

Content available at: <https://www.ipinnovative.com/open-access-journals>

Indian Journal of Clinical Anatomy and Physiology

Journal homepage: <https://www.ijcap.org/>

## Original Research Article

## Study on branching pattern of segmental branches of splenic artery in human cadaveric spleens by dissection method

Shwetha K<sup>1,\*</sup>, Dakshayani K R<sup>1</sup><sup>1</sup>Dept. of Anatomy, Mysore Medical College and Research Institute, Mysore, Karnataka, India

## ARTICLE INFO

## Article history:

Received 16-02-2021

Accepted 23-02-2021

Available online 12-04-2021

## Keywords:

Splenic artery

Segmental branches

Anastomosis

Partial splenectomy

## ABSTRACT

**Introduction:** Spleen is the largest lymphoid organ. It is supplied by splenic artery the largest branch of coeliac trunk. It traverses through the lienorenal ligament to reach near the hilum of the spleen, where it divides into two or three primary branches, each of which is subdivided mostly into two or four secondary branches. Moreover, a superior polar arteries and inferior polar arteries are given from splenic trunk or from one of its primary branches, which goes to the poles of the spleen, without entering the hilum. It can be named as superior and inferior polar artery. The human spleen is divided accordingly into two or three main segments. The segments of spleen are separated by a definite avascular plane. Hence the partial removal of the spleen is possible, as the spleen is divided into segments, separated by fibrous septa and each segment is supplied by its own main artery. The present study was undertaken to study in detail the segmental branches of splenic artery which divide the spleen into various segments, its pattern of distribution and also to find out any inter-segmental arterial anastomosis by dissection method.

**Objectives:** 1. To study segmental branches of splenic artery. 2. To study the anastomosis between the segmental branches. 3. To study the branching pattern of terminal division of splenic artery.

**Materials and Methods:** The present study was conducted on 79 adult human cadaver spleens by dissection method, irrespective of their age and sex, fixed in 10% formalin solution, collected from the Department of Anatomy and Forensic Medicine, Mysore Medical College and Research Institute, Mysore.

**Results:** 1. Two primary segmental branches were seen in 56 (70.9%) specimens, three primary segmental branches were seen in 19 (24.1%) specimens and four primary segmental branches were seen in 4 (5.1%) specimens. 2. Superior polar artery was present in 18 (22.8%) specimens and inferior polar artery was present in 32 (40.5%) and both superior and inferior polar artery was seen in 5 (6.3%) specimens. 3. Anastomosis between the primary segmental branches were seen in 11(13.9%) specimens. 4. The distributive type of branching pattern of terminal division of splenic artery was present in 50 (63.3%) specimens, and the marginal type of branching pattern was present in 29 (36.7%) specimens.

**Conclusion:** The present study adds up to the existing knowledge regarding the segmental branches of splenic artery, the better anatomical knowledge about segmental distribution of splenic artery and its variations are important for the partial removal of the spleen.

© This is an open access article distributed under the terms of the Creative Commons Attribution License (<https://creativecommons.org/licenses/by/4.0/>) which permits unrestricted use, distribution, and reproduction in any medium, provided the original author and source are credited.

## 1. Introduction

The spleen is a highly vascular and friable organ. It is the largest secondary lymphoid organ, which contains 25% of the body lymphoid tissue and has both haematological and immunological functions. Spleen is supplied by splenic

artery which is the largest branch of coeliac trunk.<sup>1</sup> It traverses through the lienorenal ligament to reach near the hilum of the spleen, where it divides into two or three primary branches, each of which is subdivided mostly into two or four secondary branches. Moreover, a superior polar arteries and inferior polar arteries are given from splenic trunk or from one of its primary branches, which goes to the poles of the spleen, without entering the hilum. It is called

\* Corresponding author.

E-mail address: [shwethajagannath85@gmail.com](mailto:shwethajagannath85@gmail.com) (Shwetha K).

as superior and inferior polar branches. The human spleen is divided accordingly into two or three main segments. Each main segment is also divided usually into two to four less constant secondary segments. The segments of spleen are separated by a definite avascular plane.

The partial removal of the spleen is possible, as the spleen is divided into segments, separated by fibrous septa and each segment is supplied by its own main artery.<sup>2</sup> The presence of splenic segmentation could be attributed to its development or to the terminal division of the artery.

Better anatomical knowledge about segmental distribution of splenic artery and its variations are important for the partial removal of the organ. So, keeping the applied aspect and clinical significance of segmental branches of splenic artery and to add more knowledge to the existing one, the present study was undertaken to study the segmental branches of splenic artery which divide the spleen into various segments, its pattern of distribution and also to find out any inter-segmental arterial anastomosis by dissection method.

## 2. Aims and Objectives

To study the branching pattern of the segmental branches of splenic artery and to find out if there is any the anastomosis between the segmental branches.

## 3. Materials and Methods

The present study is conducted on 79 Human cadaver spleens, irrespective of their age and sex, fixed in 10% formalin solution, collected from the department of Anatomy and Forensic Medicine, Mysore Medical College and Research Institute.

The gross dissection was done by following the guide lines of Cunningham's Manual. The spleen was identified and freed from the posterior abdominal wall and stomach by cutting through the gastrosplenic and lienorenal ligaments. The splenic artery was cut about 10 cm proximal to hilum of spleen, then the spleen was removed. The fascia and fat was cleared at the hilum to expose the segmental branches of the splenic artery. Firstly, the primary segmental branches of the splenic artery and its branching patterns were identified and noted, then by removing the parenchyma along the primary branches by piecemeal dissection the secondary branches and also inter segmental arterial anastomosis if any were noted.

## 4. Results

Two primary segmental branches were seen in 56 (70.9%) specimens, three primary segmental branches were seen in 19 (24.1%) specimens and four primary segmental branches were seen in 4 (5.1%) specimens.

Superior polar artery was present in 18 (22.8%) specimens and inferior polar artery was present in 32

(40.5%) specimens and both superior and inferior polar artery was seen in 5 (6.3%) specimens.

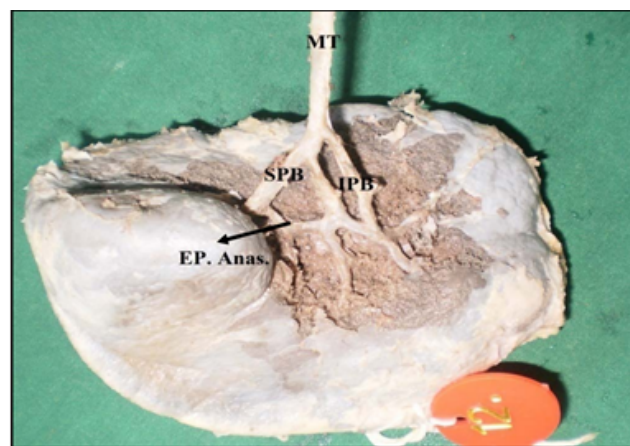
Superior polar artery arising from main trunk was present in 12 (67%) specimens and superior polar artery arising from primary branch seen in 6 (33%) specimens.

Inferior polar artery was seen arising from main trunk in 15 (47%) specimens, from left gastroepiploic artery in 9 (28%) specimens and from primary branch in 8 (25%) specimens.

Anastomosis between the primary segmental branches were seen in 11 (13.9%) specimens.

The extra-parenchymal anastomosis of primary segmental branches was seen in 5 (6.3%) specimens. The intra-parenchymal anastomosis was seen in 3 (3.7%) and sub-capsular type of anastomosis was seen in 3 (3.7%) specimens.

The distributive type of branching pattern was present in 50 (63.3%) specimens. The marginal type of branching pattern was present in 29 (36.7%) specimens.



**Fig. 1:** Extra-parenchymal anastomosis between superior and inferior primary branches  
(MT- Main Trunk, SPB – Superior Primary Branch, IPB – Inferior Primary Branch, EP. Anas. – Extra Parenchymal Anastomosis)

**Table 1:** Number of primary segmental branches of splenic artery

S. No.	Primary segmental branches	Number of specimens	Percentage (%)
1	One	Nil	0
2	Two	56	70.9
3	Three	19	24.1
4	Four	4	5.1
5	Total	79	100

## 5. Discussion

Spleen is supplied by splenic artery, which terminates at the hilum by dividing into 2 or 3 terminal branches.

**Table 2:** Types of anastomosis

Types of anastomosis	Number of specimen	Percentage (%)
None	68	86.3
Extra-parenchymal	5	6.3
Intra-parenchymal	3	3.7
Sub-capsular	3	3.7
Total	79	100.0

**Table 3:** Comparison of number of primary segmental branches of splenic artery with the previous studies

Author	Number of specimens studied	Number of primary segmental branches		
		2	3	4
Gupta CD et al. (1976) <sup>3</sup>	50	84%	16%	-
Mikhail Y et al. (1979) <sup>4</sup>	25	77%	23%	-
Katrisis E et al. (1982) <sup>5</sup>	70	88.7%	14.3%	-
Mandarin LCA (1983) <sup>6</sup> [6]	25	68.2%	10.6%	4.5%
Garcia PJA (1988) <sup>7</sup>	181	92.82%	7.18%	-
Sow ML (1991) <sup>8</sup>	32	84%	16%	-
Silva LFA (2010) <sup>9</sup>	-	93.34%	6.66%	-
Chaware PN et al. (2012) <sup>10</sup>	-	85.58%	14.42%	-
Swamy VL et al. (2013) <sup>11</sup>	60	66%	17%	17%
Londhe SR et al. (2013) <sup>12</sup>	50	90%	10%	-
Present study	79	70.9%	24.1%	5.1%

**Table 4:** Comparison of polar arteries with the previous studies

Author	Polar artery		
	Superior	Inferior	Both
Present Study	22.8%	40.5%	6.3%
Mikhail Y et al <sup>4</sup>	18%	50%	12%
Garcia PA et al <sup>7</sup>	29.28%	44.75%	10.49%
Chaware PN et al <sup>10</sup>	28.82%	42.34%	11.7%
Swamy VL et al <sup>11</sup>	41.6%	25%	16.6%
Londhe SR et al <sup>12</sup>	32%	56%	24%

**Table 5:** The comparison of anastomosis between segmental branches with the previous studies

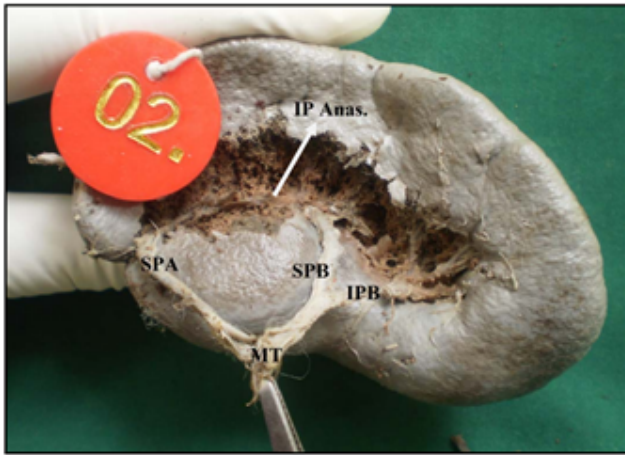
Author	Observation
Present study	13.9%
Gupta CD et al <sup>3</sup>	No anastomosis
Garcia PJA et al <sup>7</sup>	19.89%
Mandarin LCA et al <sup>6</sup>	16.7%
Chaware PN et al <sup>10</sup>	1.80%

**Table 6:** Comparison of types of anastomosis with the previous studies

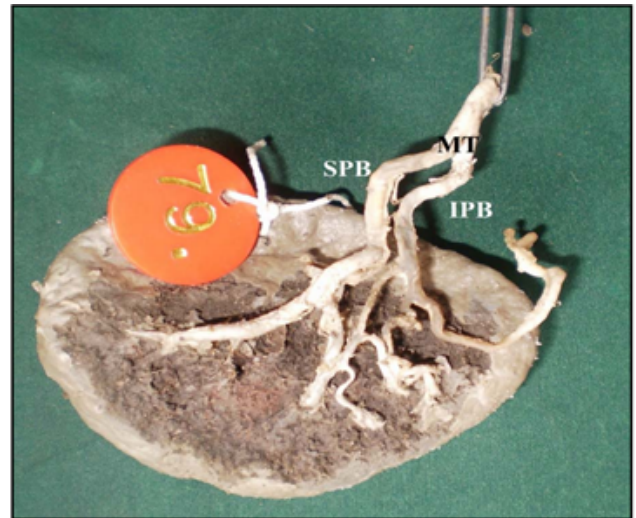
Author	Type of anastomosis		
	Extra-parenchymal	Intra-parenchyma	Sub-capsular
Present study	6.3%	3.7%	3.7%
Sow ML et al. <sup>8</sup>	9%	32%	-
Holibkova A et al. <sup>13</sup>	15%	45%	8%

**Table 7:** The comparison of branching pattern with the previous studies

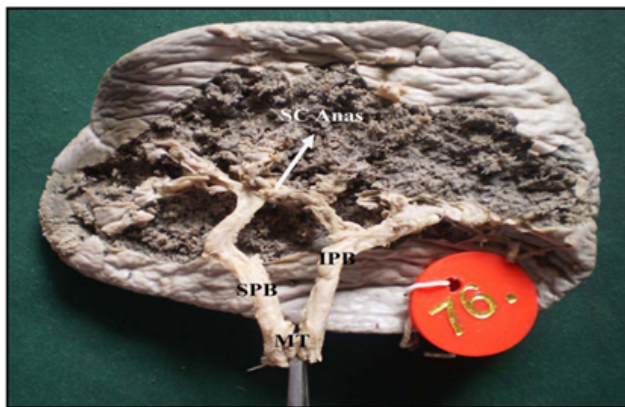
Author	Branching Pattern	
	Distributive type	Marginal type
Present study	63.3%	36.7%
Michels NA et al. <sup>14</sup>	70%	30%
Holibkova A et al. <sup>13</sup>	80%	20%
Charles Brunicardi F et al. <sup>15</sup>	70%	30%



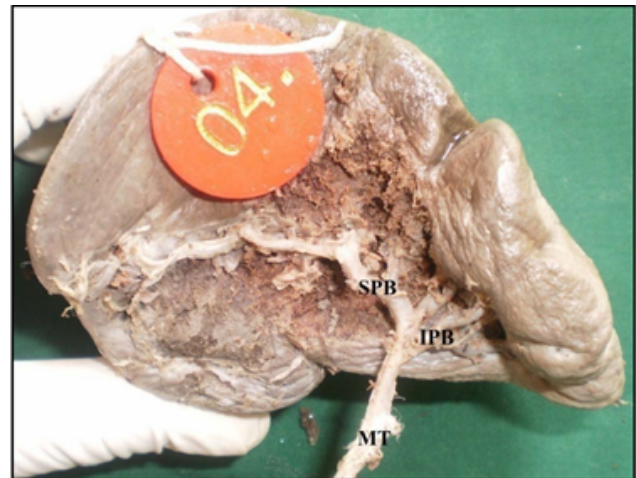
**Fig. 2:** Intra-parenchymal anastomosis between superior primary branch and superior polar artery (MT – Main Trunk, SPB – Superior Primary Branch, IPB – Inferior Primary Branch, SPA – Superior Polar Artery, IP. Anas. – Intra-Parenchymal Anastomosis)



**Fig. 4:** Distributive type of branching pattern (MT – Main Trunk, SPB– Superior Primary Branch, IPB – Inferior Primary Branch)



**Fig. 3:** Sub-capsular type of anastomosis between superior and inferior primary branches (MT – Main Trunk, SPB – Superior Primary Branch, IPB – Inferior Primary Branch, SC. Anas. – Sub capsular Anastomosis)



**Fig. 5:** Marginal type of branching pattern (MT – Main Trunk, SPB – Superior Primary Branch, IPB – Inferior Primary Branch)

These are named as superior, middle and inferior primary branches. These branches supply a particular part of the spleen which is separated by an avascular plane. Thus, these branches divide the spleen into definite arterial segments. So these arteries can be considered as the primary segmental branches.<sup>5</sup> In the present study two primary branches were seen in 56 (70.9%) specimens, three in 19 (24.1%) specimens and four in 4 (5.1%) specimens. Other studies showed only 2 to 3 primary branches. In this study we have observed 2 to 4 primary branches. The comparison of number of primary branches with the previous studies is given in Table 3.

In some spleens, a branch arising from splenic artery itself or one of its primary branch which does not pierce the hilum, but goes to the poles of spleen. These are known as superior and inferior polar arteries. These arteries also supply a particular segment of spleen, which can be considered as the polar segments.<sup>16</sup> In our study we observed superior polar artery was present in 18(22.8%) specimens and inferior polar artery was present in 32 (40.5%) specimens and both superior and inferior polar artery was seen in 5 (6.3%) specimens. The comparison between other studies is given in Table 4.

Superior polar arteries arising from main trunk was present in 12 (67%) specimens and superior polar arteries

arising from primary branch were seen in 6 (33%) specimens. Inferior polar artery was seen arising from main trunk in 15 (47%) specimens, from left gastroepiploic artery in 9 (28%) specimens and from primary branch in 8 (25%) specimens.

Katrisis E et al<sup>5</sup> in their study noted that, the polar arteries arise either from main trunk or primary branch. Silva LFA et al<sup>9</sup> observed 16% arising from main trunk and 20% arising from terminal branches. Swamy VL et al<sup>11</sup> noted all polar arteries arising from main trunk only.

The spleen is divided into segments; each segment is supplied by its own segmental branches. These segments are separated by a definite avascular plane. But rarely there may be an inter-segmental anastomosis. In the present study, anastomosis between the primary segmental branches seen in 11 (13.9%) specimens. The comparison of anastomosis between segmental branches with previous studies is given in Table 5.

The inter-segmental anastomosis can be of three types.

1. Extra parenchymal Anastomosis.
2. Intra parenchymal anastomosis.
3. Sub capsular anastomosis.

In the present study we observed, the extra-parenchymal anastomosis of primary segmental branches were seen in 5 (6.3%) specimens, the intra parenchymal anastomosis was seen in 3 (3.7%) specimens and sub capsular type of anastomosis was seen in 3 (3.7%) specimens. Comparison of type of anastomosis with the previous studies is given in Table 6.

Based on terminal branching pattern, the splenic artery pedicle can be classified into two types.

1. Distributive type where the splenic artery divides away from the hilum of the spleen with long terminal branches that enters through the hilum.
2. Marginal type where the artery divides at the hilum with short terminal branches.

In the present study we observed, the distributive type of branching pattern was present in 50(63.3%) specimens and the marginal type of branching pattern was present in 29(36.7%) specimens.

A study conducted by Henschen et al.<sup>17</sup> classified three types of pattern and observed, short distribution in 10%, long distribution in 40% and marginal type in 46%. The comparison of present study with previous studies is given in Table 7.

## 6. Conclusion

The spleen is a highly vascular and friable organ. It is the largest of secondary lymphoid organ, which contains 25% of the body's lymphoid tissue and has both haematological and immunological functions. Total splenectomy is commonly done after a splenic injury, which

leads to decrease in the immunity and predisposes the normal host to overwhelming life threatening infections and also creates an altered haematological picture. To overcome this, partial splenectomy can be done by ligating a particular segmental branch of splenic artery.

The partial removal of the spleen is possible, as the spleen is divided into segments, separated by fibrous septa and each segment is supplied by its own main artery. The presence of splenic segmentation could be attributed to its development or to the terminal division of the artery. Better anatomical knowledge about segmental distribution of splenic artery and its variations are important for the partial removal of the organ.

## 7. Source of Funding

None.

## 8. Conflicts of Interest

None.

## References

1. Standring S. The Anatomical Basis of Clinical Practice. In: Gray's Anatomy. Edinburg: Churchill Livingstone Elsevier; 2008. p. 1239–45.
2. Kyber E. Über die Milz des Menschen und einiger sangetiere. *Arch Microsk Anat Entw Mech.* 1870;6:540–70.
3. Gupta CD, Gupta SC, Arora AK, Jeya SP. Vascular segments in human spleen. *J Anat.* 1976;121(3):613–6.
4. Mikhail Y, Kamel R, Nawar NNY, Rafla MFM. Observations on the mode of termination and parenchymal distribution of the splenic artery with evidence of splenic lobation and segmentation. *J Anat.* 1979;128(2):253–8.
5. Katrisis E, Parashos A, Papadopoulos N. Arterial Segmentation of the Human Spleen by Post-Mortem Angiograms and Corrosion-Casts. *Angiology.* 1982;33(11):720–7. doi:10.1177/000331978203301104.
6. Mandarim LCA, Sampaio FJ, Passos MA. Vascular segmentation of the spleen in the new born infants. Anatomical support for partial resection. *J Chir (Paris).* 1983;120(8-9):471–3.
7. Garcia-Porrero JA, Lemes A. Arterial Segmentation and Subsegmentation in the Human Spleen. *Cells Tissues Organs.* 1988;131(4):276–83. doi:10.1159/000146529.
8. Sow ML, Dia A, Ouedraogo T. Anatomic basis for conservative surgery of the spleen. *Surg Radiol Anat.* 1991;13(2):81–7. doi:10.1007/bf01623878.
9. Silva LFA. Morfometric study of arterial branching of the spleen compared to radiological study. *Rev Col Bras Cir.* 2011;38(3):181–5.
10. Chaware PN, Belsare SM, Kulkarni YR, Pandit SV, Ughade JM. Variational anatomy of the segmental branches of the splenic artery. *JCDR.* 2012;6(3):336–8.
11. Swamy VLI, Suseelamma D, Jadhav SD, Balbhim ZR, Mithil NP, Chaitanya K. Study of prehilum branches of splenic artery by dissection method. *Int J Med Res Health Sci.* 2013;2(3):620–3. doi:10.5958/j.2319-5886.2.3.109.
12. Londhe SR. Study of vascular pattern in human spleen by carrion cast method. *Al Ameen J Med Sci.* 2013;6(2):167–9.
13. Holibkova A, Machalek L, Houserkova D, Ruzioka V. A contribution to the types of branching and anastomosis of the splenic artery in the human spleen. *Biomedical Papers.* 1998;141(1):49–52.
14. Michels NA. The variational anatomy of the spleen and splenic artery. *Am J Anat.* 1942;70(1):21–72. doi:10.1002/aja.1000700103.

15. Brunicaudi FC. Schwartz's Principles of Surgery. 8th ed. McGraw-Hill Companies Inc; 2005.
16. Redmond HP, Redmond JM, Rooney BP, Duignan JP, Bouchier-Hayes DJ. Surgical anatomy of the human spleen. *Br J Surg*. 1989;76(2):198–201. doi:10.1002/bjs.1800760230.
17. Henschen C. Die chirurgischen Anatomie der Milzgefisse. *Schweiz Med Wochenschr*. 1928;58:161–70.

**Dakshayani K R**, Professor and Head

**Cite this article:** Shwetha K, Dakshayani K R. Study on branching pattern of segmental branches of splenic artery in human cadaveric spleens by dissection method. *Indian J Clin Anat Physiol* 2021;8(1):30-35.

### Author biography

**Shwetha K**, Tutor