



Short Communication

Infrared clinical anatomy of mammary gland's additional lobe in non-pregnant young woman

Natalia Urakova¹, Aleksandr Urakov^{2,1,*}, Vladimir Nikolenko^{3,2}, Lolita Kartasheva¹

¹Dept. of Modeling and Synthesis of Technological Structures, Udmurt Federal Research Center of Ural branch of RAS, Izhevsk, Russia

²Dept. of Human Anatomy, I. M. Sechenov First Moscow Medical State University, Moscow, Russia

³Dept. of Anatomy, M.V. Lomonosov Moscow State University, Moscow, Russia



ARTICLE INFO

Article history:

Received 03-02-2020

Accepted 17-02-2020

Available online 14-03-2020

Keywords:

Mammary glands

additional lobe

Menstrual cycle

Clinical anatomy

Infrared thermography

Visualization

Diagnostics

ABSTRACT

A method of infrared detection of mammary gland's additional lobe has been developed due to changes in the local temperature of the anterior and lateral surfaces of the chest detected with a thermal imager that has an accuracy of 0.01 °C. It is shown that infrared thermography allows to diagnose, determine the location, shape and size of the additional lobe of the mammary gland in the last 3 days before menstruation.

© 2020 Published by Innovative Publication. This is an open access article under the CC BY-NC-ND license (<https://creativecommons.org/licenses/by/4.0/>)

1. Introduction

Currently, known methods of diagnosis do not provide timely detection of an additional lobe of the mammary gland. Therefore, the process of formation and development of an additional lobe of the mammary gland still cannot be diagnosed at the stage of development and education.^{1,2} Usually, young women first learn about the presence of an additional lobe only during pregnancy or in the first days after birth. This is due to the action of prolactin, which causes the transformation of the mammary glands for subsequent lactation.^{3,4} At the same time, all these changes occur not only in the normal mammary glands, but also in the additional lobe of them. Therefore, some young women have swelling in the projection area of this additional lobe, and sometimes pain.⁵

The aim of the study was to develop a method for infrared detection of additional lobe of mammary gland in young women before the first pregnancy. First, we studied scientific articles and inventions that were essentially the closest to the goal. The analysis of the obtained information allowed us to choose the following invention as a prototype: "Method for of breast infrared screening growths» (RU patent 2561302). The essence of this method is that using a thermal imager with the function of color image of the breast surface on the screen, the dynamics of its local temperature is observed during the process of blowing the gland with room temperature air. When a site with local hypothermia or hyperthermia appears, a conclusion is made about the presence of a neoplasm, and its shape, size, and localization are specified.

However, this method does not provide detection of an additional lobe of the mammary gland. The fact is that the known method does not provide monitoring of the dynamics of the local temperature of the chest surface during the

* Corresponding author.

E-mail address: urakoval@live.ru (A. Urakov).

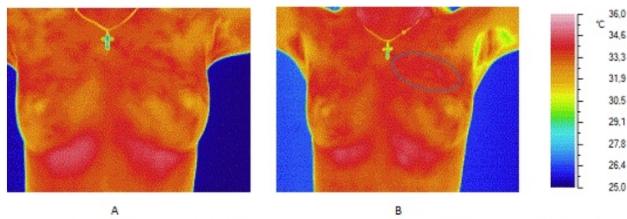


Fig. 1: Thermogram of healthy non-pregnant young woman (M 23 years old); **A:** The 20th day of the menstrual cycle; **B:** The last day of the menstrual cycle (28th day). (The ellipse indicates the area of the additional lobe of the mammary gland)

menstrual cycle. At the same time, on most days of the menstrual cycle, the local temperature of the additional lobe of the mammary gland does not differ from the temperature of neighboring tissues. This is confirmed by the fact that previously, with the help of standard infrared diagnostics, no one detected a zone of local hyperthermia in the chest area in women in the norm. However, the generally accepted Protocol for infrared diagnostics excludes the registration of local breast temperature in women during menstruation and / or near menstruation.

In this regard, in the period between September 15 and December 15, 2019, we monitored the dynamics of the local temperature of the front surface of the chest in 52 healthy non-pregnant young women aged 18-23 years during the menstrual cycle. Before starting the study, it was found that, 40 out of 52 young women previously usually experienced pain in the area of the mammary glands before menstruation. However, no one has been treated with medication for this condition. The other 12 young women did not experience breast pain before menstruation. These young women formed a control group. Infrared thermography was performed using the TH91XX thermal imager (NEC, USA) using a well-known method.⁶

Analysis of the results showed that thermal monitoring of the local temperature dynamics of the anterior surface of the chest, conducted during the pre-menstrual period, proved the possibility of infrared imaging of additional mammary lobes. In particular, with the help of a thermal imager, additional lobe of mammary gland were detected in 7 young women. It is important to emphasize that these additional lobes of the mammary glands were not found in young women from the control group. Moreover, the additional lobes of the mammary glands were identified by foci of local hyperthermia, which appeared only 3-2 days before menstruation and remained for 1-2 days, after which they disappeared without a trace and were absent at other times of the menstrual cycle.

Pockets of local hyperthermia have been identified: in the 2 young women - on the right side along the 3rd intercostal space between the mid clavicular and anterior axillary lines;

in the 3 young women - in the underarm area (2 - in right side and 1 - in left side); in the 2 young women - at the intersection of the 4th intercostal space with anterior axillary line. The foci of local temperature had a width of 2.5 ± 0.2 cm and a length of 3.0 ± 0.3 cm ($P \leq 0.05$, $n = 7$). In the foci of local hyperthermia, the temperature was 0.8 ± 0.3 °C ($P \leq 0.05$, $n = 7$) higher than the temperature in neighboring tissues (Figure 1).

The accuracy of the infrared diagnosis of the additional lobe of mammary gland was confirmed by the result of a cytological examination of the biopsy obtained using a puncture biopsy. This biopsy was performed on our recommendation and with the voluntary informed consent of one young woman in the central part of the local hyperthermia area detected with a thermal imager. Thus, if a woman has an additional lobe of the mammary gland, the local skin temperature above it begins to increase then 3 days before menstruation and for 1-2 days it increases by an average of 0.8 °C compared to the skin temperature in neighboring areas. The focus of local hyperthermia of the skin in the area of the projection of the additional lobe of the mammary gland can be detected using infrared thermography of the front surface of the chest, which should be performed daily a week before menstruation. The localization, shape, and size of the local hyperthermia focus during this period of the menstrual cycle indicate the localization, shape, and size of the additional breast lobe.

2. Conflict of Interest

None.

References

- Macias H, Hinck L. Mammary gland development. *Wiley Interdiscip Rev Dev Biol.* 2012;1(4):533–557.
- Lteif A, Javed A. Development of the Human Breast. *Semin Plast Surg.* 2013;27(01):5–12.
- Khan YS, Sajjad H. Anatomy, Thorax, Mammary Gland ;. Available from: <https://www.ncbi.nlm.nih.gov/books/NBK547666/>.
- Mammary gland. Anatomy ;. Available from: <https://www.britannica.com/science/mammary-gland>.
- Mammary gland. Features of the additional lobe of the mammary gland ; 2019,. Available from: <https://nuzpolarmavir.ru/mammologiya/dairy-share-features-of-an-additional-mammary-gland.html>.
- Ring EFJ, Ammer K. The technique of infra-red imaging in medicine. *Thermol Intl.* 2017;27(2):78–79.

Author biography

Natalia Urakova Associate Professor

Aleksandr Urakov Professor

Vladimir Nikolenko Professor

Lolita Kartasheva Assistant Professor

Cite this article: Urakova N, Urakov A, Nikolenko V, Kartasheva L. Infrared clinical anatomy of mammary gland's additional lobe in non-pregnant young woman. *Indian J Clin Anat Physiol* 2020;7(1):127-129.