



Case Report

Ulnar artery: A case report of high origin and superficial course

Veena V Kulkarni^{1,*}, Rakesh Kumar¹, Subhash K Deshpande¹

¹Dept. of Anatomy, SDM Medical College Sciences & Hospital, Dharwad, Karnataka, India



ARTICLE INFO

Article history:

Received 05-10-2019

Accepted 13-02-2020

Available online 14-03-2020

Keywords:

Ulnar artery

Upper limb artery

Brachial artery

ABSTRACT

Blood vessel variety of the upper appendage are normal and these can be of impressive enthusiasm to orthopedic surgeons, radiologists and anatomists. During routine dissection for college understudies of the right upper limb in a male cadaver, a variation starting point of ulnar artery from brachial artery was taken note. The brachial artery ending in the cubital fossa by partitioning into radial and ulnar or interosseous supply routes. The outspread artery had taken typical course and branches. Different divisions was the basic interosseous artery, anterior and posterior ulnar recurrent arteries demonstrated ordinary course. The irregular high source of ulnar artery route from the brachial artery was seen which was taking root from medial side of the brachial artery higher than the radial artery, running on the shallow muscles and going underneath the Palmaris longus tendon and intersection the tendon from lateral to medial side. At that point its running shallow to the muscles which were taking cause from the regular flexor source from the humerus and it was secured by the profound belt of the forearm arm, at that point it crosses the flexor retinaculum and partook in the formation of the superficial palmar arch. During its course, supply route didn't give any branch.

© 2020 Published by Innovative Publication. This is an open access article under the CC BY-NC-ND license (<https://creativecommons.org/licenses/by/4.0/>)

1. Introduction

On the off chance that we put pressure to the horizontal side against the shaft of the humerus we can feel the pulsation of the brachial artery next to the average side of biceps and furthermore superiorly, in the discouraged zone back to coracobrachialis muscle. In the distal part pulse can be felt posteromedial to the tendon of biceps brachii then it dives deep to the bicipital aponeurosis. The brachial course lies average to the humerus in its upper part, however then lies straightforwardly before the hard shaft. The nearness of the supply route to a bone against which it very well may be compacted makes this the helpful apparatus to quantify the pulse. The median nerve is firmly identified with the brachial artery all through its course in the arm. It lies at first parallel to the artery, then in centre of the arm the median nerve crosses the brachial artery by going before it and plummets average to the artery till the cubital fossa.

The ulnar artery is one of the bigger terminal part of the brachial artery. It starts 1 cm distal to the flexion wrinkle of the elbow and degrees to the average side of the lower forearm till its halfway among elbow and wrist. During its course in the lower forearm the artery route lies superficially on brachialis and afterward profound to pronator teres, flexor carpi radialis, palmaris longus and flexor digitorum superficialis. Ulnar artery at that point lies on flexor digitorum profundus muscle, between flexor carpi ulnaris and flexor digitorum superficialis muscle and is likewise secured by the skin, shallow and profound fascia. The median nerve structure the average connection with the supply route in the upper piece of the arm, and then crosses the artery and goes sidelong to artery. The ulnar nerve lies average to the artery in its lower part, which supplies the nerve all through its length. The palmar cutaneous part of the ulnar nerve running along the ulnar supply route to arrive at the hand. The artery crosses the flexor retinaculum of the hand, lies sidelong to the ulnar nerve and pisiform bone, at that point it enter the hand.¹

* Corresponding author.

E-mail address: rakesh.anat@gmail.com (V. V. Kulkarni).

2. Case Report

During routine cadaveric dismemberment in the department of Anatomy for the college understudies, we got an alternate root of ulnar artery from brachial artery route in the cubital fossa. The brachial artery end in the cubital fossa by sharing into two branches (Figure 1). One of the branch is the ulnar artery and other branch going downwards and afterward at the neck of the radius it separates into the radial and common interosseous artery. The radial supply route took ordinary course and branches. One of the artery was the basic interosseous supply route, and it at that point isolating into anterior and posterior interosseous arteries, which demonstrated the typical course.

A rare unusual origin of ulnar artery from the brachial artery was observed which was taking origin from medial aspect of the brachial artery little higher than the radial artery, descends on the pronator teres, flexor digitorum superficialis muscles and at the middle of the forearm artery passing below the Palmaris longus tendon from lateral to medial (Figure 2). Thus it took a superficial course along the forearm and the artery was covered by the deep fascia of the forearm. In the lower part of the forearm artery was nearer to the ulnar nerve. Then it crosses the flexor retinaculum, and took part in the formation of the superficial palmar arch. During its course, artery did not give any branch.

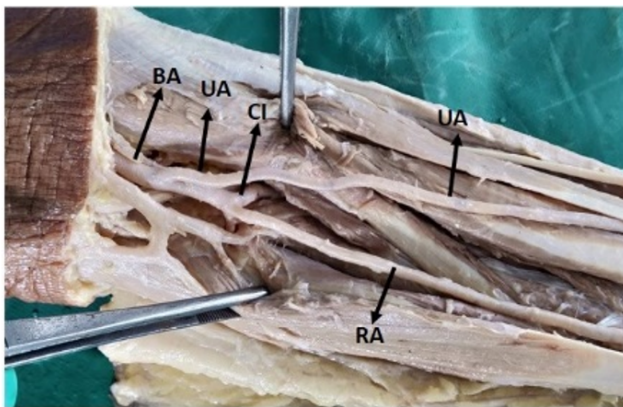


Fig. 1: Ulnar artery taking high origin from brachial artery. BA- Brachial artery, UA-Ulnar artery, CI-Common interosseous artery, RA- Radial artery

3. Discussion

Varieties root of the blood vessel example of the upper appendage are basic that has demonstrated in before studies.²⁻⁸ Inordinate accessory branches may take source from the brachial artery.⁹ Ulnar supply route was watched separated from its ordinary course of beginning in one in very nearly thirteen cases, as often as possible it jumped on or after the lower some portion of the brachial Artery. The course of the ulnar artery in the lower forearm was every

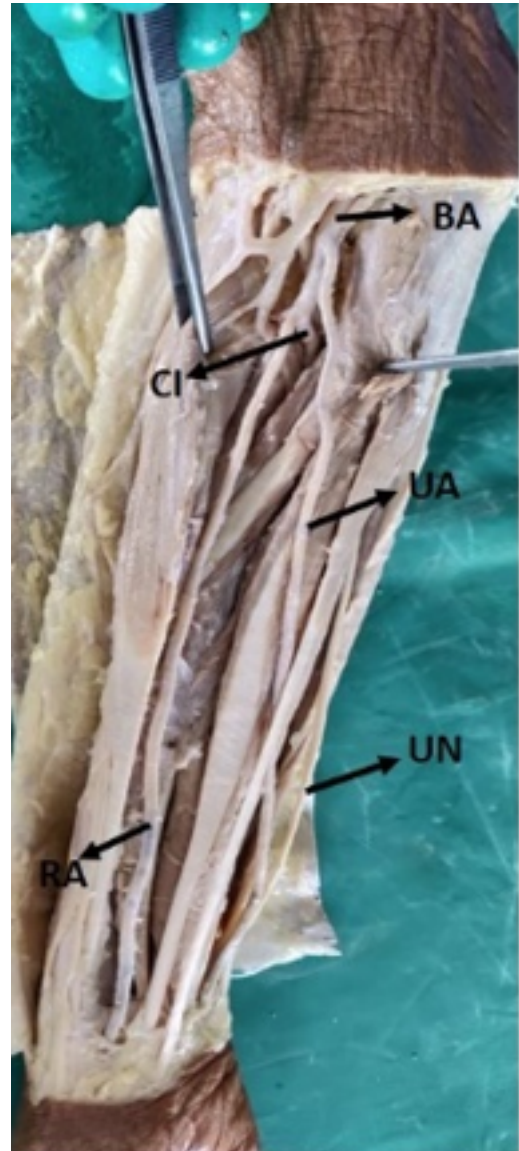


Fig. 2: Superficial course of ulnar artery, BA- Brachial Artery, UA- Ulnar Artery, CI - Common interosseous Artery, RA- Radial Artery, UN- Ulnar Nerve

now and again changed, in instances of variable starting point, it perpetually running over the shallow muscles taking origin from the medial epicondyle of the humerus and was encased by the profound sash of the forearm.² The present contextual analysis of ulnar supply route is somewhat not quite the same as the varieties exhibited in Quain's Anatomy (Thane, 1892). This case is of significance. In such cases course may show a shallow pulse and a hazard to venipuncture¹⁰ and lead to harming intra-blood vessel infusions or ligature as a substitute of the vein in the cubital fossa.^{11,12}

4. Embryological basis

Every appendage is provided by a pivot artery that is gotten from intersegmental arteries. The axis artery run along the focal hub of the appendage. The Axis artery of the upper appendage is resultant from seventh cervical intersegmental (subclavian) artery. The supply route raises distally along the ventral hub line and rejects in a palmar capillary plexus in hand. Principle trunk of hub artery shapes axillary artery, brachial artery, foremost interosseous artery and profound palmar arch. Radial and ulnar arteries become later as buds of the axis artery adjoining twist of the elbow.¹³

5. Conclusion

Unordinary root of ulnar supply route is an uncommon instance of variety with considerable clinical significance. Familiarity with the variety of arteries isn't huge for anatomists anyway additionally for angiologists, vascular specialists, paramedical staff, radiologists and other therapeutic staff since they ordinarily do cannulation and intravenous infusions.

6. Source of Funding

None.

7. Conflict of Interest

None.

References

1. Standring S. Gray's anatomy-The anatomical Basis of Clinical Practice. Spain: Churchill Livingstone Elsevier ;
2. Thane GD. Quain's elements of Anatomy. In: and others, editor. Arthrology- Myology-Angiology. 10th Edn. London: Longman,

Green, and Co ; 1892, .

3. Cormack LJM, Caldwell MD, Anson BJ. Brachial antebachial arterial patterns. *Surg Gynecol Obstet.* 1953;96:43–54.
4. Coleman SS, Anson BJ. Arterial patterns in the hand based upon a study of 650 specimens. *Surg Gynecol Obstet.* 1961;113:409–424.
5. Poteat WL. Report of a rare human variation: Absence of the radial artery. *Anatomical Rec.* 1986;214(1):89–95.
6. Aharinejad S, Nourani F, Hollensteiner H. Rare case of high origin of the ulnar artery from the brachial artery. *Clin Anat.* 1997;10(4):253–258.
7. Patnaik VVG, Kalsey G, Singla RK. Trifurcation of brachial artery-A case report. *J Anatomical Soc India.* 2001;50(2):163–165.
8. Suganthi J, Koshy S, Indrasingh I, Vettivel S. A very rare absence of radial artery : A case report. *J Anatomical Soc India.* 2002;51(1):61–64.
9. Huber GC. Piersol's Human Anatomy. In: The vascular system 9th Edn. vol. 1. Philadelphia: J. B. Lippincott Co ; 1930, . p. 767–791.
10. Hazlett JW. Superficial ulnar artery with reference to accidental intra-arterial injection. *Can Med Assoc J.* 1949;61:289–318.
11. Pabst R, Lippert H. Belderseitiges Vorkommen von A. brachialis superficialis, ulnaris superficialis and A. mediana. *Anatomischer Anzeiger.* 1968;123:223–226.
12. Thoma A, Young JEM. The Superficial Ulnar Artery "Trap" and the Free Forearm Flap. *Ann Plast Surg.* 1992;28(4):370–372.
13. Vishram S. Textbook of Clinical Embryology. vol. 19 ; p. 219–220.

Author biography

Veena V Kulkarni Professor

Rakesh Kumar Tutor

Subhash K Deshpande Professor

Cite this article: Kulkarni VV, Kumar R, Deshpande SK. **Ulnar artery: A case report of high origin and superficial cours.** *Indian J Clin Anat Physiol* 2020;7(1):124-126.