



Short Communication

Cross sectional anatomy - need for uniformity in the display of medical images or line diagram while representing the anatomical structures

S Rajalakshmi¹, Shyamkumar N Keshava^{2,*}, Aparna Irodi², Suganthy Rabi¹

¹Dept. of Anatomy, Christian Medical College, Vellore, Tamil Nadu, India

²Dept. of Radiology, Christian Medical College, Vellore, Tamil Nadu, India



ARTICLE INFO

Article history:

Received 10-11-2018

Accepted 26-10-2019

Available online 31-12-2019

Keywords:

Cross-sectional anatomy

CT

MRI

ABSTRACT

Cross sectional anatomy had enjoyed wide popularity during 19th century, but its application declined during 20th century. With the advent of radiologic techniques like computed tomography, magnetic resonance imaging, cross sectional anatomy regains its importance. However, there were differences in the ways anatomists and radiologists approach cross sectional anatomy. This manuscript tries to point out the differences and the steps taken by anatomists to integrate teaching of Anatomy with clinical teaching.

© 2019 Published by Innovative Publication. This is an open access article under the CC BY-NC license (<https://creativecommons.org/licenses/by-nc/4.0/>)

1. Introduction

There were differences in the ways anatomists and radiologists approach cross-sectional anatomy. If learning cross-sectional anatomy and subsequent imaging anatomy are in the same orientation, a potential scope for wrong identification of the side can be avoided. This manuscript tries to point out the steps taken by anatomists to integrate teaching of Anatomy with clinical teaching.

Sectional anatomy has had a long history, enjoyed wide popularity during 19th century, but its application to study anatomy declined during early 20th century. It cannot be said with certainty who had started the study of cross-sectional anatomy, but it was used in 16th century, which was evident from the drawings of Leonardo da Vinci.¹

With the advent of radiological techniques, such as Computed Tomography (CT) and Magnetic Resonance Imaging (MRI), cross-sectional anatomy regains its importance. It is not only mandatory for the radiologists, but also for the surgeons, physicians, students of Anatomy to learn cross-sectional anatomy in order to interpret these

Cross-section of thorax, viewed from head-end

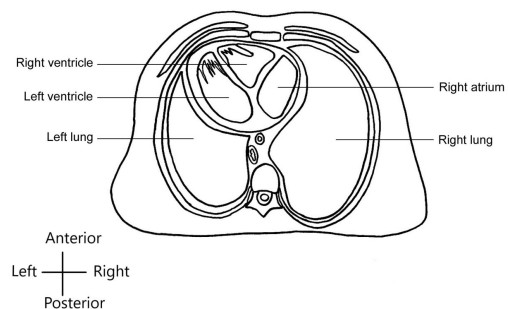


Fig. 1:

images and provide quality health care for the patients.¹⁻⁵ Knowledge of cross-sectional Anatomy helps the students to get a three dimensional view of the organs, their relationship with one another, retaining the information for a longer duration.^{2,4,6}

The books which were published earlier displayed the cross-sectional anatomy images as viewed from the head end down as it was considered as *rational standard/clinical position*.⁷ As per the standard Anatomical Position, the

* Corresponding author.

E-mail address: shyamkumar.n.keshava@gmail.com (S. N. Keshava).

Table 1: Table depicting the name of the books and their way of display of cross-sectional images/ line diagrams

Name of the book	Images are viewed from		
	From Head end	From Foot end	Mixed (some images were viewed from head end, some from foot end)
Cunningham's Manual of Practical Anatomy	+ (Upto 15 th edition)	+ (16 th edition)	-
Gray's Anatomy, The Anatomical basis of Clinical Practice	+ (Upto 38 th edition)	+ (From 40 th edition)	+ (39 th edition)
Clinical Anatomy: Harold Ellis	+ (Upto 9 th edition) (10 th , 11 th , 12 th editions were not available in the library.)	-	+ (13 th edition)
Human Sectional Anatomy, Atlas of Body sections, CT and MRI images, by Harold Ellis, Bari M Logan, Adrian K Dixon	-	+ (3 rd and 4 th editions)	-
An Atlas of Anatomy: J.C.Boileau Grant	-	-	+ (5 th , 10 th , 14 th editions)
Last's Anatomy, Regional and Applied	+ (Upto 7 th edition : for cross-sections through limbs-orientation not mentioned) (8 th , 9 th , 11 th editions were not checked as they were unavailable).	-	+ (10 th , 12 th editions)
Clinical Anatomy for Medical students: Richard S.Snell	-	-	+ (4 th to 9 th edition)
Clinical oriented Anatomy: Keith L Moore	-	-	+ (2 nd to 7 th edition)
Colour Atlas of Human Anatomy: McMinn	-	-	+ (2 nd to 6 th edition)
Illustrated Clinical Anatomy by Peter Abraham, John Craven, John Lumley	-	-	+ (For some cross-sectional images, orientation is not mentioned)
Textbook of Human Anatomy: Hamilton, 2 nd edition	+	-	(For some cross-sectional images, orientation is not mentioned)
Detailed atlas of the Head and Neck by Truex and Kellner	-	-	+
Atlas of Human Anatomy: Lopetz-Antunez	+	-	-
Anatomy, a photographic Atlas by Rohen, Yokochi, Lutjen-Drecoll	-	-	+ (8 th edition: for some cross-sections orientation is not mentioned.)
Atlas of Human Anatomy: Frank.H.Netter	-	-	+ (2 nd to 6 th edition)
Workbook for a cross-sectional approach to anatomy: Roy R.Peterson	-	+	-
An atlas of cross-sectional anatomy, Computed tomography, Ultrasound, Radiography, Gross anatomy: Stephen A.Kieffer, E.Robert Heitzman	-	+	-
Basic atlas of sectional anatomy with correlated imaging: J.Bo W, Carr JJ, A.Krueger W, T. Woleman N, L. Bowden R	-	+ (1 st , 2 nd , 4 th editions.) (3 rd edition was not available)	-
The visible human body, Indian edition: Von Hagens G, J Romrell L, H.Ross M, Tiedemann K.	-	+	-
Living anatomy, Robert A.Novelline, Lucy Frank Squire	-	+ (but orientation is not mentioned in some cross-sections)	-
A cross-sectional anatomy: Albert C. Eycleshymer, Daniel M. Shoemaker	+	-	-

(For some of the books, the older editions were not available in the library.)

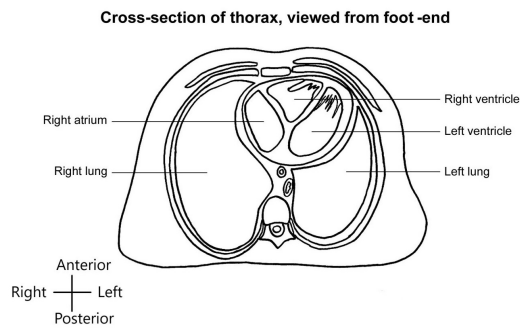


Fig. 2:

structures and their relations of various organs are described even when the body is lying on the back in the bed, or in the dissecting table, assuming as if the person is standing upright with the feet together and the head and eyes are looking to the front, with the arms straight by the side and the palms of the hands facing forwards. I assume that this may be the reason for describing the cross-sectional images from the head end in those days.

Albert Einstein said, "I never teach my pupils, I only provide the conditions in which they can learn." Thus to meet the demands of the students learning cross-sectional anatomy to identify the structures in CT, MRI where the equipment produces images as viewed from the foot end up, the authors of the Anatomy and Cross-sectional Anatomy books have changed their approach and nowadays, in all the atlases, the orientation of the image is in line with the CT/MRI axial images.^{2,3,8-18}

"A Cross sectional Anatomy" by C. Eycleshymer A, M. Schoemaker D. (published in 1911), projected the cross-sections from the head end. Even the Cunningham's Manual of Practical Anatomy upto the 15th edition also displayed the cross-sections from the head end. But the recent edition (16th edition) displays the cross-sections from the foot end.

To summarise, the cross-sections of thorax, abdomen were described from foot end by most of the textbooks, while the cross-sections of the extremities and brain were given in different patterns in different textbooks and for some of the cross-sections through neck and extremities, the orientation was not mentioned.

Identifying a correct side is important in the medical practice. For example, when an externally invisible unilateral tumour requiring surgical excision is diagnosed, there should not be any error of identifying the correct side. If learning cross sectional anatomy and subsequent imaging anatomy are in the same orientation, a potential scope for wrong identification of the side can be avoided.

The front cover of the 41st edition of Gray's Anatomy, The Anatomical basis of Clinical Practice shows the image of orientation of the white fibres in the brain using "Advanced Diffusion Tractography". For me, this implies that the anatomists understood the need to revise the

traditional methods of teaching anatomy and to integrate with other basic sciences and clinical teaching.

References

1. Anatomy Atlases: Atlas of Human Anatomy in Cross Section: Introduction and Explanatory Note; July 2017; 2017. Available from: <http://www.anatomyatlases.org/HumanAnatomy/IntroExplanatoryNote.shtml>.
2. Why Study Cross-Sections? July 2017; 2017. Available from: http://webanatomy.com/CSA/cross_objectives.asp.
3. The National Library of Medicines Visible Human Project; July 2017. Available from: https://www.nlm.nih.gov/research/visible/visible_human.html.
4. Oh CS, Kim JY, Choe YH. Learning of cross-sectional anatomy using clay models. *Anat Sci Educ.* 2009;2(4):156-159.
5. Head CT 2017. Available from: <https://www.meded.virginia.edu/courses/rad/headct/anatomy.html>.
6. Jr TDJ, Emmons KA, Sim KT, Ang EC, Goldstein B, Fleming AW, et al. The Utilization of Cross-Sectional Anatomy in a Surgical Residency Training Program. *J Natl Med Assoc.* 1987;79(3):289.
7. A CE, D MS. A Cross sectional Anatomy. Appleton and Company; 1911; 1911.
8. S AK, Heitzman ER. An Atlas of cross-sectional anatomy. Harper & Row Publishers; 1979; 1979.
9. and J J Carr JBW, and T Woleman N AKW, R LB. Basic Atlas of Sectional Anatomy with correlated imaging. 4th edition. Reed Elsevier India Private Ltd; 2009.
10. Ellis H, B ML, A KD. Human Sectional Anatomy, Atlas of body sections, CT and MRI images. 3rd edition. Hodder Arnold Education; 2007.; 2007.
11. Living Anatomy. C.V. Mosby Company; 1987; 1987.
12. Hagens GV, L LR, M HR, Tiedemann K. The visible human body an atlas of sectional anatomy. and others, editor. K M Varghese Company; 1991.
13. R RP. Workbook for cross-sectional anatomy. R.R.Peterson Publications; 1982;.
14. Ellis H. Clinical Anatomy A Revision and Applied Anatomy for Clinical Students. 11th edition. and others, editor. Balckwell Publishing Ltd;.
15. R SS. Clinical Anatomy by Regions. 9th edition. Lippincott: Williams and Wilkins;.
16. K LM, A FD, A MRA. Clinically Oriented Aantomy. 7th edition. and others, editor. Lippincott: Williams and Wilkins;.
17. Romanes GJ. Cunningham's Manual of Practical Anatomy. 15th edition. vol. 2. and others, editor. Oxford University Press;.
18. Standring S. Gray's Anatomy The Anatomical Basis of Clinical Practice. 41st edition. Elsevier;.

Author biography

S Rajalakshmi Post Graduate Registrar

Shyamkumar N Keshava Professor

Aparna Irodi Professor

Suganthi Rabi Professor

Cite this article: Rajalakshmi S, Keshava SN, Irodi A, Rabi S. Cross sectional anatomy - need for uniformity in the display of medical images or line diagram while representing the anatomical structures. *Indian J Clin Anat Physiol* 2019;6(4):515-517.