



Original Research Article

Evaluation of osteometric parameters of fibula and talar facet morphometry in Telangana region

Peter Ericson Lingamdenne^{1,*}¹Dept. of Anatomy, Kamineni Academy of Medical Sciences and Research Center, Hyderabad, Telangana, India

ARTICLE INFO

Article history:

Received 08-11-2019

Accepted 25-11-2019

Available online 31-12-2019

Keywords:

Fibula

Neck

Lateral malleolus

Talar facet

ABSTRACT

Introduction: Fibula the slender lateral bone of the leg has vast clinical and surgical application. The various osteometric parameters from both the ends and intervening shaft can be used to accurately assess the stature, nutritional status of an individual, determine the identity and gender, and aid in evaluation and surgical management of different ankle pathologies.

Objective: The aim of this study was to evaluate osteometric parameters of fibula and Talar facet morphometry in Telangana region. Statistical analyses of these measurements, regional comparisons and correlations between these measurements are presented in this paper.

Materials and Methods: Anthropometric evaluation of 74 dry, complete adult human fibulae was done. Measurement of 10 osteometric variables from different parts of the fibula and morphological analysis of talar facet have been undertaken results statistically analysed and tabulated.

Results and Conclusions: The precise osteometric measurements of adult fibula in Telangana region have been presented in this paper. Significant correlation was found between the maximum length, mid shaft circumference, neck circumference, upper and lower epiphyseal breadth. This data has vast anthropometric, clinical, surgical, forensic and demographic application.

© 2019 Published by Innovative Publication. This is an open access article under the CC BY-NC-ND license (<https://creativecommons.org/licenses/by/4.0/>)

1. Introduction

Fibula is the slender lateral bone of the leg. The upper end of the fibula gives attachments to ligaments of knee joint but does not form a direct articular component of the knee joint. The proximal end of the fibula has the head, irregular in shape, and a round facet is present on its proximo-medial aspect. The facet articulates with the lateral tibial condyle via a plane synovial joint. A styloid process, projects proximally from the postero-lateral aspect of the head. The borders of the shaft spiral, and the shape varies, due to pull of the attached muscles. The lower end of the fibula has the lateral malleolus the lateral aspect of which can be palpated subcutaneously. A triangular facet, the Talar facet is present on its medial surface; behind it is the malleolar fossa which gives attachments to the posterior tibio-fibular and posterior talo-fibular ligaments. Distal end of the fibula takes part in

the Talo-crural joint.¹

The fibula is the only bony component of a continuous osseo-musculo-fascial system starting from the sacroiliac joint extending along biceps femoris, peroneus longus, ankle joint and arches of foot. It transmits 7-30% load in different positions of the ankle joint, and places an important role in the biomechanics of the lower limb.²

Estimation of the height of an individual can be determined from the length of fibula by using standardised ratios.^{3,4} The fibula is least affected by arthritis⁵ and osteoporosis, its measurements can be used to assess the stature, and nutritional status in the elderly.⁶

The common fibular nerve in its course is related to the head and neck of fibula. It can be compressed or entrapped as it crosses the head due to external compression due to prolonged cross legged position, yoga palsy, casts, and ill-fitting knee braces. Traumatic fracture of the fibular neck can also injure the nerve. The symptoms can vary between

* Corresponding author.

E-mail address: peterericson7@gmail.com (P. E. Lingamdenne).

numbness on the lateral side of the neck, and a complete foot drop due to the palsy of the muscles of the anterior and lateral compartments of the leg.⁷

Free vascularized fibular flap is used in several reconstructive surgeries especially in oro-maxilla-facial region, due to the feasible use of it as linear long graft, better cosmesis,⁵ easy accessibility, and proven reliable graft survival rate.⁸

Incongruent articular surfaces of the ankle joint due to congenital, post traumatic sequelae, secondary to neuromuscular disorders can affect tibio -femoral joint and the upper tibio-fibular joint.⁹ Ankle pathologies can present as pain around the knee or, knee pathologies can present as pain around the ankle joint warranting a concurrent examination and evaluation of both joints.

Understanding the detailed anatomy of lateral ligament complex of the ankle joint with their relationships to the osseous structures and biomechanics of the ankle can help understand ankle pathologies and successful treatment.¹⁰

Evaluation of isolated lateral malleolar fracture or bimalleolar fracture requires knowledge of the morphology of distal fibula, and treatment by complete anatomical reduction of lateral malleolus prevents the development of degenerative arthritis.¹¹

Osteometric measurements of different parts of the fibula, particularly the distal fibula are used to determine the sex of the bone.¹²

The osteometric data of fibula is limited in literature and very few studies have been done where the complete fibula has been evaluated. Due to this extensive clinical application, forensic and demographic significance of the fibula and lack of adequate studies on fibula our present study was undertaken. The fibula was extensively studied and evaluated. Ten osteometric parameters from both its ends, intervening shaft were measured and correlations between them were statistically analysed. The sides of the irregular triangular talar facets were measured and the angles calculated.

2. Materials and Methods

In our study 74 complete, intact, adult fibulae of unknown gender with distinguishable clear features were sourced from the bone bank. Deformed, incomplete, broken fibulae were excluded from our study.

Of the seventy four fibula 43 belonged to the right side, 31 to the left side.

Osteometric linear measurements were done using osteometric board and a digital sliding Vernier calliper's. Measuring tape was used for circumferential measurements

The following parameters were measured in each fibula.

1. Maximum length of the fibula (Figure 1A): Distance from the apex of the fibular head to the furthest point of the lateral malleolus.

2. Circumference of the neck (Figure 1B).
3. Mid-shaft circumference (Figure 1C): Circumference taken at the mid shaft with a measuring tape
4. Mid-shaft Antero posterior diameter (Figure 2A).
5. Mid shaft Transverse diameter (Figure 2B).
6. Upper epiphyseal breadth distance between medial & lateral sides of the fibula Head (Figure 2C).
7. Oval facet maximum longitudinal diameter (Figure 2D).
8. Oval facet maximum transverse diameter (Figure 2D).
9. Depth of malleolar fossa (Figure 3A).
10. Distal epiphyseal breadth: maximum width of the lateral malleolus (Figure 3B).

2.1. The talar facet

1. The measurements of the base, antero-medial, and postero-medial distances of the facet were taken (Figure 3C).
2. Three angles were calculated (Figure 3D).

- (a) Between antero-medial and postero-medial sides
- (b) Between postero-medial side and base
- (c) Between antero-medial side and base

The measurements were taken twice by the same author and the data analysed using IBM SPSS 2019.

Mean values and Pearson correlation coefficient values were calculated and the results tabulated.



Fig. 1: Osteometric measurements of fibula
A: Maximum length, **B:** Neck circumference, **C:** Mid-shaft circumference

3. Results and Discussion

Though the fibula has a minor role in weight bearing, its extensive clinical importance in various ankle pathologies, and its invaluable use as free vascularised surgical flap in reconstructive surgery especially in the oro-maxillo-facial

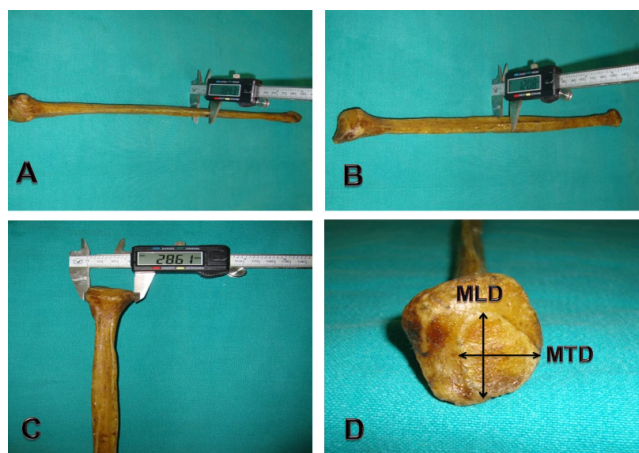


Fig. 2: Osteometric measurements of fibula (continued)

A: Mid shaft Antero-Posterior diameter, **B:** Mid shaft transverse diameter, **C:** Upper epiphyseal breadth, **D:** Oval facet: Maximum longitudinal diameter (MLD), Maximum transverse diameter (MTD).




Fig. 3: Osteometric measurements of fibula (continued)

A: Malleolar fossa depth, **B:** Distal epiphyseal breadth, **C:** Talar facet, **D:** Talar facet angles: (a) between antero-medial and postero-medial sides, (b) between postero-medial side and base, (c) between antero-medial side and base

region have motivated this study to measure, analyse, and correlate the different osteometric parameters of fibula.

In our present study the maximum length showed strong correlation with the neck and mid shaft circumference (Table 3). We found the maximum length of the fibula to be 35.96cm. Westeous Dominic et al⁴ reported values of 39.85 cm among South Indian population, while Naidoo et al⁵ observed values of 36.36cm to 38.04cm in the south African population. Auyeung et al⁶ reported values of 36cm in males and 32cm in females in Japanese population whereas Yoshiaki et al⁸ observed values of 38.74cm and 36.15cm in male and female fibula respectively among the Canadian

population. In both these studies the maximum length was higher in males as compared to females. Pedzisai et al¹³ reported similar values of 34.93 cm in the South African population. Bazin et al¹⁴ observed values of 37.05 cm in the French, and Aliya et al¹⁵ observed values of 34.69cm and 34.90cm among Pakistani population in left and right fibula respectively.

Fibula is least affected by arthritis and osteoporosis and other age related degenerative changes. It can be used to assess nutritional status in different age groups including the elderly.⁶

For jaw reconstruction the maximum length of the fibula is of paramount importance in planning the operation; based on the maximum length the graft is taken leaving a 6-7cm bone below the fibular head, and around 8-10 cm proximal to lateral malleolus.⁸ Knowledge regarding the anatomy of fibula is vital for a successful reconstructive surgery and good functional recovery post-surgery.¹⁶

The common fibular nerve is related to the neck of the fibula.¹ Injury to the nerve at this level can lead to foot drop.⁷ In our present study we recorded the neck circumference value as 3.39cm. After a thorough and extensive search of literature, studies measuring this parameter could not be found. The neck circumference (Table 3) showed a strong correlation with the maximum length of fibula ($p < .001$). This data could help in reconstruction of the fibula and aid further demographic studies of fibula.

In our study three measurements were taken at the mid-shaft level, circumference, antero-posterior and transverse diameters, and the values of 3.94cm, 13.67mm, and 10.86 mm were observed respectively. Similar values for mid-shaft circumference of 3.9cm right fibulae and 4.0cm left fibulae were reported among males in south Indian population by K Aparna Devi et al.¹² She observed comparatively lower values in females of 3.3cm and 3.2 cm in right and left fibula respectively. In our present study the maximum length of the fibula showed a significant ($p < 0.01$) correlation with the mid shaft circumference.

In our study the upper epiphyseal breadth was 20.98mm, and the oval facet maximum longitudinal and maximum transverse diameters were observed to be 13.67mm and 10.86mm respectively. In arthritis of knee joint especially of the medial compartment, proximal fibular osteotomy is emerging as the treatment modality for relieving pain and improvement of joint function.¹⁷

The upper fibular osteometric data can be used perioperatively for effective results.

Table 1: Measurement of fibula parameters

Measurements of fibula	Mean	Standard Deviation	Minimum	Maximum
Max length (cm)	35.96	2.93	31.00	40.00
Neck circumference (cm)	3.39	.50	2.60	4.70
Mid shaft circumference(cm)	3.94	.50	3.20	4.90
Mid shaft Antero-Posterior diameter(mm)	13.67	2.07	9.84	18.54
Mid shaft transverse diameter (mm)	10.86	1.63	8.19	14.05
Upper epiphyseal breadth (mm)	20.98	3.08	14.59	29.38
Oval facet maximum longitudinal diameter (mm)	15.35	3.06	10.48	21.54
Oval facet maximum transverse diameter (mm)	13.76	2.75	8.20	18.70
Malleolar fossa depth (mm)	2.63	.56	1.74	3.81
Distal epiphyseal breadth (mm)	16.88	2.36	13.01	22.81

Table 2: Measurement of talar facet

Measurements of Talar facet	Mean	Standard Deviation	Minimum	Maximum
Antero-Medial (mm)	18.62	2.45	14.00	24.20
Postero-Medial (mm)	19.76	2.17	15.54	25.66
Base (mm)	17.90	2.19	13.40	21.94
Anteromedial-Posteromedial ^o	59.26	8.61	40.06	77.81
Posteromedial- Base ^o	65.12	6.27	49.17	74.95
Anteromedial -Base ^o	55.61	7.71	39.65	72.29

Table 3: Pearson correlation coefficients between Fibula osteometric parameters

Measurements of Fibula		Maximum length	Neck circumference	Mid-shaft circumference
Maximum length	Pearson Correlation	1	.529**	.664**
	Sig. (2-tailed)		.003	.000
Neck circumference	Pearson Correlation	.529**	1	.741**
	Sig. (2-tailed)	.003		.000
Mid-shaft circumference	Pearson Correlation	.664**	.741**	1
	Sig. (2-tailed)	.000	.000	
		30	30	30

** . Correlation is significant at the 0.01 level (2-tailed).

Table 4: Pearson correlation coefficients between Fibula osteometric parameters (continued)

Measurements of Fibula		Maximum length	Upper Epiphyseal breadth	Lower Epiphyseal breadth
Maximum length	Pearson Correlation	1	.573**	.513**
	Sig. (2-tailed)		.001	.004
Upper Epiphyseal breadth	Pearson Correlation	.573**	1	.370*
	Sig. (2-tailed)	.001		.044
Lower Epiphyseal breadth	Pearson Correlation	.513**	.370*	1
	Sig. (2-tailed)	.004	.044	
		30	30	30

** . Correlation is significant at the 0.01 level (2-tailed).
* . Correlation is significant at the 0.05 level (2-tailed).

K. Aparna Vedapriya et al¹² in her study of cadaveric fibula, observed that the maximum length, distal end width, and mid shaft circumference, can be used to determine the sex of the fibula. She reported values of 2.4cm and 2.1cm for the distal width in males and females respectively. In our study the gender of the fibula was unknown; we observed mean values of 1.68cm for distal epiphyseal breadth. The distal epiphyseal breadth (Table 4) showed strong correlation with the maximum length of the fibula ($p < 0.01$). We measured the maximum depth of the malleolar fossa to be 2.63mm.

In the management of isolated lateral malleolar fracture or bimalleolar fracture requires a thorough understanding of the morphometry of distal fibula. Complete reduction of lateral malleolus, in the treatment of bimalleolar fractures prevents the talar tilt and the development of degenerative arthritis. This point was proven in cadavers, where bimalleolar fractures were created and the talus could be anatomically repositioned only when the lateral malleolus was accurately reduced.¹¹

Ankle joint ligament repair via arthroscopy requires both descriptive and osteometric data of the distal fibula. The lateral malleolus can be palpated subcutaneously and serves as an important landmark to measure the distance for placement of the arthroscopic portals for the surgical procedure.¹⁸

The morphological parameters of the distal fibula especially the lateral malleolus show regional and ethnic^{5,14} variations. This data plays a key role in accurate designing and usage of a fibular nail.^{19,20}

The Antero-medial distance, Postero-medial distance and base of the talar facet were 18.62mm, 19.76mm and 17.90mm respectively in our study. Naidoo et al⁵ in their studies on the south African population reported values of 19.18mm, 20.40mm, 18.77mm in males and 18.39mm, 18.21mm, and 17.14mm in females for the Antero-medial distance, Postero -medial distance and base respectively. They observed angles between antero -medial and postero-medial sides, postero-medial side and base, Antero-medial side and base as 56.6⁰, 58.5⁰, and 64.9⁰ in males and 55.7⁰, 62.8⁰, and 61.6⁰ in females respectively. In our study we observed values of 59.26⁰, 65.12⁰ and 55.61⁰ for the three respective angles.

The complete osteometric data is of immense value in forensics to establish the gender and identity of the individual. It can also be used to determine the mechanism of injury, bone Fragment analyses, and reconstruction of the fibula.²¹

4. Conclusions

Ten parameters of the fibula and six parameters of the talar facet in a South Indian population have been measured, statistically analysed, and presented in this paper. Correlation between different parameters of the fibula,

comparison with available studies from different regions revealed variations attributable to regional and ethnic differences. These parameters can be used to accurately assess the stature, nutritional status of an individual, determine the identity and gender, aid in evaluation and surgical management of different ankle pathologies including designing of suitable implants. They have extensive application in forensic sciences and contribute to demographic studies.

5. Conflict of interest

None

6. Source of funding

None.

References

1. Susan S. Grays anatomy: The anatomical basis of clinical practice. 41st edition ; 2016.
2. Wang, Qian, Whittle, Michael, Cunningham, et al. Fibula and its ligaments in load transmission and ankle joint Stability. *Clin Orthop Relat Res.* 1996;330:261–270.
3. Nihal A, Fateh M, Ibrahim F, Shivkumar B. Estimation of height from the long bones of lower limb and foot dimensions in South Indian Population. *J Evid Based Med Healthc.* 2014;1(8):884–892.
4. Westeous D. Estimation of height of an individual in correlation with the length of the fibula. *Int J Pharm Sci Rev Res.* 2017;44(2):77–79.
5. Naidoo N, Ishwarkumar S, Lazarus L, Pillay P, Satyapal KS. Osteometry and morphology of the human fibula: A South African study. *Int J Morphol.* 2015;33(3):1071–1077.
6. Auyeung TW, Lee JS, Kwok T, Leung J, Leung PC, Woo J. Estimation of stature by measuring fibula and ulna bone length in 2443 older adults. *J Nutr Health Aging.* 2009;13(10):931–936.
7. Anderson JC. Common Fibular Nerve Compression: Anatomy, symptoms, clinical evaluation and surgical decompression. *Clin Podiatr Med Surg.* 2016;33(2):283–291.
8. Yoshiaki I, Satoru M, Jeffrey H, Daniel OC, Hadi S, Johan W. Anatomical examination of the fibula: digital imaging study for osseointegrated implant installation. *J Otolaryngol Head Neck Surg.* 2015;44(1):1.
9. Sutro CJ, Sutro WH. The clinical importance of articulations of the fibula. *Bull Hosp Jt Dis Orthop Inst.* 1982;42(1):68–79. Spring.
10. Uğurlu M, Bozkurt M, Demirkale I, Cmert A, Acar HI, Tekdemir I. Anatomy of the lateral complex of the ankle joint in relation to peroneal tendons, distal fibula and talus: a cadaveric study. *Eklem Hastalik Cerrahisi.* 2010;21(3):153–158.
11. Yablon IG, Heller FG, Shouse L. The key role of the lateral malleolus in displaced fractures of the ankle. *J Bone Joint Surg Am.* 1977;59(2):169–173.
12. Vedapriya KA, Rajasre TK. Determination of sex based on adult Fibula. *Int J Biol Med Res.* 2013;4(2):3199–3209.
13. Pedzisai M, Brendon B. Topographic and morphometric features of the nutrient foramina of the fibula in the South African mixed-ancestry population group and their surgical relevance. *Eur J Anat.* 2016;20(4):329–336.
14. Bazin I, Armendariz M, Marcheix PS, Pichon M, Fredon F, et al. A computed tomography study of the fibula: morphology, morphometry, intramedullary anatomy, application prospects on intramedullary nailing. *Foot Ankle Int.* 2008;29(1):77–81.
15. Aliya Z, Muhammad A, Raana S. Morphological and topographical anatomy of diaphyseal nutrient foramina of dried Pakistani fibulae. *J Coll Physicians Surg.* 2015;25(8):560–563.

16. Chandni G, Vikram P, Nivedita N, Jitendra S, Yadav, Sneha GK. A morphometric study of distal articulating surfaces of tibia and fibula in South Indian population with its clinical implications. *Int J Pharm Sci Rev Res.* 2017;42(2):36–38.
17. Wang X, Wei L, Lv Z, Zhao B, Duan Z, et al. Proximal fibular osteotomy: a new surgery for pain relief and improvement of joint function in patients with knee osteoarthritis. *J Int Med Res.* 2017;45(1):282–289.
18. Masato T, Mark G, James S, Stephane G. M D F Ankle arthroscopic reconstruction of lateral ligaments. *Ankle Anti-ROLL) Arthrosc Tech.* 2015;4(5):595–600.
19. Bugler KE, Watson CD, Hardie AR. The treatment of unstable fractures of the ankle using the Acumed fibular nail: development of a technique. *Bone Joint J.* 2012;94(8):1107–1112.
20. Tracey J, Vovos TJ, Arora D, Adams S, Parekh SG. The use of modern intramedullary nailing in distal Fibula fracture fixation. *Foot Ankle Spec.* 2019;12(4):322–329.
21. Savka IG. Forensic morphological signs characterizing stability of the femur, tibia and fibula during effect of external destructive load. *Wiad Lek.* 2019;72(2):198–200.

Author biography

Peter Ericson Lingamdenne Associate Professor

Cite this article: Lingamdenne PE. Evaluation of osteometric parameters of fibula and talar facet morphometry in Telangana region. *Indian J Clin Anat Physiol* 2019;6(4):497-502.