



## Original Research Article

## Nutrient foramen of clavicle an anatomical and a topographic study

Sharmada K L<sup>1</sup>, Kavya<sup>1,\*</sup>, Sowmya S<sup>1</sup><sup>1</sup>Dept. of Anatomy, Bowring and Lady Curzon Medical College and Research Institute, Bangalore, Karnataka, India

## ARTICLE INFO

## Article history:

Received 11-12-2019

Accepted 17-12-2019

Available online 31-12-2019

## Keywords:

Clavicle

Nutrient foreman

Long bone

## ABSTRACT

**Introduction:** The collar bone is an atypical long bone having a nutrient foramen in the middle one third of the clavicle, along its superior border. The knowledge of the neurovascular foramina of the clavicle is clinically important as the structures are routinely dealt in surgical practice. The aim of the present investigation was to study the topographic anatomy and morphology of the neurovascular foramina in human adult clavicles as it is enlightening for the operating surgeon in vascularized bone grafts surgeries.

**Materials and Methods:** The study included 104 adult clavicles (54 right sides and 50 left) of unknown age and sex without any external damage, which were obtained from the osteology section of the anatomy laboratory of our department. All the bones were observed using a magnifying lens for the number, location, and direction of the nutrient foramina. The data were collected on a standardized sheet and morphologically analyzed. Results and conclusions

**Results and Conclusions:** The neurovascular foramina were observed in 101 (97.11%) clavicles and found absent in 3 clavicles (2.88%), the foramen was observed on the posterior surface contrary to mentioned in literature. The present study has provided additional information about the topographical anatomy and morphology of the foramina of this bone. Knowledge of the localization of nutrient foramina can be useful in certain surgical procedures to preserve the circulation. As the microvascular bone transfer is becoming more popular, we believe that a convention for the accurate anatomical description of these foramina is important.

© 2019 Published by Innovative Publication. This is an open access article under the CC BY-NC-ND license (<https://creativecommons.org/licenses/by/4.0/>)

## 1. Introduction

Nutrient foramen is an opening into the bone shaft for passage of blood vessels into the bone for its nourishment and growth, which is very vital for its development in the embryonic and fetal life.<sup>1</sup> The clavicle it develops intramembranous and is the last bone to complete ossification and first to begin the process.<sup>2</sup> It is the only long bone to lie horizontally displaying a double curvature. As known all bones have nutrient foramen, classically literatures describes that the clavicle has a small foramen present at the superior border at the middle one third of the bone transmitting nutrient artery and occasionally supraclavicular nerve.<sup>2</sup> Various authors observed that Clavicle is supplied by periosteal artery<sup>3</sup>

and suprascapular artery.<sup>4,5</sup> Supraclavicular nerve can get entrapped and cause Supraclavicular nerve entrapment syndrome, hence the through knowledge of the Foramina is very essential.

## 2. Aim

The aim of this study is to understand the detailed topographic anatomy of the neurovascular foramen in human adult clavicle to enlighten the operating surgeons the variations that could be encountered and prevent further complications.

## 3. Materials and Methods

The present study was conducted on 104 (54 right sides and 50 left) adult clavicle of unknown age and sex without an

\* Corresponding author.

E-mail address: [kavs.084@yahoo.co.in](mailto:kavs.084@yahoo.co.in) (Kavya).

external damage from the department of Anatomy. All the bones were observed for the number of foramina, position location and direction. The data were collected on a standardized sheet and morphologically analyzed.

#### 4. Results

From 104 clavicle various parameters were observed and noted as below mentioned.

#### 5. Discussion

Long bones get their arterial supply from the nutrient artery, the supply from these arteries is vital and essential during active growth period and in yearly ears of ossification.<sup>6</sup> The direction and position of the nutrient foramina is towards the growing end of the long bone in mammalian bone which can be variable at times and may alter during growth.<sup>7</sup> Since clavicle lacks medullary cavity, absence of nutrient foramina can be justified<sup>8</sup> and therefore does not depend on nutrient artery for its nutrition.<sup>3</sup>

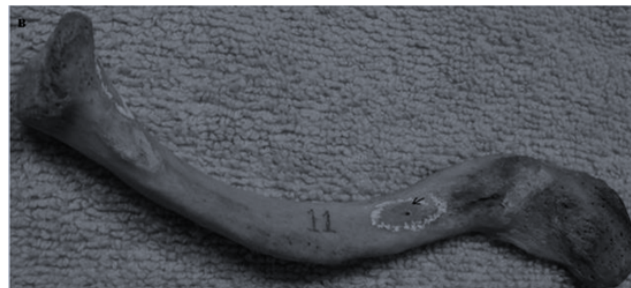In this study the neurovascular foramina were present in 97.11% of clavicle and majority of the foramina (93.2%) was directed towards the lateral end, indicating the medial end of the bone as the growing end supporting similar study by Havet et al.,<sup>5</sup> Fischer and Carret,<sup>4</sup> Kumar et al.<sup>2</sup> Multiple foramina's was observed in majority along with topographic location of the foramina's being situated in the middle 1/3 of the clavicle in most of the cases.

Standard textbooks of anatomy state that the foramina were present at the inferior surface. But in the present study, we observed that in 44.2 % of the cases the foramina were present at the posterior surface (Figure 1) and were present at the inferior surface in 52.8% of the clavicles (Figure 2) and 2.8% of the clavicle had foramen at its superior surface (Figure 3).

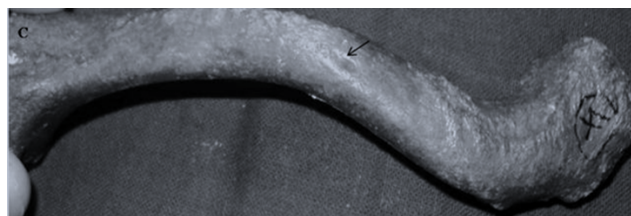
5- 10% of clavicular fracture occur in middle 1/3 due to the natural double curvature of the bone.<sup>5</sup> They reported that periosteal artery was always present on the superior surface and anterior border of the clavicle, but never on the inferior surface or posterior border. Their results showed that the periosteal arteries located between the muscular insertions could be compromised in case of displacements or fracture. They concluded that, if the clavicular fractures or non-unions cannot preserve the periosteal blood supply, bone grafting should be done.<sup>1</sup>

Nutrient foramina contain fascicle of the supraclavicular nerve along with nutrient artery as reported by Kumar et al.<sup>2</sup> Gelberman et al.<sup>9</sup> defined the supraclavicular nerve entrapment syndrome, the nerve injury has been attributed to the location of the branch of the supraclavicular nerve in the narrow canal of the clavicle.<sup>8</sup> Shohei et al.<sup>10</sup> reported that they have treated two patients who had entrapment neuropathy of the supraclavicular nerve attributable to an osseous tunnel of the clavicle and decompression of

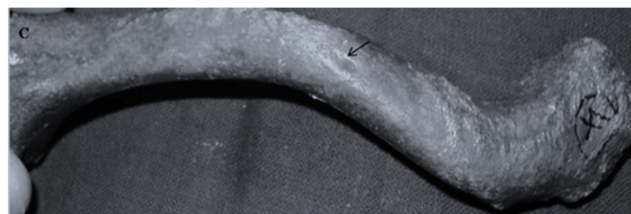
the entrapped nerve relieved symptoms in both patients. Fibrous and muscular structures in addition to nutrient canal contents could also be an Anatomical basis for the supraclavicular nerve entrapment syndrome as suggested by Jelev and Surchev.<sup>8</sup>



**Fig. 1:** Clavicles showing the nutrient foramen at the inferior surface



**Fig. 2:** Clavicles showing the nutrient foramen at the inferior surface



**Fig. 3:** Clavicles showing the nutrient foramen at the superior surface

#### 6. Conclusion

The present study shows that the nutrient foramina in the clavicle was present not only in the inferior surface but also present on the posterior surface in great numbers and majority of Clavicle had multiple foramens that outnumbered the clavicle with single foramen in contrary to described in classically Anatomy text books. The study on foramina of collar bone are limited, hence this study provides additional information about the morphology of the foramina in this atypical long bone. Knowledge of localization of nutrient foramina can be useful in wile operating through the bone in tissue salvaging procedures.

**Table 1:**

Structure observed	No	No	
Neurovascular Foramen	Present 101(97.11%)	Absent 3(2.88%)	
Number of Neurovascular seen	Single foramen 31(39.42%)	Double foramen 46(44.2%)	Multiple foramen 13(12.5%)
Region of the Foramen seen	Medial 1/3 9(8.6%)	Middle 1/3 97(93.2%)	Lateral 1/3 2(1.9%)
Surface of the bone Foramina was observed	Inferior 55(52.8%)	Posterior 46(44.2%)	Superior 3(2.88%)
Direction of the Foramina	Towards the lateral end 97(93.2%)	Towards the medial end 7(6.72%)	

**Table 2:** Showing the topographical distribution of the NF of the clavicle with respect to side

Topography of NF	Right side	Left side	Total
at posterior surface	20 (19.13%)	26(24.86%)	46 (44.2%)
at inferior surface	32 (30.25%)	23(21.74%)	55 (52.8%)
at superior surface	3(2.9%)	nil	3 (2.9%)
at middle 1/3 part	56 (53.80%)	41(39.39%)	97 (93.2%)
at medial 1/3 part	2 (1.91%)	7 (6.69%)	9 (8.6%)
at lateral 1/3 part	2 (1.9%)	Nil	2 (1.9%)

NF – nutrient foramina

We believe that a convention for the accurate anatomical description of these foramina is important.

## 7. Source of funding

None.

## 8. Conflict of interest

None.

## References

1. Udayasree L, Ravindranath G, Maheswari KB, Prasad GVS. Anatomical study of nutrient foramina in dried human upper limb bones and their clinical significance. *J Evolution Med Dent Sci*. 2017;6(2):110–113.
2. Kumar R, Lindell MM, Madewell JE, David R, Swischuk LE. The clavicle: Normal and abnormal. *Radiographics*. 1989;9:677–706.
3. Knudsen FW, Andersen M, Krag C. The arterial supply of the clavicle. *Surg Radiol Anat*. 1989;11:211–214.
4. Fischer LP, Carret JP. Vascularisation artrielle des os chez l'homme. *Bull Assoc Anat*. 1978;62:419–454.
5. Havet E, Duparc F, Tobenas-Dujardin AC, Muller JM, Delas B, Freger P. Vascular anatomical basis of clavicular non-union. *Surg Radiol*. 2008;30:23–28.
6. Kizilkanat E, Boyan N, Ozsahin ET, Soames R, Oguz O. Location, number and clinical significance of nutrient foramina in human long bones. *Ann Anat*. 2007;189:87–95.
7. Henderson RG. The position of the nutrient foramen in the growing tibia and femur of the rat. *J Anat*. 1978;125:593–599.
8. Jeleu L, Surchev L. Study of variant anatomical structures (bony canals, fibrous bands, and muscles) in relation to potential supraclavicular nerve entrapment. *Clin Anat*. 2007;20:278–285.
9. Gelberman RH, Verdeck WN, Brodhead WT. Supraclavicular nerve-entrapment syndrome. *J Bone Joint Surg Am*. 1975;57:119.
10. Shohei O, Yasuhito T, Yoshizumi M, Tatsuya K, Yoshinori T. Traction neuropathy of the supraclavicular nerve attributable to an osseous tunnel of the clavicle. *Clin Orthop Relat Res*. 2005;431:238–240.

## Author biography

**Sharmada K L** Tutor

**Kavya** Assistant Professor

**Sowmya S** Associate Professor

**Cite this article:** Sharmada K L , Kavya , Sowmya S . Nutrient foramen of clavicle an anatomical and a topographic study. *Indian J Clin Anat Physiol* 2019;6(4):454-456.