

# A Study of Various Forms of Mandibular Coronoid Process in Determination of Sex

Mouna Subbaramaiah<sup>1,\*</sup>, Roshni Bajpe<sup>2</sup>, S.R.Jagannatha<sup>3</sup> K.S. Jayanthi<sup>4</sup>

<sup>1</sup>Assistant Professor, <sup>2</sup>Professor, Department of Anatomy, <sup>3</sup>Associate Professor, Department of Forensic Medicine, Kempegowda Institute of Medical Sciences(KIMS), Bangalore.

<sup>4</sup>Professor, Department of Anatomy, Vydehi Institute of Medical Sciences(VIMS), Bangalore.

**\*Corresponding Author:**

E-mail: mounagowda123@rediffmail.com

## ABSTRACT:

The coronoid process of the mandible is gaining vital importance as a graft material in reconstructive craniomaxillofacial surgeries and as a non metric skull variant in assessment of age, sex, race and species. Hence the present study was taken to assess the different forms of the coronoid process existing in Indian adult population on both sides and to assess the feasibility of using this knowledge in identification of sex. The study includes 50 male and 50 female mandibles which were collected from various medical colleges. The various presentations of coronoid process were observed and broadly classified, on both the sides. Statistical analysis was calculated using Chi-square test. Hook shaped coronoid process was the most predominant type (61.5%) followed by triangular (14%) and rounded (12.5%) types. About 12% belonged to the miscellaneous type. Hook shape coronoid process was significantly higher in the females. The other shapes did not show any significant gender variation. From the present study it was inferred that the structural changes at the coronoid process of mandible help oneself to distinguish the gender of the individual.

**Keywords:** Coronoid process; Mandible; Shape variation; Sex determination; Hook shape

Access this article online	
Quick Response Code:	Website: www.innovativepublication.com
	DOI: 10.5958/2394-2126.2015.00020.1

## INTRODUCTION

The coronoid process derived from a Greek word korone (meaning crow's beak) is a flat piece of triangular bone projecting upwards from the anterior margin of the mandibular ramus<sup>1</sup>. Coronoid or condylar process cannot be distinguished in the early stage of mandibular development. At 24mm stage (55<sup>th</sup> day) these processes begin to be mapped out in membrane and by 43mm stage (70<sup>th</sup> day) it will take the form as bony processes. At around 13<sup>th</sup> week of intrauterine life, a strip of cartilage appears along the anterior border of coronoid process which is invaded and displaced by the membrane bone.<sup>2</sup> This cartilage usually disappears before birth but can persist as subcoronoid sutures<sup>2,3</sup>.

Literature search suggest varying form of coronoid process in adult human mandibles. Early back in 1915 Schaffer called it beak shaped process while Schulz in 1933 described it being S-shaped, undulant and low symmetrical. Sable like curvature of the process was interpreted as a manifestation of ageing<sup>3,4</sup>. Thereafter most authors like Hamilton, Basmajian, Williams have described it as triangular process<sup>5,6,1</sup>. Presence of a double or second coronoid

process has also been cited<sup>7</sup>. The shape of ramus is species specific amongst primates. Human ramus resembles that of a chimp with relatively slender coronoid process (particularly at its tip), shorter in height, separated from the condylar process by a deep notch. Several other primates resemble gorillas having a broad coronoid process and separated by a shallow mandibular notch<sup>8</sup>. Recently studies undertaken by Isaac, Narayana and P. Ranganath has found various forms of coronoid process that are evident in human mandibles like triangular, rounded, hook shaped, rectangular, flattened etc<sup>9,10,11</sup>.

The coronoid process of the mandible is gaining vital importance as a graft material in all aspects of reconstructive cranio-maxillofacial surgeries like orbital floor reconstruction, paranasal augmentation, temporomandibular joint ankylosis, etc<sup>12,13,14</sup>. Coronoid process is also being used as a non metric skull variant in assessment of age, sex, race and species<sup>8</sup>. The clinical and other applications of coronoid morphology are in the field of reconstructive surgery and anthropology has been well documented in literature<sup>9</sup>. However except for a few paper presentations no detailed account about coronoid morphology has been cited so far. The present study was under taken to assess the different forms of the coronoid process existing in Indian adult population on both sides and to assess the feasibility of using this knowledge of coronoid morphology in identification of sex.

## MATERIAL AND METHODS

The mandibles were collected from departments of Anatomy of various medical colleges. Fifty male and fifty female mandible were retrieved during routine cadaver dissection, and assessed regarding the shape and configuration of coronoid process. Mandibles of adult age group were included in the study. The mandibles in which the coronoid process was damaged were excluded from the study. The various presentations of coronoid process was considered and classified as follows:

**Triangular:** Pointed apex, straight anterior and posterior border, notch absent (Figure 1).

**Hook shaped:** Pointed apex, Anterior border being convex, posterior border being concave, with presence of notch (Figure 2).

**Rounded:** Blunt apex, straight anterior and posterior border, notch absent (Figure 3).

**Miscellaneous variety:** Mandibles which did not fit into any of the above findings (Figure 4).

Hook shaped mandibles showed much variation and they were sub categorized as

a) Broad or narrow at the base (Figure 6)

b) Proximity of notch to apex (Figure 5)

The collected samples were analyzed regarding their shape and configuration which were later compared with various studies for their statistical significance using Chi-square test.

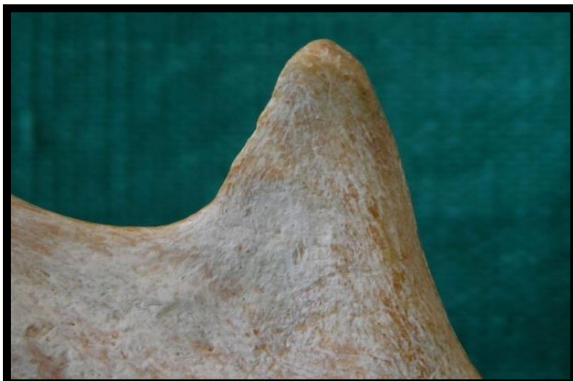

Fig. 1: Triangular coronoid process

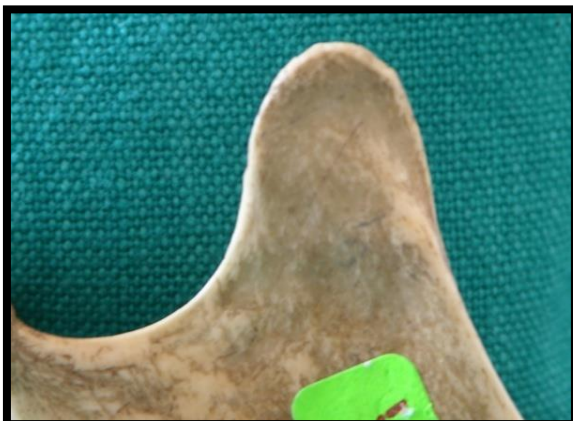


Fig. 2: Rounded coronoid process

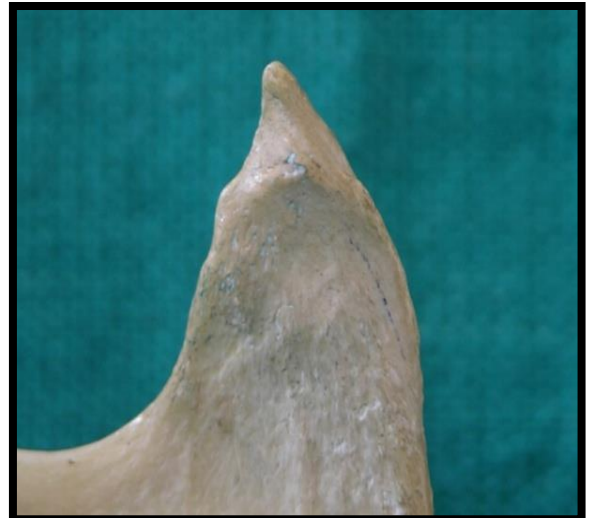

Fig. 3: Hook shaped coronoid process

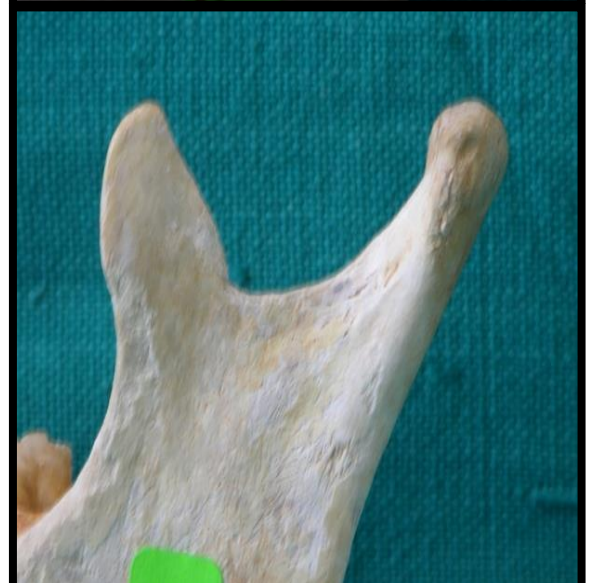
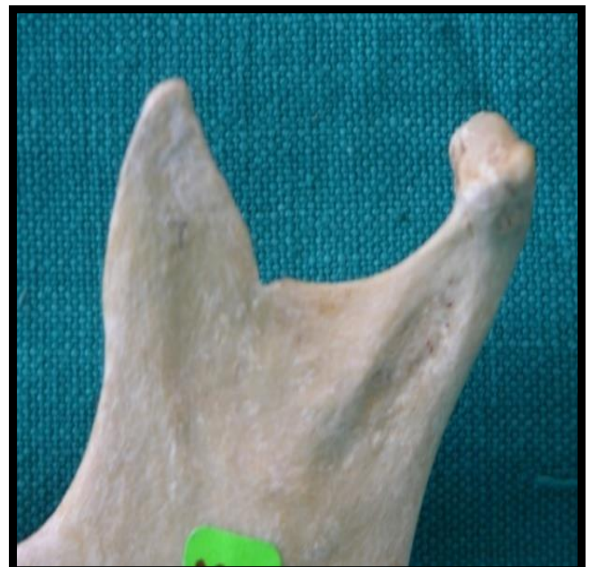
Fig. 4: Miscellaneous coronoid processes

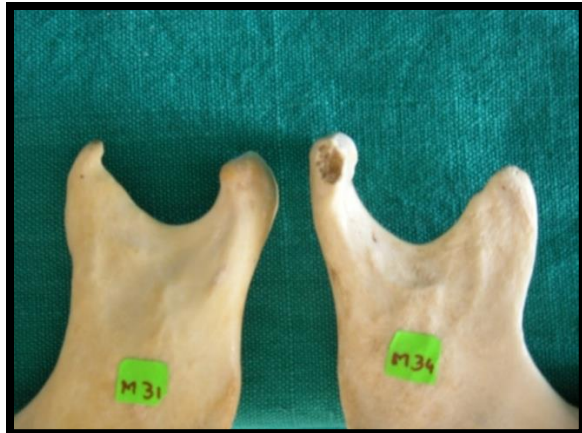

Fig. 5: Hook shaped coronoid process subvarieties based on notch

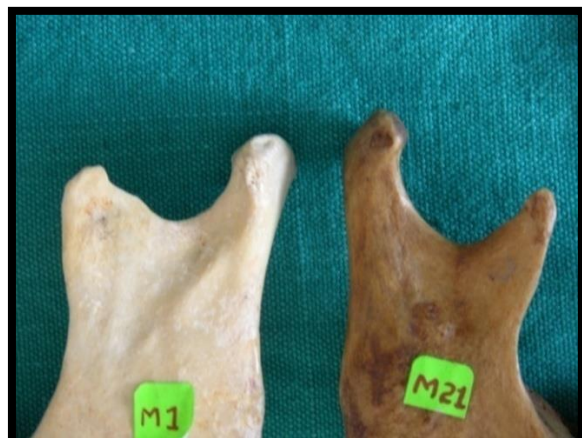

Fig. 6: Hook shaped coronoid process sub varieties based on base breadth

**RESULTS**

From the present study it was noted that hook shaped coronoid process predominated with 61.5% followed by triangular (14%) and rounded forms (12.5%) (Table-3). About 12% came under the miscellaneous category, out of which, 4% had close resemblance to hook, triangle and rounded variety each. 70% of the mandibles showed similar shape on both sides, while in 30% there was a difference in the shape on right and left side of mandible. Amongst symmetrical mandibles majority of them belonged to hook type. In males hook shape was seen predominantly with 52%, followed by triangular form in 18%, rounded form in 17% and miscellaneous form noted in 13% (Table 4). Hook shaped coronoid process also predominantly seen in females with 71%, followed by triangle form in 10% and round form in 8% (Table 4). Hook shape form in males had 57.7% broad base and 69.23% the notch was situated close to the apex. In females, 57.75% had narrow base and 60.56% showed notch close to apex. From the present study, hook shape was seen predominantly in females (Table-1) compared with males. Based on this fact it can be deduced that mandibles with hook shape could be of female gender. Moreover when side was considered, significant number of female mandibles showed hook shape coronoid process on the left side (Table -2).

**Table 1: Analysis of different shapes in male and female mandibles**

Shape	Males (n=100)	Females (n=100)	Z	P-value
Hook	52	71	-2.76	0.006
Triangular	18	10	1.63	0.103
Rounded	17	8	1.92	0.054
Miscellaneous	13	11	0.44	0.663

**Table 2: Distribution of shapes of coronoid process**

Right side:

Shape	Gender				Total	Chi-Square	P-value
	Males		Females				
	Nos.	% age	Nos.	% age			
Hook shaped	27	54	34	68	61	2.764	4.429
Triangular	7	14	7	14	14		
Rounded	9	18	5	10	14		
Miscellaneous	7	14	4	8	11		
<b>Total</b>	<b>50</b>	<b>100</b>	<b>50</b>	<b>100</b>	<b>100</b>		

Left side:

Shape	Gender				Total	Chi-Square	P-value
	Males		Females				
	Nos.	%age	Nos.	% age			
Hook shaped	25	50	37	74	62	9.244	0.026
Triangular	11	22	3	6	14		
Rounded	8	16	3	6	11		
Miscellaneous	6	12	7	14	13		
<b>Total</b>	<b>50</b>	<b>100</b>	<b>50</b>	<b>100</b>	<b>100</b>		

Table 3: Comparison of occurrence of different forms of coronoid process in different studies

	Isaac	Prashanthi Total/adult	P. Ranganath (bilateral)	Present
Hook	27.4%	11.3/7.9%	53.7%	61.5%
Triangular	49%	47.2/54.3%	23.4%	14%
Rounded	23.6	27.4/26.6%	22.8%	12.5%
Miscellaneous	–	13.2/11.2%	–	12%

Table 4: Comparison of occurrence of different forms of coronoid process in males and females from different studies

	Males		Females	
	Isaac study	Present Study	Isaac study	Present study
Hook	30%	52%	22.8%	71%
Triangular	46.5%	18%	53.5%	10%
Rounded	23.5%	17%	23.7%	8%
Miscellaneous	-	13%	-	11%

**DISCUSSION**

The much variation in the coronoid process morphology noted in the present study can be attributed to the variation in socio demographic profile of the individuals which has a direct or indirect affect on the size of the temporalis muscle altering the morphology of the coronoid process<sup>15, 16</sup>. Present study suggests, occurrence of hook shaped coronoid process was significantly higher in females and may aid in determination of sex of an individual. However when other forms of coronoid process are present sex cannot be accurately predicted based on coronoid process morphology alone. The present study coincides with a study done at StJohn’s Medical college in the occurrence pattern where they have done a study on 154 mandibles and found that the shape of the coronoid process was bilaterally triangular in 16.2%, hook-shaped in 45.5%, rounded in 18.2% rounded and hook-shaped in 4.5%, and unilaterally triangular in 12.3%, hook-shaped in 11.7%, and rounded in 7.1% of the mandibles<sup>11</sup>. However they have not considered the characteristics of the coronoid process with the sex. Contrary to our study, a study done by Isaac and Prashanthi showed majority of the coronoid process being triangular in shape (Table-3)<sup>9,10</sup>. Even though the studies considered for comparison with our study were done in India, there was marked variation in conclusion as the dietary habits and the genetic factor varied from region to region. Diet as we know has a vital role in

affecting the muscular pull on the bony process and as such can alter the shape of coronoid process markedly. Occupation and hormonal effect also has its effect (e.g. basket makers, who often use their mouth for weaving, tend to have a bigger coronoid process due to functional over activity of the temporalis). The sample type chosen in different studies could be another reason for the varied results. The inclusion of the miscellaneous category in the present study is another possibility for altered results. However such an inclusion was essential to segregate those mandibles with indistinct features which would otherwise increase the percentage of observer bias. In the present study such grouping and repeated reconfirmation of results has minimized the observation bias to a large extent.

**CONCLUSION**

Thus from the present study it can be said that coronoid process exists in many morphological shapes. The socio demographic factors either directly or indirectly affect the final appearance of the coronoid process morphology. The present study concludes that coronoid process with other non metrical variants can be used to asses gender of a person. It can thus be used as an identification marker thereby benefiting forensic experts. Thus the coronoid process, though an ignored territory of the mandible acts as a vital information centre. A larger sample could be studied to interpret the actual

occurrence of the rarer forms like double coronoid process, subcoronoid sutures etc. which were not encountered in the present study as sample size was limited.

## REFERENCES

1. Susan Stranding ed. Gray's Anatomy: The Anatomical basis of clinical practice 40<sup>th</sup> Ed. Churchill Livingstone, Elsevier; 2008, 530-533.
2. Breathnach A.S., ed. Frazer's Anatomy of the Human Skeleton, 6<sup>th</sup> Ed. London: J & A Churchill; 1965, 228-235.
3. Schafer E. A. and Thane G.D.; Elements of anatomy, In: The bones of the head, 10<sup>th</sup> Ed. London: Longmans, green & Co.; 1890, 60.
4. Johannes Lang, ed. Clinical Anatomy of Masticatory Apparatus and peripharyngeal spaces, illustrated Ed. New York: Thieme pub; 1995, 19-37.
5. Hamilton W.J.; Textbook of Human Anatomy in: Locomotor system, 2<sup>nd</sup> Ed. London: Macmillan; 1976, 80.
6. Basmajian J. V. and Slonecker C. E. ; Grant's Method of anatomy in: Side of skull, temporal and infratemporal regions. 11<sup>th</sup> Ed. London: Williams & Wilkins, Baltimore; 1989, 516.
7. Kansu. H., O. Kansu, F. Akgunlu. ; Bifid coronoid process. Oral surgery, Oral Medicine, Oral Pathology, 1994; 78(2): 136.
8. Rak Y., Ginsbing A., Geffen E. Gorilla like anatomy of Australopithecus aferensis mandible. Proc. Nat. Acad. Sci. U. S. A., April 2007; 104(16): 6568-6572.
9. Isaac B. and Holla S. J. Variations in the shape of coronoid process in the adult human mandible. Journal of Anatomical Society of India 2001; 50(2): 137-139.
10. Prashanthi N., Narayana K., and Nayak S. R.; Morphology of lingula, coronoid process and the mandibular notch in Indian dry mandibles. Folia Anatomica, Belgrade 2004; 31(1): 13-16.
11. Ranganath, P., Manjunath K.Y., Balasubramanya. ; The varying shape of coronoid process of the mandible. Indian Journal of Dental Research, 2004; 15(3): 96-98.
12. Mintz S. M., Ettinger A Schmakel T and Gleason M. J.; Contralateral coronoid process bone grafts for orbital floor reconstruction- an anatomic study and clinical study. Journal of Oral and Maxillofacial Surgery, 1998; 56(10): 1140-1144.
13. Choung P., Kim S.; The coronoid process for paranasal augmentation in the correction of midfacial concavity. Oral Medicine, Oral Pathology, Oral Radiology, Endod. 2001; 91: 28-33.
14. Egito Vasconcel B.C., Gabriel Granja Porto, Ricardo Viana, Bessa Nogvelira; Tempero mandibular joint ankylosis. Revista Brasileira Otorrinolaringologia, Feb. 2008; 74(1): 34-38.
15. Avis. V; The relation of the temporal muscle to the form of coronoid process. American Journal of Physical Anthropology, 1959; 17: 99-104.
16. Meopi N Syropoulos; The morphogenetic relationship of the temporalis muscle to the coronoid process in human embryos and fetuses. American Journal of Anatomy, April 1977; 150:395-410.