

## Histometric study of the mean epidermal thickness from different regions of skin of human fetuses of 11-40 weeks of gestational age

Shivani Dhingra<sup>1\*</sup>, Adil Asghar<sup>2</sup>

<sup>1</sup>Post Graduate Student, <sup>2</sup>Associate Professor, <sup>1</sup>Uttar Pradesh University of Medical Sciences, Saifai, Uttar Pradesh, <sup>2</sup>All India Institute of Medical Sciences, Patna, Bihar, India

\*Corresponding Author: Shivani Dhingra

Email: cherrycd185@gmail.com

Received: 12<sup>th</sup> September, 2018

Accepted: 19<sup>th</sup> January, 2019

### Abstract

**Introduction:** Skin is the largest organ in the body. It forms the pigmented and protective external covering of the body and plays an important role in regulating body temperature. Learning its development is important for us for determining the gestational age of a fetus. The aim of this study is to measure the mean epidermal thickness from different regions of the body in fetuses ranging from 11-40 weeks of gestation.

**Materials and Methods:** Measurement of epidermal thickness from abdominal, interscapular, scalp and palmar regions in 30 human fetuses of 11-40 weeks which were divided into 6 groups was done using Amscope 5MP Aptina MT9P001.

**Results:** The mean epidermal thickness for abdominal skin was  $5.04 \pm 0.97 \mu\text{m}$  for Group 1 (11-15 weeks) which increased to  $38.48 \pm 2.62 \mu\text{m}$  in Group 6. Similarly, the mean epidermal thickness increased in interscapular, scalp and palmar regions but there was a difference in increase in the pattern of mean epidermal thickness in different regions. The thickness of abdominal epidermis was not similar to the thickness of interscapular, scalp and palmar skin in the same age group.

Statistical tests used: T-Test and single factor ANOVA. P-value was calculated.

**Conclusion:** Our study concluded that the epidermal thickness varied according to the different regions of the body. But surely there was an increase in mean epidermal thickness from Group 1 to Group 6 in all the regions of the skin.

**Keywords:** Skin, Mean epidermal thickness, Calibration.

### Introduction

Skin has dual origin- the epidermis that develops from surface ectoderm and the dermis that develops from underlying mesenchyme. During 4<sup>th</sup>-6<sup>th</sup> week of gestation, during the process of neuralation under the influence of notochord differentiation of ectoderm into surface ectoderm and neural ectoderm takes place. The further development of epidermis takes place from the surface ectoderm. By 6<sup>th</sup> week of gestation, fetal skin can be visualized as two distinct layers with a basal epidermal layer covered by an outer layer, termed the periderm. The periderm is uniquely found in humans without an analog in animal models, such as mice or rats.<sup>1</sup> In next 4-5 weeks, stratification becomes apparent in different layers.<sup>2</sup> Keratinization begins around ninth weeks of gestation. By 12-16 weeks there are one or more intermediate layers. From 16 and 26 weeks, there is a sudden increase in the intermediate layers, and from 21 weeks keratohyalin granules begin to appear in the superficial layers. By 24 weeks the periderm cells start to separate from the embryo. Together with shed lanugo, sebum and other materials, it forms the vernix caseosa.<sup>3</sup>

### Aim and Objective

The aim of our study is to identify the sequential changes in development of epidermis of human fetal skin in fetuses of 11-40 weeks of gestation divided into 6 groups and the objective is to compare the growth pattern by mean thickness of epidermis in 11-40 weeks of gestation of fetuses divided into 6 groups in skin samples from different

regions of abdominal, interscapular, palm and scalp in human fetuses.

### Materials and Methods

It is an observational study conducted on 30 (Stillborn/Intra uterine died/ Medically Terminated Pregnancy) human fetuses ranging from 11-40 weeks of gestational age without any gross anomaly that were collected from department of Obstetrics and Gynaecology, U.P.U.M.S., Saifai, from the period of January 2017 to June 2018. The study was conducted after approval from ethical committee of the institute (E.C. No. 2017/131) and after obtaining written informed consent from the mothers. Fetuses were well preserved in jars containing 10% formalin solution in the department of Anatomy, U.P.U.M.S., Saifai. Skin from all the fetuses was procured from abdominal region, interscapular region, palm region and scalp regions after calculating the age with help of crown-rump length, biparietal diameter and femur length in addition to menstrual history of the mother. The size of tissue taken was roughly 5 mm\* 5 mm. Skin sample was processed by paraffin embedding method. Inclusion criteria for our study were age of fetus corresponding with the menstrual history of the mother and mother having no serious/chronic medical illness. The exclusion criteria included small for date foetus, pre term foetus, macerated foetus and foetus with any visible/gross congenital anomaly. The histological process involved were fixation, dehydration, clearing, and wax impregnation, section cutting and staining with H & E stains. The stained section was mounted with DPX then

covered with cover slip and then the slide was examined under light microscope.

### Measurement

All the measurements of the slides examined were done by using Amscope 5MP Aptina MT9P001. Thickness of epidermis was taken from uppermost layer upto the dermo epidermal junction. The measurements were done three times by two observer each time.

### Statistical Analysis

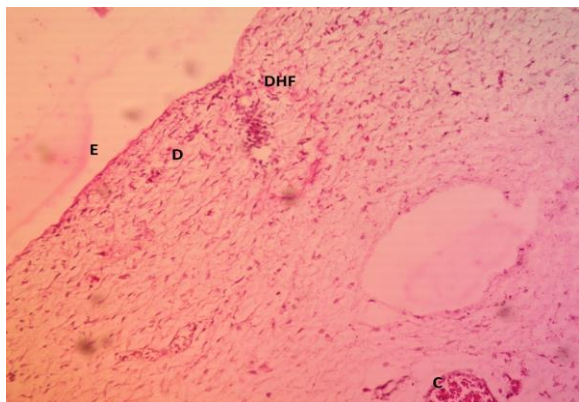
Statistical analysis was done by using SSPS v22.0 and MS Excel 2007. ANOVA and T-test were applied accordingly. P- value was calculated for each group.

For the study, we categorized the fetuses in 6 groups according to their age. (Table 1)

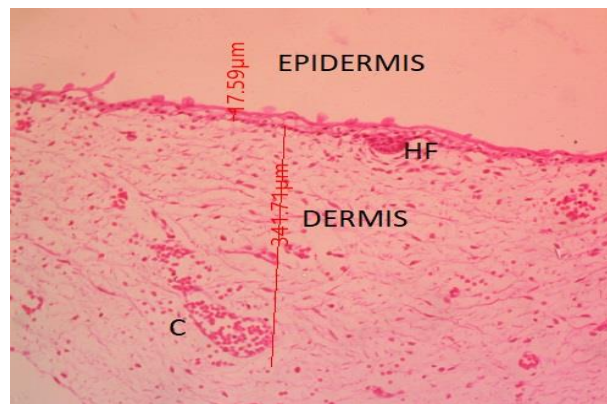
### Results and Observation

On histology, in Group 1(11-15 weeks of gestation) the epidermis was found to be thin and only two layered thick in all the regions (abdomen, interscapular, scalp and palm) with no hair follicle present, no capillary was seen. Group 2 (16-20 weeks) fetus started showing multilayered epidermis in all the regions with developing capillaries appreciable and developing hair follicles (except in palmar skin) were seen per high power field (Fig. 1). And further in all the groups upto Group 6 the epidermal layer increased in size with proper hair follicle (except in palm skin) appreciable along with sebaceous glands and fully developed capillaries were seen per high power field.

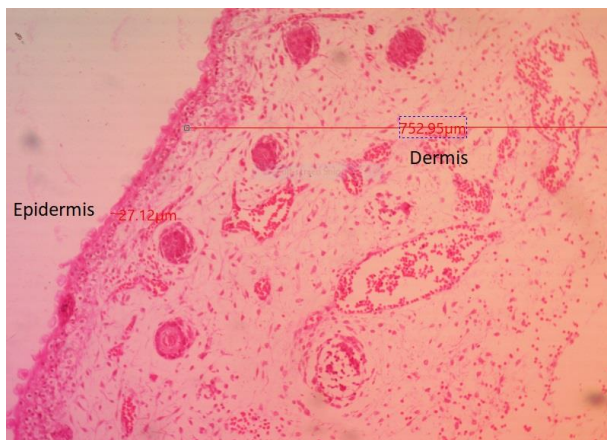On histometric evaluation, we calculated the mean epidermal thickness in all the fetuses in the 6 groups from different regions of fetus- abdominal, interscapular, scalp and palm. The mean abdominal epidermal thickness ( $\mu\text{m}$ ) calculated in 6 groups (Table 2) (Fig. 2) and were found to be increasing from group 1 to group 6. Similarly the mean interscapular epidermal thickness (TABLE 3), mean scalp epidermal thickness (Table 4) (Fig. 3) (Fig. 4) and mean palm epidermal thickness (Table 5) (Fig. 5) all in  $\mu\text{m}$  along with standard deviation were calculated and the thickness of epidermis increased from group 1 to group 6 in all of the regions.



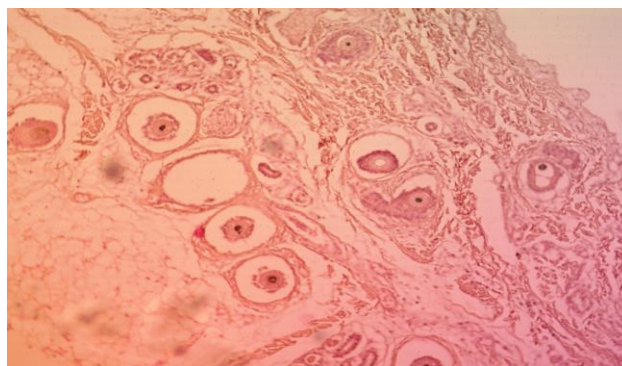
**Fig. 1:** Skin of abdomen (10X) showing developing hair follicle (DHF) at 15 week of gestation on H & E Stain



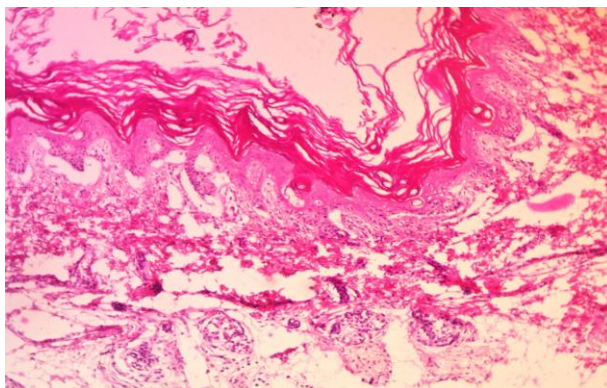
**Fig. 2:** Abdominal skin at 25 weeks of gestation showing Epidermal Thickness ( $\mu\text{m}$ ) at 10x (H & E stain) along with developing hair follicle (HF) and developing capillary (C)



**Fig. 3:** Scalp skin at 25 weeks of gestation showing Epidermal Thickness ( $\mu\text{m}$ ) at 10x (H & E stain) along with hair follicle (HF) and Capillary (C) and Sebaceous Gland (S)



**Fig. 4:** Scalp skin at 33 weeks of gestation at 10x (H & E stain)



**Fig. 5:** Palm skin at 33 weeks of gestation at 10x (H & E stain)

**Table 1:** Categorization of fetuses into 6 groups according to their age

Group	Age of fetus (weeks)
Group 1	11-15
Group 2	16-20
Group 3	21-25
Group 4	26-30
Group 5	31-35
Group 6	36-40

**Table 2:** The mean abdominal epidermal thickness ( $\mu\text{m}$ ) in 6 groups

Groups	No. of fetus studied	Mean Abdominal epidermal thickness ( $\mu\text{m}$ )	Standard Deviation	p- value
Group 1	5	5.04	0.97	0.0001
Group 2	5	7.6	0.81	0.0001
Group 3	5	19.02	4.19	0.0001
Group 4	5	27.82	2.03	0.0001
Group 5	5	33.44	1.32	0.0001
Group 6	5	38.48	2.62	0.0001

**Table 3:** The mean Interscapular epidermal thickness ( $\mu\text{m}$ ) in 6 groups

Groups	No. of fetus studied	Mean Interscapular epidermal thickness ( $\mu\text{m}$ )	Standard Deviation	p- value
Group 1	5	9.74	1.14	0.0001
Group 2	5	11.46	0.27	0.0001
Group 3	5	149.92	9.55	0.0001
Group 4	5	147.1	6.18	0.0001
Group 5	5	160.94	14.34	0.0001
Group 6	5	188.08	22.82	0.0001

**Table 4:** The mean Scalp epidermal thickness ( $\mu\text{m}$ ) in 6 groups

Groups	No. of fetus studied	Mean Scalp epidermal thickness ( $\mu\text{m}$ )	Standard Deviation	p- value
Group 1	5	12.8	0.71	0.0001
Group 2	5	14.52	0.79	0.0001
Group 3	5	20.76	4.61	0.0001
Group 4	5	28.76	1.56	0.0001
Group 5	5	43.26	0.77	0.0001
Group 6	5	45.36	0.64	0.0001

**Table 5:** The mean Palm epidermal thickness ( $\mu\text{m}$ ) in 6 groups

Groups	No. of fetus studied	Mean Palm epidermal thickness ( $\mu\text{m}$ )	Standard Deviation	p- value
Group 1	5	9.9	1.67	0.0001
Group 2	5	15.02	1.58	0.0001
Group 3	5	160.88	4.33	0.0001
Group 4	5	177.2	9.37	0.0001
Group 5	5	206.96	16.66	0.0001
Group 6	5	268.44	11.12	0.0001

## Discussion

Fetal skin develops primarily to protect the infant from water loss and from any foreign body invasion it also provides immunity, sensations and temperature regulation immediately after the birth. These functions are mainly performed by the three important layers, the superficial most layer stratum corneum, the epidermis and dermis, and specialized cells found within them.

**K. B. L. Verma, H. C. Varma and S. S. Dayal (1976)** took pieces of skin 0.5-1 -0 cm<sup>2</sup> in area from between the scapulae, the umbilical region, the angle of mouth, palm and sole. Specimens were studied in 5 groups. Maximum numbers of layers were appreciated in fetuses of Group 4 (119-140 days) i.e 30 -35 weeks of gestation. In our study we observed the mean epidermal thickness among Group 6 (35-40 weeks) fetus was maximum that too in the palm skin. So, this specified the study more that the mean epidermal thickness was maximum is palmar region amongst the other regions (abdominal, interscapular and scalp) even in the same age group.

**Jorg Ersch and Thomas Stallmach (1999)** conducted a study on 379 human fetuses from 12–30 weeks of gestational age, skin samples were dissected from abdomen below the umbilicus. They appreciated from 13 weeks onwards, an intermediate layer appears and fetal skin becomes stratified, but no appendages are seen. The maturation of fetal skin varies by site. This is why the development of skin from neck region would be 1–2 weeks ahead of actual gestational age and 2 weeks behind on examining the thigh skin. This explains the overall development of mammalian embryos, which begins from the head pole and continues upto the caudal pole. Similarly in our study we found that the maturation of epidermal thickness is varying by the site of the fetal skin sample taken.

**Rehman F and Nasir N (2017)** with their study showed that the differentiation of epidermis begins from the end of the second month. Upto 9 weeks of gestation the embryo is covered with a single layer of epidermal cells. From 9<sup>th</sup> week onwards upto 13<sup>th</sup> week, two-layered skin is appreciated with a second superficial layer called periderm. In the similar manner we found from our study that in Group 1 (11-15 weeks of gestation) the mean epidermal thickness was the least amongst the other groups. It was measured to be  $5.04 \pm 0.97 \mu\text{m}$  in abdomen,  $9.74 \pm 1.14 \mu\text{m}$  in interscapular region,  $12.8 \pm 0.71 \mu\text{m}$  in scalp and  $9.9 \pm 1.67 \mu\text{m}$  in palm because the epidermis in this age group is only a

two layered structure and with further development of layers the thickness increases in the following age groups and it is seen in our study that the mean epidermal thickness increased as we moved from Group 1 to Group 6.

## Conclusion

Human skin consists of an outer epidermis and an underlying dermis of connective tissue. Starting from 10th weeks and continuing until 30th weeks, the development of skin and its appendages is a sequence of easily recognizable histological patterns within the skin of the fetus. Identification of these age-related morphometric patterns allows assessing the fetal age and offers background information for detecting congenital skin diseases. Detection of congenital skin diseases is possible only with exact knowledge of normal histology. In postmortem examination the clinician usually gives gestational age of a fetus. Due to inaccuracy of the age given in cases of severe growth retardation or organ hypoplasia assessing the gestational age from histology of fetal skin and along with its thickness measurement is done. This data provides relevance to prenatal diagnosis of inherited skin disease. From amniocentesis and/or fetal biopsy specimens; the present study of fetal epidermal surface will allow one to predict the types of skin-derived cells that should be present in the amniotic fluid at a given age, and to evaluate a fetal biopsy from skin and be confident that it is an accurate index of fetal skin development, age and status in general.

**Conflicts of Interest:** None.

## References

1. Satish L, Kathju S. Cellular and Molecular Characteristics of Scarless versus Fibrotic Wound Healing. *Dermatol Res Pract* 2010;790234:1-7.
2. Ersch J, Stallmach T. Assessing gestational age from histology of fetal skin: an autopsy study of 379 fetuses. *Obstet Gynecol* 1999;94:753–7.
3. Holbrook KA, Odland GF. The fine structure of developing human epidermis: light, scanning and transmission electron microscopy of the periderm. *J Invest Dermatol* 1975;65:16–38.
4. Verma KBL, Varma HC, Dayal SS. A histochemical study of human fetal skin. 1976;121:185-91.
5. Ersch J, Stallmach T. Assessing gestational age from histology of fetal skin: an autopsy study of 379 fetuses. *Obstet Gynecol* 1999;94:753–7.
6. Fazal UR Rehman, Nazim Nasir. Micro-morphometric study of skin in developing human fetuses and its clinical relevance. *Int J Anat Res* 2017;5(1):3496-3500.

7. Farah Ghaus, Nafis Ahmad Faruqi. Histogenetic and Histomorphometric Studies on Developing Skin of Human Foetuses. *Int J Med Res Prof* 2018;4(1):224-7.
8. Breathnach AS. Embryology of human skin. A review of ultrastructural studies. The Herman Beerman Lecture. *J Invest Dermatol* 1971;57:133-4.
9. Holbrook KA. Structure and function of the developing human skin. In: Goldsmith LA, ed. *Biochemistry and Physiology of the Skin*. New York: Oxford University Press, 1983:64–101.
10. Holbrook KA, Hoff MS. Structure of the developing human embryo and fetal skin. *Semin Dermatol* 1984;3:185–202.
11. Hoyes AD. Electron microscopy of the surface layer (periderm) of human foetal skin. *J Anat* 1968;103 (Pt 2):321-6.
12. McGrath JA, Eady RAJ and Pope FM. Anatomy and Organization of human skin In Burns T, Breathnach S, Cox N and Griffiths C (eds) *Rook's Textbook of Dermatology*. Blackwell Science Ltd Oxford, Oxford 2004;3.1-3.
13. Hoath, SB. Physiologic development of the skin. In: RA, P.; Fox, W.; Abman, S., editors. *Fetal and Neonatal Physiology*. Elsevier; Philadelphia, PA: 2004.
14. Yosipovitch G, Maayan-Metzger A, Merlob P. Skin barrier properties in different body areas in neonates. *Pediatrics* 2000;106:105–8.
15. Breathnach, A. S. &Wyllie, L. M. Fine structure of the cells forming the surface layer of epidermis in human fetuses at fourteen and twelve weeks. *J Invest Dermatol* 1965;45(3):179-89.
16. Marty Visscher and Vivek Narendran, Neonatal Infant Skin: Development, Structure and Function, *Newborn and Infant Nursing Reviews* 2014;14:4.

**How to cite this article:** Dhingra S, Asghar A. Histometric study of the mean epidermal thickness from different regions of skin of human fetuses of 11-40 weeks of gestational age. *Indian J Clin Anat Physiol* 2019;6(2):247-51.