

Cadaveric incidence of renal artery variations at SRTR Govt. Medical College Ambajogai

Nilima Patil¹, S. S. Dhapate^{2,*}

¹Associate Professor, ²Professor and HOD, Dept. of Anatomy, ¹Shri Vasantrao Naik Government Medical Hospital, Yavatmal, Maharashtra, ²Swami Ramanand Tirth Rural Government Medical College, Ambajogai, Maharashtra, India

*Corresponding Author: S. S. Dhapate

Email: drdhapatess@gmail.com

Received: 31st July, 2018

Accepted: 20th November, 2018

Abstract

Introduction: Vascular anomalies related to the renal arteries are not uncommon. The literature indicates that multiple renal arteries are found in 9-76% of cadavers. Two groups of renal artery variations are considered, the early division (ED) and extra renal arteries (ERA). Surgeons operating on the kidney must be acquainted with normal and abnormal anatomy of the renal vessels to avoid inadvertent injury. Aim of this study was to establish the prevalence of cadaveric renal artery variations with the Objective to bring awareness to the surgeons and radiologists performing vascular surgeries and invasive procedures respectively.

Materials and Methods: This is a descriptive observational study wherein dissected cadavers were observed for the presence of renal arterial variations. The study was conducted in the department of anatomy, SRTRGMC, Ambajogai, Maharashtra over a period of 2012-2017 and total of 30 cadavers that is total 60 kidneys were observed for the presence of various renal arterial variations during routine abdominal dissection conducted for medical undergraduates.

Result: In this present study the incidence of various renal artery variations taken together amongst all cadaveric kidneys observed was 36.66%. Incidence of ERA was 20% and Incidence of ED was 16.66%.

Keywords: Renal artery variations, Extra renal artery, Early division, Ladder pattern, Fork pattern.

Introduction

Renal vasculature can be studied at various levels commencing with the Principal and accessory renal arteries. Their primary pattern of branching and areas of distribution suggest the presence of vascular segmentation.¹ Usually one renal artery arises from the anterolateral or lateral aspect of abdominal aorta just below the origin of Superior mesenteric artery (SMA) and enters the kidney through hilum. Developmentally renal arteries arise from most caudal lateral splanchnic arteries on each side. During ascent of the kidney to their final position in the posterior abdominal wall the embryonic kidney receives their blood supply and venous drainage from successively more superior vessels. Usually the inferior vessels degenerate and the superior ones take over the blood supply.² Vascular anomalies related to the renal arteries are not uncommon. The literature indicates that multiple renal arteries are found in 9-76% of cadavers³ Knowledge of variations of renal vascular anomalies has importance in exploration and treatment of renal trauma, renal transplantation, renovascular hypertension, renal artery embolization, angiography and renal vascular reconstruction for congenital and acquired lesions, surgery for abdominal aortic aneurysm and conservative or radical renal surgery.⁴ Two groups of renal artery variations are considered, early division (ED) and Extra renal arteries (ERA). ERA are further divided into hilar and polar renal arteries. Hilar arteries are the accessory renal arteries whereas the arteries entering the poles of the kidney are considered aberrant renal arteries.⁵ Shoja et al classified perihilar branching of renal artery as Ladder and fork patterns. The pattern where there were sequential branching points was termed as the

ladder pattern. The pattern with a common branching point was termed as fork pattern.⁶

Surgeons operating on the kidney must be acquainted with normal and abnormal anatomy of the renal vessel to avoid inadvertent injury. It is also important for the radiologists to be aware of such renal vasculature anomalies especially while performing renal angiography.

The aim of this study was to study the incidence of cadaveric renal artery variations with the objective to bring awareness to the surgeons and radiologists performing vascular surgeries and invasive procedures respectively.

Materials and Methods

This is a descriptive observational study in which dissected cadavers were observed for the presence of renal arterial variations. The study was conducted in the department of anatomy, SRTRGMC, Ambajogai, Maharashtra over a period of 5 years, 2012-2017 and total 30 cadavers that is total 60 kidneys were observed for the presence of various renal arterial variations during routine abdominal dissection conducted for medical undergraduates.

Kidneys were observed for variations in arterial patterns. Renal arterial patterns were grouped into two groups that is ERA and ED. ERA is again grouped into accessory and aberrant renal artery. ED was grouped in to ladder pattern and fork pattern. These various arterial patterns were identified, photographed and described to study the incidence of each variation. As all these above mentioned variations can occur unilaterally or bilaterally as well as in combination with each other so the incidence was calculated according to the number of kidneys observed that is in this study total 30 cadavers were observed sointotal 60 kidneys were observed.

Observations and Result

It was observed that out of 30 cadavers, 12 cadavers showed presence of renal artery variations unilaterally or bilaterally as well as multiple variations in combination with each other. Out of these 12 cadavers 8 cadavers were with extra renal arteries (ERA) and 7 cadavers with early division(ED) of renal arteries in isolation or in combination on one or both the sides.

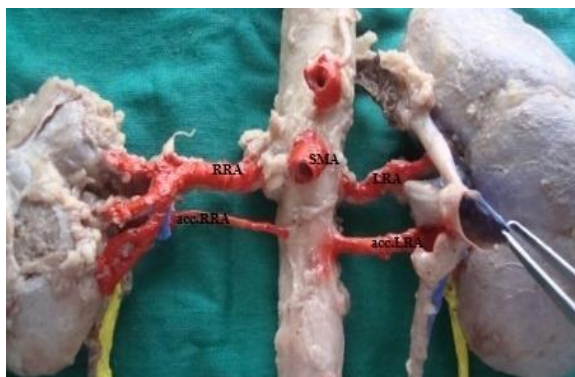


Fig. 1: The cadaver with accessory renal arteries bilaterally showed origin of accessory arteries from the anterolateral aspect of aorta 1.5cm below the level of origin of (SMA) superior mesenteric artery. (RRA)Right main renal artery in addition showed early division into segmental arteries in ladder pattern

Out of these 8 cadavers with ERA, 4 cadavers were with bilateral ERA and 4 cadavers with unilateral ERA.

Table 2: Showing incidence of ERA amongst total cadaveric kidneys observed (60)

Type of variation	No. of kidneys showing the variation	% of variation
Extra renal arteries	12	20%
a. Accessoryrenal arteries	10	16.66%
b.Aberrant renal artery	2	3.33%

Seven cadavers showed early division of renal arteries on one or other side with bilateral early division in three cadavers distributed as ladder pattern in two cadavers and one cadaver with fork pattern in left renal artery and ladder pattern in right renal artery. Remaining four out of seven

Table 1: Showing incidence of bilateral and unilateral ERA amongst the total cadavers observed:

	No. of cadavers	Incidence
Unilateral ERA	4	13.33%
Bilateral ERA	4	13.33%

So in total 12 kidneys out of 60 kidneys observed show presence of extra renal artery (20%) out of these 4 unilateral ERA 2 were with unilateral accessory renal artery and 2 with unilateral aberrant renal artery to superior pole of the right kidney.

cadavers showed unilateral early division of renal arteries distributed as Ladder pattern in 2 and Fork pattern in 2. In total 10 kidneys out of observed 60 kidneys showed occurrence of early division of renal arteries. (16.66%)

Table 3: Showing incidence of ED amongst total cadaveric kidneys observed (60)

Type of variation	No. of kidneys showing the variation	% of variation
Early division of renal arteries.	10	16.66%
Ladder type early division	7	11.66%
Fork pattern early division	3	5%

Table 4: Distribution of ERA and ED amongst total cadaveric kidneys

Total no of Kidneys observed	60	100%
Number of kidneys with ERA	12	20%
Number of kidneys with ED	10	16.66%
Total Kidneys with various renal artery variations	22	36.66%

Discussion

Kidneys develop in three stages that are pronephros, mesonephros and metanephros. During this process kidneys

ascend from pelvic cavity to the lumbar region. When the kidneys are situated in the pelvic region they are supplied by the branches of common iliac arteries while the kidneys ascend to lumbar region, their arterial supply also shifts from common iliac to abdominal aorta.⁷

Different origins of renal arteries and frequent variations are explained by the development of mesonephric arteries. These arteries form a vascular net feeding the kidneys, suprarenal glands and gonads on both sides of aorta between cervical 6th and 3rd lumbar vertebrae a region known as retearteriosumurogenitale. Over time these arteries degenerate leaving only the mesonephric artery which undertake arterial circulation of the kidneys, deficiency in the development of mesonephric arteries results in more than one renal arteries.^{8,9}

Various chemical agents, growth factors and haemodynamic forces may all take part in the selection and persistence of a particular congenital vascular channel. Embryonic signals that result in the formation of an accessory renal artery is yet unknown.¹⁰

The surgeons operating on the kidney must be acquainted with the normal and abnormal anatomy of the renal vessels to avoid inadvertent injury to the kidney so this study was aimed to find out the incidence of renal artery variations in cadaveric specimens.

Two groups of renal artery variations were considered, the early division (ED) and Extra renal arteries (ERA). ERA are further divided into hilar and polar renal arteries. Hilar arteries are the accessory renal arteries whereas the arteries entering the poles of the kidney are considered aberrant or polar renal arteries.⁵

The ERA shows dissimilarities according to society, ethnicity and race. Satyapal et al stated that the frequency of ERA is between 9-76%.¹¹ In the present study the incidence of ERA was 20%. The present study result of accessory renal artery incidence was nearer to the results of Saldarriaga et al¹² Gupta et al 28.33%¹³ Ozkan et al 24%.⁵ However lower than that described by Pamieri et al 61.5%¹⁴ Eisendrath et al 45%¹⁵ Rupert et al 61%.¹⁶ The frequency rate of bilateral ERA is 12% in general population.¹⁷ In several anatomic and angiographic studies the rate of bilateral ERA was stated to be 10%-15%. In the present study the occurrence of unilateral as well as bilateral ERA was observed to be 13.33%.

In the present study the incidence of ED in cadaveric specimens was found to be 16.66% which is nearer with the study by Kadir et al stated that the rate of ED in general population is 15%.¹⁷

In the present study the ladder pattern of early division of renal artery was found to be 11.66% and that of fork pattern was 5%. In contrast to our study the fork pattern was more common than ladder pattern in a study by N Shakuntala Rao et al.¹⁸

From the above discussion it is clear that the rate of occurrence of various types of renal artery variations differs from region to region so there should be conduction of large group studies on the commonly occurring renal artery variations in that particular region.

Often abnormal branching pattern of the segmental arteries may result in erroneous interpretation of angiograms¹⁹ so it is also important for the radiologists to be aware of the renal artery variations.

Precise knowledge of the renal artery and its branching pattern is very useful for surgeons performing nephrectomies and renal transplantation. Transplantation of kidneys with one renal artery is technically easier than when there is more than one renal artery. Moreover in transplantation of kidneys with one renal artery postsurgical rates of complication and kidney loss are lower as compared to transplantation of kidney with more than one renal artery.^{20,21} Nevertheless to plan adequate surgical procedure and to avoid any vascular complications arteriography should be performed prior to nephrectomy.²³

Interestingly the incidence of donor kidney vasculature anomalies ranges from 18-30% and such kidneys are usually at increased risk of vascular and urological complications.²²

Conclusion

As the occurrence of renal artery variations are according to society, ethnicity and race, further studies are recommended with large study groups in relation with the society, ethnicity and race.

Conflict of Interest: None.

References

1. Gray Henry; Williams Petrer: Bannister, Lawrence H, Gray's Anatomy Edition 38th Churchill Livingstone page 1826.
2. Keith L Moore. Persaud. T.V.N. clinically oriented embryology 8th edition Saunders 2003.
3. Khamanarong K, Prachaney P, Utravichien A, Tongun T, Sripao Raya K. Anatomy of renal arterial supply. *Clin Anat* 2004;17:334-336.
4. Fernandes RMP, Conte FHP, Favorito La, Abidu-Figueiredo M, Babinski MA. Triple Right Renal Vein an uncommon variation. *Int J Morphol* 2005;23:231-233.
5. Ugur Ozakan, Levent Oguzkurt, Fahri Tercon, Osman Kizilkilic, Zafer Koc, Nihal Koca. Renal artery origins and variations: Angiographic evaluations of 855 consecutive patients. *Diagn Interv Radiol* 2006;12:183-186.
6. Mohammadi M Shoja R, Shane Tubbs, Abolhassan Shakeri, Marios Loukas, Mohammad R Ardalan, Hamid T, Khosroshahi W, Jerry Oakes. Peri-hilar branching patterns and morphologies of the renal artery, a review and anatomical study. *Surg Radiol Anat* 2008;30(5):375-382.
7. Nathan H. Aberrant renal artery producing developmental anomaly of kidney associated with unusual course of gonadal vessels. *J Urol* 1963;89:570-572.
8. Boijsen E, anomalies and malformations In: Baum S, ed Abraham's angiography, 4th Ed. Philadelphia: Little brown and company, 1997;1217-1229.
9. Felix W. die Entwicklung der harn- und Geschlechts Organe In: Keibel K, eds, Handbuch der Entwicklung, Geschichtes des Menschen Leipzig, Hirzel, 1911;732.
10. Pai MM, Vadgaonkar R, Rai R, Nayak SR, Jiji PJ. A Cadaveric Study of the testicular artery in the South Indian population. *Singapore Med J* 2008;49:551-555.
11. Satyapal KS, Haffejee AA, Singh B, Ramsaroop L, Robbs JV, Kalideen JM. Additional Renal Arteries: Incidence and morphometry. *Surg Radiol Anat* 2001;23:33-38.

12. Saldarriaga B, Perez AF, Ballesteros LE. A direct anatomical study of additional renal arteries in a Colombian Mestizo Population. *Folia Morphol* 2008;67(2):129-134.
13. Gupta A, Gupta R, Singhla RK. The accessory renal arteries: comparative study in vertebrates with its clinical implications. *J clinDiagn Res* 2011; 5:970-73
14. Palmieri BJ, Petroianu A, Silva LC, Andrade LM, Alberti LR. Study of arterial pattern of 200 renal pedicles through Angiotomography. *Revol Bras Cir* 2011;38:116-21.
15. Eisendrath DN. The relation of variations in the renal vessels to pyelotomy and Nephrectomy. *Am J Surg* 1920;71:726-743.
16. Rupert RR. Further study of irregular kidney vessels as found in one hundred eighteen cadavers. *Surg Gynae Obst* 1915;21:471-480.
17. Kadir S. Kidneys In: Kadir S, ed Atlas of normal and variant angiographic anatomy Philadelphia: WB Saunders Company, 1991:387-429.
18. N Shakuntala Rao, Krishna Kishore, Et al. Extra Hilar Branching of Renal Arteries: An Anatomical study. *Int J Anat Res* 2015;3(4):1568-1572.
19. Srijt Das. Anomalous renal arteries and its clinical implications. *Bratisl Lek Lisly* 2008;109(4)182-184.
20. Fox M, Yalin R. Renal Transplantation with multiple arteries. *Br J Urol* 1979;51:333-336.
21. Sanson JR, Hall CL. Barnes AD, Robinson BHB, Blainey JD. The significance of vascular anomalies in human renal transplantation. *Proceur Dial Transplant Assoc* 1978;15:345-351.
22. Gurses IA, Kale A, Gayretti O, Bayraktar B, Usta A, Kayaalp ME, Ari Z. Bilateral variation of renal and testicular arteries. *Int J Anat Var (IJAV)*. 2009;2:45-47.
23. De, Coppi P, Giuliani S, Fusaaro F, Zanatta C, Z Acc hello G, Gamba P, Zanon GF. Cadaver kidney transplantation and vascular anomalies: A paediatric experience. *Transplant* 2006;82(8):1042-1045.

How to cite this article: Patil N, Dhapate SS. Cadaveric incidence of renal artery variations at SRTR Govt. Medical College Ambajogai. *Indian J Clin Anat Physiol* 2019;6(1):49-52.