

Content available at: <https://www.ipinnovative.com/open-access-journals>

Indian Journal of Clinical Anatomy and Physiology

Journal homepage: <https://www.ijcap.org/>

Short Communication

Students' perception of rudimentary organs - Is the vermiform appendix a vestigial structure?

Sven Schumann^{1,2*}¹Institute of Anatomy, University Medical Center of the Johannes Gutenberg University Mainz, Mainz, Germany²Institute of Anatomy, Brandenburg Medical School, Neuruppin, Germany

ARTICLE INFO

Article history:

Received 19-07-2024

Accepted 23-07-2024

Available online 17-10-2024

Keywords:

Medical education

Teaching

Dissection

Evolution

Immunology

ABSTRACT

Vestigial anatomical structures or rudimentary organs are considered to have lost much or all of their function through evolution. In this survey, we asked medical students (n = 220) to define the terms “rudimentary organ or vestigial structure” and name up to three corresponding structures. 46 students completed the survey. With 21 times, the vermiform appendix was the most commonly mentioned organ. According to this pilot study, anatomists should be (more) careful in discussing and teaching vestigial structures so that students do not get confused in the context of highly functional organs.

This is an Open Access (OA) journal, and articles are distributed under the terms of the [Creative Commons Attribution-NonCommercial-ShareAlike 4.0 License](https://creativecommons.org/licenses/by-nc-sa/4.0/), which allows others to remix, tweak, and build upon the work non-commercially, as long as appropriate credit is given and the new creations are licensed under the identical terms.

For reprints contact: reprint@ipinnovative.com

1. Introduction

Vestigial anatomical structures or rudimentary organs are considered to have lost much or all of their function through evolution. These non-functional anatomical features (e.g., Plica semilunaris conjunctivae, Darwin's tubercle in humans) can give insights into the phylogenetic history of species.^{1–3} Additionally, vestigial structures can be of clinical importance since these structures might be confused with or be the source of pathologies (e.g., hamartoma of the juxtaoral organ of Chievitz).⁴ Nevertheless, there is some debate in anatomical literature which structures should be considered as vestigial and which not. While this discussion in several cases is just of academic interest (e.g., function of Mueller's orbitalis muscle), we were interested in students' perspective about rudimentary organs.⁵

2. Materials and Methods

In this prospective single centre study (University Medical Center Mainz, Germany), we requested a total number of

220 students of human medicine to fill in an online survey. This survey was performed in winter term 2023/2024. The participation was anonymous and voluntary. All participants were in the preclinical phase of medical studies (before first state examination) and after completion of a hands-on dissection course (66 hours of practical training on body donors). Students were asked to define the terms “rudimentary organ or vestigial structure” and name up to three corresponding structures (Table 1).

Table 1: Questions of the online survey

I have completed the dissection course	Yes
	No
Please define the term rudimentary organ / vestigial anatomical structure	
Please list three rudimentary organs / vestigial anatomical structures in humans	1.
	2.
	3.

* Corresponding author.

E-mail address: sven.schumann@mhb-fontane.de (S. Schumann).

3. Results

A number of 46 students completed the survey (20.9%). 39 students were able to define the terms vestigial anatomical structure or rudimentary organ (84.8%). Students should name up to three rudimentary organs or vestigial structures. 46 students named in total 91 structures. Most frequently, the vermiform appendix (appendix vermiformis) was mentioned (21 times, 23.1%). At second place, wisdom teeth (third molars, 17 times, 18.7%) and on third place the coccyx (Os coccygis, 9 times, 9.9%) were mentioned (Figure 1).

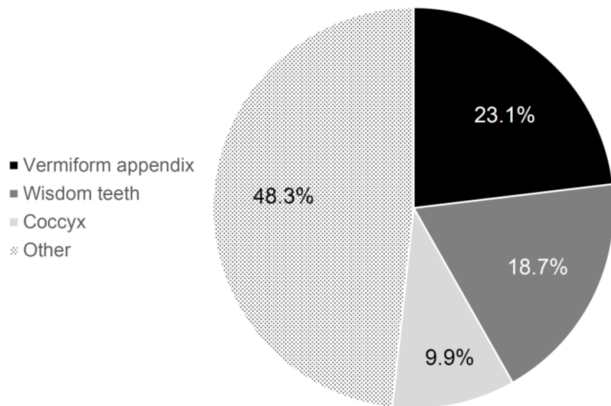


Figure 1: Putative vestigial structures named by students (n = 46)

4. Discussion

Almost half of the students thought that the vermiform process as a perfect example of a vestigial structure.

The vermiform appendix is a blind-ending tube with a length usually between 6 and 10 cm in adults. It lies at the posteromedial wall of the caecum below the ileocolic junction in the right iliac fossa with the tip lying most commonly retrocaecal, retrocolic or pelvic. The vermiform appendix has a continuous outer layer of longitudinal muscle formed by the fusion of the three taeniae coli.⁶ The lumen is irregularly narrowed by submucosal lymphoid tissue (Fig. 2 A). It may be widely patent in early childhood but often partially or wholly obliterates by fibrous tissue in the elderly. Agenesis or duplication of the vermiform appendix are exceptionally rare.^{7,8}

The appendix belongs to the so-called GALT (gut-associated lymphoid tissues).⁹ The submucosa typically contains large lymphoid aggregates that may extend into the mucosa and disrupt the integrity of the muscularis mucosae. The epithelium, which overlies the mucosal lymphoid tissue (follicle associated epithelium, dome epithelium, Fig. 2 B), contains microfold cells (M cells). Lymphoid follicles are absent at birth but accumulate during the first 10 years of life to become prominent. In adults, the lymphoid follicles gradually atrophy.⁶ The vermiform appendix has

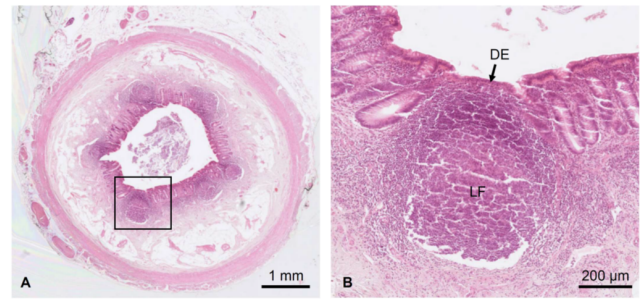


Figure 2: Microscopic anatomy of the vermiform appendix. **A:** Overview. **B:** Detail of a lymphoid follicle (LF) with dome epithelium (DE)

an immunoregulatory function (gut tonsil). In addition, it probably serves as a microbiome reservoir (“safe house”) that enables a rapid recolonization of the colon with a physiological bacterial flora familiar to the immune system after diarrhoea.¹⁰

Third molars (wisdom teeth) do not play a key role in mastication or speech production in humans. Additionally, there is a high variation of agenesis of third molars in different populations from practically 0% (Tasmania) to nearly 100% (Mexican Indians), suggesting that humans may be on evolutionary track to lose them totally.¹¹ The coccyx is not entirely useless in humans, because it has attachments to various muscles, tendons and ligaments. However, it is doubtful that the coccyx attachments are important to the well-being of humans.

5. Study Limitations

There are several limitations of this study. First, the number of participants was very low. This is because we only asked students who completed a full practical dissection course on body donors (no restrictions due to corona pandemic). We are convinced that learning on corpses directly shows variability of the human body and helps students to recognize vestigial structures. Nevertheless, this study should be repeated at different universities and countries. Due to the small sample size, we did not take into account sociodemographic characteristics of the participants.

6. Conclusion

Taken together, anatomists should be (more) careful in discussing and teaching vestigial structures so that students do not get confused in context with highly functional organs.

7. Source of Funding

This research received no external funding.

8. Conflicts of Interest

The author declares that there is no conflict of interest.

9. Ethical Statement

According to the Ethics Committee of Rhineland-Palatine no ethics approval was necessary for the present study, as it is not a biomedical research project in the narrower sense of the Declaration of Helsinki.

Acknowledgments

We thank Fabian Peter for assistance with the online survey and Silke D. Storsberg for proofreading of the manuscript.

References

1. Wiedersheim R. Der Bau des Menschen als Zeugnis für seine Vergangenheit. German: Nabu Press; 1895.
2. Smith HF, Wright W. Vestigial organ. Encyclopedia of animal cognition and behavior. Berlin: Springer; 2018.
3. Dhawan SS, Yedavalli V, Massoud TF. Atavistic and vestigial anatomical structures in the head, neck, and spine: An overview. *Anat Sci Int*. 2023;98(3):370–90.
4. Ide F. Juxtaoral organ of Chievitz presenting clinically as a tumour. *J Clin Pathol*. 2003;56(10):789–90.
5. Rodríguez-Vázquez JF, Mérida-Velasco JR, Arráez-Aybar LA, Jiménez-Collado J. Anatomic relationships of the orbital muscle of Muller in human fetuses. *Surg Radiol Anat*. 1998;20:341–4.
6. Standring S. Gray's Anatomy: The Anatomical Basis of Clinical Practice. 41st ed. Philadelphia: Elsevier; 2016.
7. Hammood ZD, Salih AM, Malah LA, Yas YT, Ghaleb HA, Kakamad FH. Agnesis of vermiform appendix; a case report with literature review. *Int J Surg Case Rep*. 2021;87:106364.
8. Chew DKW, Borromeo JR, Gabriel YA, Holgersen LO. Duplication of the vermiform appendix. *J Pediatr Surg*. 2000;35:617–8.
9. Kooij IA, Sahami S, Meijer SL, Buskens CJ. The immunology of the vermiform appendix: a review of the literature. *Clin Exp Immunol*. 2016;186(1):1–9.
10. Bollinger RR, Barbas AS, Bush EL, Lin SS, Parker W. Biofilms in the large bowel suggest an apparent function of the human vermiform appendix. *J Theor Biol*. 2007;249(4):826–31.
11. Rozkocová E, Marková M, Dolejší J. Studies on agnesis of third molars amongst populations of different origin. *Sb Lek*. 1999;100(2):71–84.

Author biography

Sven Schumann, Professor

Cite this article: Schumann S. Students' perception of rudimentary organs - Is the vermiform appendix a vestigial structure?. *Indian J Clin Anat Physiol* 2024;11(3):183-185.