

Content available at: <https://www.ipinnovative.com/open-access-journals>

Indian Journal of Clinical Anatomy and Physiology

Journal homepage: <https://www.ijcap.org/>

## Original Research Article

## Morphometric assessment of sternal foramina and sternal variations

Shaheen Sajid Abbas Rizvi<sup>1\*</sup>, Sharadkumar Pralhad Sawant<sup>1</sup><sup>1</sup>Dept. of Anatomy, K. J. Somaiya Medical College and Research Centre, Mumbai, Maharashtra, India

## ARTICLE INFO

## Article history:

Received 05-04-2024

Accepted 28-04-2024

Available online 06-05-2024

## Keywords:

Sternum  
Sternebrae  
Sternal Foramen  
Sternal Biopsy  
Acupuncture  
Manubrium  
Xiphoid  
Pericardium  
Heart  
X rays  
CT scan

## ABSTRACT

**Background:** The sternum is a crucial component of the thoracic cage. Its articulations and divisions play an important role in providing structural support to the thoracic cage and facilitating movements. The body of the sternum originates from four mesenchymal bars known as sternebrae, Incomplete fusion of the sternebrae or failure of fusion can lead to the development of a sternal foramen. The clinical significance of a sternal foramen lies in the potential risks associated with medical procedures such as acupuncture or sternal puncture for bone marrow biopsy.

**Materials and Methods:** A study was conducted on 100 sterna at K. J. Somaiya Medical College to find out the presence of sternal foramen, to study their site, size and shape and to discuss its clinical Implications. 20% of the specimens were found to possess a sternal foramen.

**Result:** The vertical to transverse diameter of these foramina were in the range of 4.4 – 6.9mm. Most of the foramen were found to be at the level of 3<sup>rd</sup> and 4<sup>th</sup> costal notches followed by Xiphoid process. The study also observed the variations in the shape of the manubrium and the body of the sternum and the variations of the Xiphoid process.

**Conclusion:** Failure to recognize the presence of sternal foramina can pose serious risks during medical procedures, potentially leading to damage to the pericardium and heart. Therefore, it is essential for healthcare practitioners to be aware of these variations and consider obtaining X-ray or CT scans to assess sternum morphology before performing invasive procedures. The study emphasizes the importance of comprehensive anatomical knowledge and careful clinical assessment when dealing with the sternum and underscores the need for precautionary measures to prevent complications associated with sternal foramina.

This is an Open Access (OA) journal, and articles are distributed under the terms of the [Creative Commons Attribution-NonCommercial-ShareAlike 4.0 License](https://creativecommons.org/licenses/by-nc-sa/4.0/), which allows others to remix, tweak, and build upon the work non-commercially, as long as appropriate credit is given and the new creations are licensed under the identical terms.

For reprints contact: [reprint@ipinnovative.com](mailto:reprint@ipinnovative.com)

## 1. Introduction

The sternum, also known as the breastbone, is indeed a crucial component of the thoracic cage. It is divided into three parts: the manubrium (prosternum), the body of the sternum (mesosternum), and the xiphoid process (metasternum). Manubrium (Prosternum) is the superior part of the sternum. It is identified by the suprasternal notch in the midline and the clavicular notches laterally. The manubrium articulates laterally with the sternal end of the clavicle, forming the sternoclavicular joint.

Additionally, it articulates with the first and second costal cartilages, forming the first and second chondrosternal joints, respectively.<sup>1</sup> Body of the Sternum (Mesosternum) is curved anteriorly and concave posteriorly. It articulates superiorly with the manubrium forming the manubriosternal joint and inferiorly with the xiphoid process forming the xiphisternal joint. Laterally, it features articulations for the third to sixth costal cartilages.<sup>2</sup> Xiphoid Process or Metasternum is the most inferior and shortest part of the sternum. It exhibits considerable variation in shape and size among individuals. It articulates laterally with the inferior portion of the seventh costal cartilage. These

\* Corresponding author.

E-mail address: [shaheen.rizvi@somaiya.edu](mailto:shaheen.rizvi@somaiya.edu) (S. S. A. Rizvi).

articulations and divisions of the sternum play important roles in providing structural support to the thoracic cage and facilitating movements of the ribcage during breathing and other activities.<sup>3</sup>

The sternum develops from the fusion of two cartilaginous sternal plates during fetal development. Initially, two bars of cartilage merge towards each other in eighth week of gestation to form the manubrium and the body of the sternum. The body of the sternum originates from four mesenchymal bars known as sternal bars. Chondrification of these bars occurs from cranial to caudal, forming sternabrae. Ossification typically begins around the tenth week of gestation. The sternum is ossified from six ossification centers: one for the manubrium, four for the body of the sternum, and one for the xiphoid process. The ossification centers for the upper part develop earlier and progress downwards over time. The timing of appearance of ossification centers follows a specific pattern, with the ossification centers for the manubrium and the initial pieces of the body of the sternum appearing first.<sup>4</sup> Incomplete fusion of the sternabrae or failure of fusion can lead to the development of a sternal foramen. This foramen, which can vary in size and shape, is typically located between the third and fourth sternabrae. The occurrence of a sternal foramen is attributed to irregular union, variations in the number and position of ossification centers, and the level of completeness in fusion. The clinical significance of a sternal foramen lies in the potential risks associated with medical procedures such as acupuncture or sternal puncture for bone marrow biopsy. Failure to recognize the presence of a sternal foramen can lead to serious complications, including damage to the pericardium and heart, highlighting the importance of thorough anatomical knowledge and careful clinical practice.<sup>5</sup>

## 2. Aim of the Study

1. To study the presence or absence of sternal foramen,
2. To study the site, size, shape and number of sternal foramina
3. To study the shape of the sternal bone
4. To underscore the possible clinical implications for patients with sternal foramina, outline essential guidelines for safely conducting sternal procedures in the presence of this anomaly and to prevent misinterpretations in radiological and pathological assessments.

## 3. Materials and Methods

100 dried human adult sterna were studied in the Department of Anatomy of K. J. Somaiya Medical College, Sion, Mumbai. They were grossly examined for the different shapes, presence and absence of sternal foramen, the location of the foramen and variations in the shape of the

sternum. The size of the sternal foramen was measured with the help of digital vernier callipers. Photographic were taken for documentation.

## 4. Results

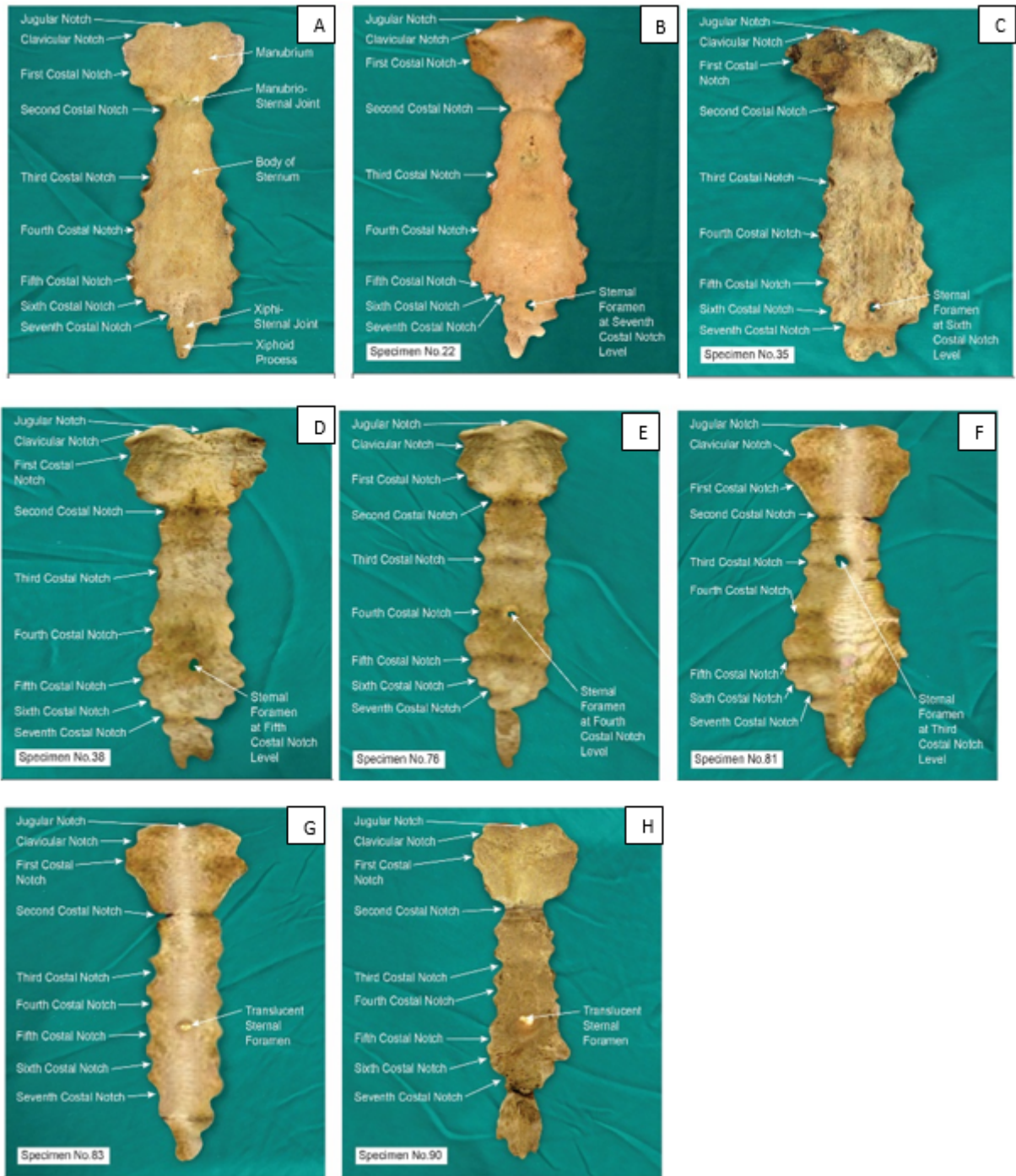
In this study, 20 sterna showed the presence of sternal foramen. Single sternal foramen in the body of the sternum was noted in 14 bones, 2 bones showed the presence of a translucent gap instead of a complete foramen, in 4 bones a foramen was observed in the xiphoid process of which 3 foramina were complete and one was incomplete.

The shape of the sternum was observed as normal flat shape in 42 sterna, longitudinal in 36 and oval in 22 specimens. The shape of the manubrium also showed variations, Triangular shape was seen in 20 specimens, quadrangular manubrium was observed in 65 and trapezoid shape in 15 specimens.

A number of variations were observed in the Xiphoid process, bifid Xiphoid was most prevalent seen in 33 specimens, other shapes observed were triple Xiphoid in 1 specimen, hook like in 2 specimens, reverse S shaped in 1 specimen, elongated in 3 specimens, curved ventrally in 1 specimen and curved dorsally in 1 specimen.

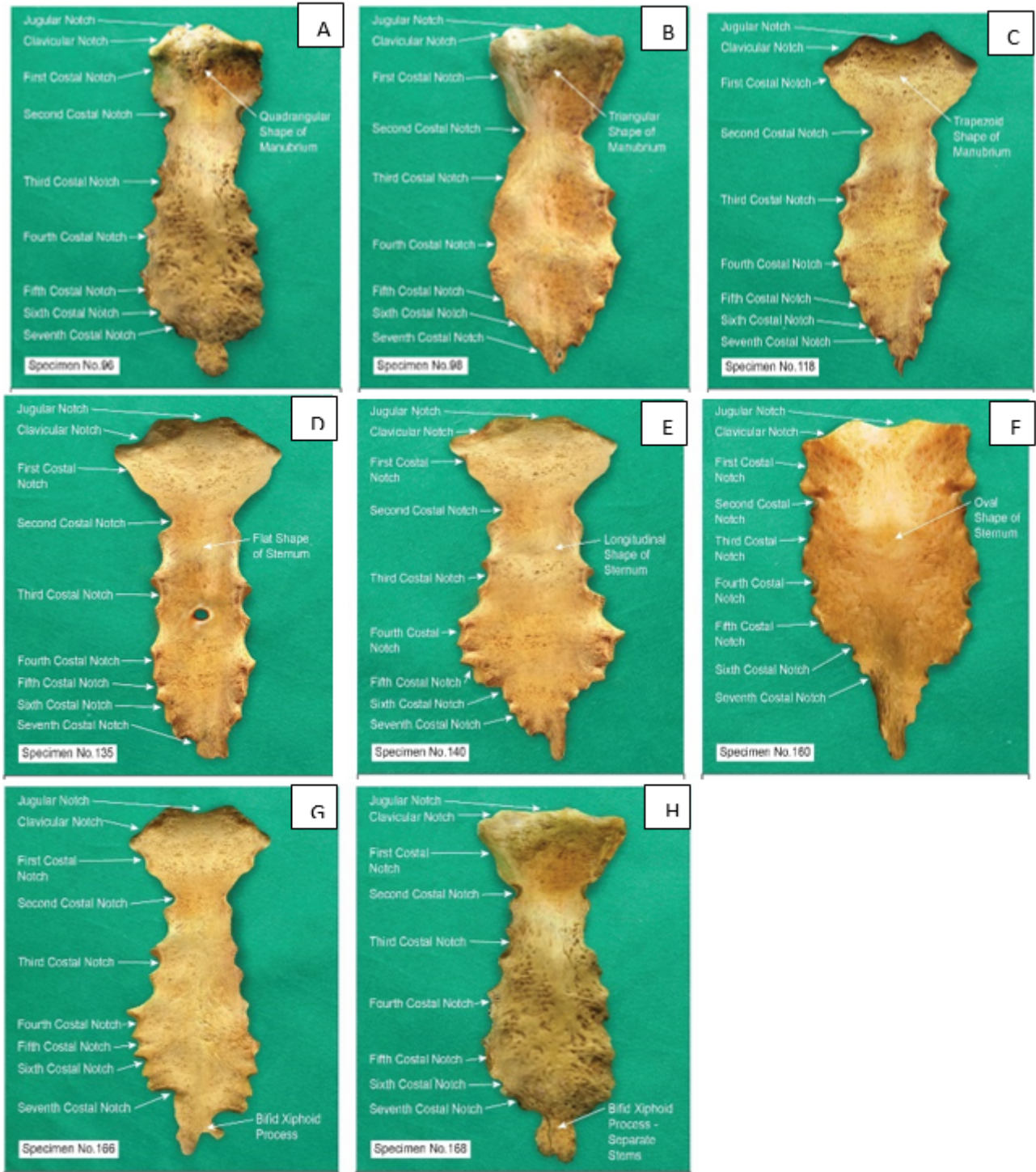## 5. Discussion

The sternum originates from the transformation of bilateral sternal plates during embryonic development. Fusion of these plates with the ribs commences approximately during the 10th week of fetal life. Following this, the process of sternal bone formation takes place through endochondral ossification, which is governed by specific ossification centers situated in both the manubrium (one center) and the mesosternum (three centers). Ossification progresses along distinct segments within the mesosternum, termed as sternabrae. Morphological changes in size and structure occur in the sternum until around the age of 30, with segmental fusion potentially continuing until about the 25th year of life. In cases where fusion is hindered, it can lead to the manifestation of a cleft sternum or sternal foramen. Sternal foramina denote particular structural anomalies within the sternum.<sup>6</sup> Defects in the partial fusion of cartilage bars can result in the formation of openings within the sternum. These sternal foramina may emerge in the manubrium, body, or xiphoid process. Their presence signifies an impaired fusion of ossified segments, which can manifest in any anatomical region of the sternum.<sup>7</sup> Various studies in the literature have reported a prevalence of sternal foramina ranging from 6% to 20%. In a study conducted by Paraskevas et al.,<sup>8</sup> the incidence was found to be 18.3%, which closely aligns with our own findings. Interestingly, Paraskevas et al. observed one specimen with multiple xiphoid foramina, a feature not encountered in our study. Other investigations, such as those by Gkantsinikoudis et

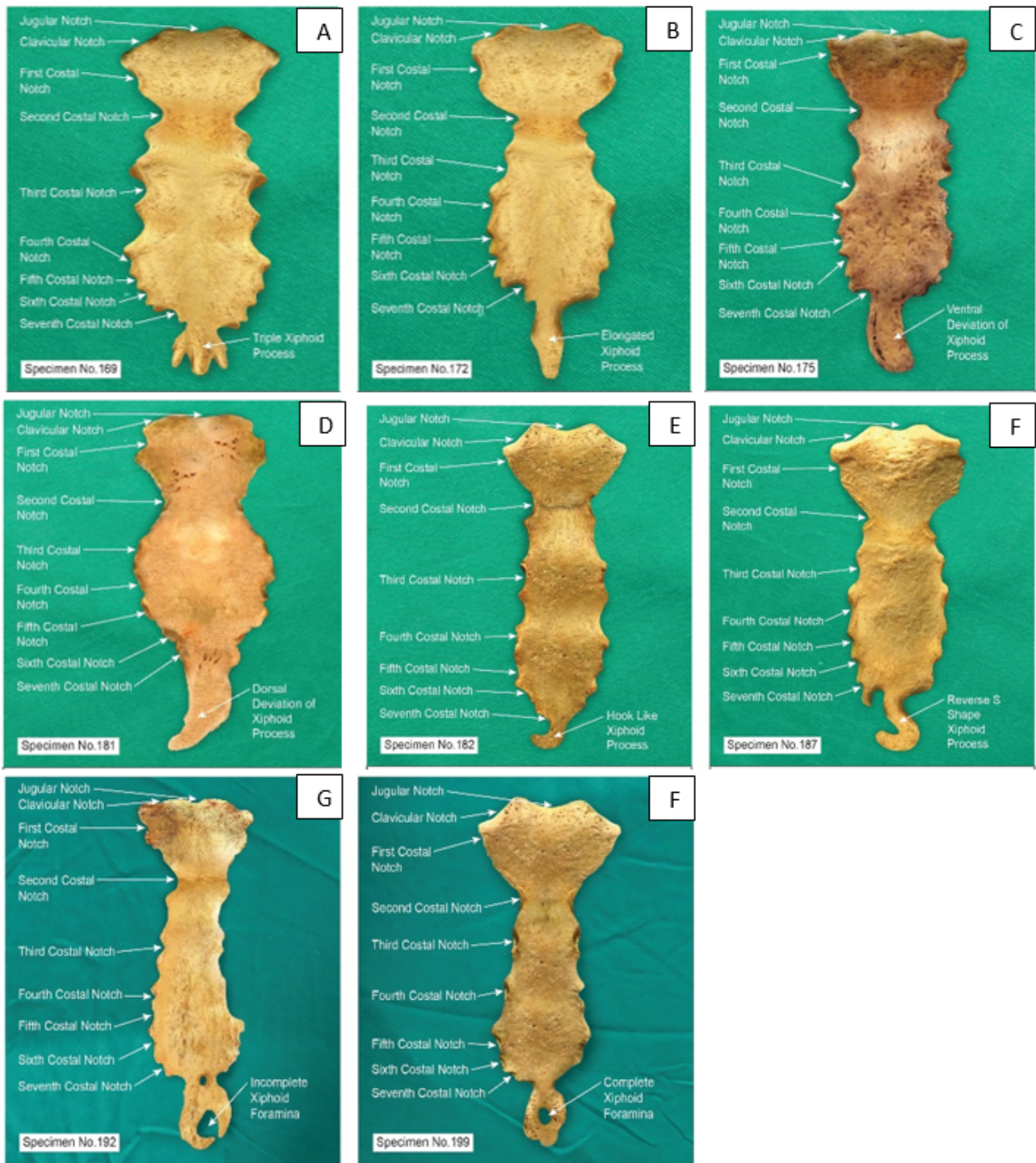


**Figure 1:** Specimens showing presence of sternal foramen; **A):** Photographic presentation of normal sternum; **B):** Photographic presentation of sternal foramen at seventh costal notch level; **C):** Photographic presentation of sternal foramen at sixth costal notch level; **D):** Photographic presentation of sternal foramen at fifth costal notch level; **E):** Photographic presentation of sternal foramen at fourth costal notch level; **F):** Photographic presentation of sternal foramen at third costal notch level; **G):** Photographic presentation of translucent sternal foramen; **H):** Photographic presentation of translucent sternal foramen





**Figure 2:** Showing variations in the shape of sternum, manubrium and xiphoid process; **A):** Photographic presentation of quadrangular shape of manubrium; **B):** Photographic presentation of Triangular shape manubrium; **C):** Photographic presentation of trapezoid shape manubrium; **D):** Photographic presentation of flat shape of sternum; **E):** Photographic presentation of longitudinal shape of sternum; **F):** Photographic presentation of oval shape of sternum; **G):** Photographic presentation of bifid xiphoid process; **H):** Photographic presentation of bifid xiphoid process- Separate stems



**Figure 3:** Showing variations in the xiphoid process; **A):** Photographic presentation of triple xiphoid process; **B):** Photographic presentation of elongated xiphoid process; **C):** Photographic presentation of ventral deviation of xiphoid process; **D):** Photographic presentation of dorsal deviation of xiphoid process; **E):** Photographic presentation of hook like xiphoid process; **F):** Photographic presentation of reverse shape xiphoid process; **G):** Photographic presentation of incomplete xiphoid foramina; **H):** Photographic presentation of complete xiphoid foramina



**Table 1:** No. of specimens showing presence of sternal foramen

Sternal Foramen	No. of specimens %	Location of Foramen				
		3 <sup>rd</sup> costal notch	4 <sup>th</sup> costal notch	5 <sup>th</sup> costal notch	6 <sup>th</sup> costal notch	7 <sup>th</sup> costal notch
Presence of SF in body of sternum	14	5	4	2	1	2
Translucent gap in body of sternum	2	-	1	1	-	-
Presence of SF in Xiphoid process	4	-	-	-	-	-

**Table 2:** Size of sternal foramen in mm with vernier calliper

No. of foramen	3 <sup>rd</sup> costal notch	4 <sup>th</sup> costal notch	5 <sup>th</sup> costal notch	6 <sup>th</sup> costal notch	7 <sup>th</sup> costal notch	Xiphoid process
1	3.65 x 7.5	6.38 x 10.4	4 x 5	4.65 x 7.35	3.28 x 10.1	5.5 x 4.5
2	4 x 10	3.2 x 7.55	3.12 x 6.5		5 x 8.5	3.8 x 7.3
3	5.35 x 7.22	4 x 5.24	-	-	-	4.2 x 3.5
4	4 x 10.55	5.5 x 4.5	-	-	-	Incomplete
5	5.81 x 1.67		-	-	-	-
Translucent gap	-	11.72 x 8	5.3 x 3.92	-	-	-

**Table 3:** No. of specimens showing variations in shape of manubrium and sternum

Shape of manubrium				Shape of sternum	
Triangular	Quadrangular	Trapezoid	Normal Flat	Longitudinal	Oval
20	65	15	42	36	22

**Table 4:** No. of specimens showing variations in Xiphoid process

Normal	Bifid	Triple	Hook like	Reverse S shaped	Elongated	Ventral deviation	Dorsal Deviation
58	33	1	2	1	3	1	1

**Table 5:** Incidence of sternal foramina in the literature

Study	No. of specimens	Percentage of sternal foramen observed	Mean diameter of SF (Vertical – Transverse)
Cooper PD et al (1988)	2016 Radiographs	6.7	
Busaid et al (2012)	80	13.8	
Babinski et al (2012)	180	16.6	5.5 – 4.5
Paraskevas et al (2015)	60	18.3	4.4 -3.4
Gkantsinikoudis et al (2017)	35 (20 males and 15 females)	14.2 in male, 6.6 female	5.1- 4.8
Kirum et al (2017)	85	12.9	
Arumugam et al (2018)	80	14	
Present study (2024)	1002	20	4.4 – 6.9

al.<sup>9</sup> (14.2% in males, 6.6% in females), Kirum et al.<sup>10</sup> (12.9%), Busaid et al.<sup>11</sup> (13.8%), Arumugam<sup>12</sup> (14%), and Babinski et al.<sup>13</sup> (16.6%), reported incidences ranging between 12% to 16%. However, Cooper PD et al.<sup>14</sup> reported a notably lower incidence of sternal foramina at 6.7%, along with the observation of a manubrial foramen in one specimen. Arumugam, in a study of 80 dry sterna, noted a foramen in 2% of the manubria, a relatively rare occurrence. In contrast, our study did not observe any foramina in the manubrium. Similarly, other authors

like Kumarasamy et al.,<sup>15</sup> Kumar et al.,<sup>16</sup> and Tandon et al.<sup>17</sup> noted sternal foramina in only one specimen each in their respective studies. Furthermore, a multidetector CT study by Duraikannu et al.<sup>18</sup> depicted well-corticated, round to oval-shaped defects in the midline of the sternal body, with an average diameter of 6 mm, with the largest foramen measuring 11 mm. They also identified a specimen with multiple foramina in the body and xiphoid, and another specimen in which the foramen was not completely formed or was translucent, a phenomenon they termed as a

'Pseudofoamen', similar to observations made in our study. In our current investigation, the sternal foramina exhibited oval or round shapes, consistent with previous studies mentioned earlier. The average vertical and transverse diameters of the sternal foramina reported in the literature ranged from 3.4mm to 6.7mm. However, in our study, we found that the mean vertical diameter was 4.4 mm and the mean transverse diameter was 6.9mm. Interestingly, the maximum vertical diameter observed in the translucent gap was 11.72mm, surpassing measurements from other studies. In a cadaveric examination conducted by Selthofer et al.,<sup>19</sup> the standard shape of the sternal body was described as longitudinal or oval. More recently, in a study by Bayarogullari et al.<sup>20</sup> assessing the postnatal development of the sternum using MDCT, the flat type was the most commonly observed. In our investigation, we found that the flat type was present in 42% of the specimens examined.

## 6. Clinical Significance

Individuals with a sternal foramen typically do not exhibit symptoms, and the presence of the defect is often discovered incidentally through radiological imaging or during midline sternotomy procedures. Despite appearing minor, a sternal foramen holds significant clinical implications that are frequently overlooked by clinicians, acupuncturists, radiologists, and pathologists. The clinical significance of this defect becomes evident during procedures in the region, such as bone marrow biopsy or acupuncture, where the sternum's proximity to mediastinal structures exposes the lungs, heart, and major blood vessels to potential harm. Complications stemming from sternal puncture have been documented in medical literature, including inadvertent puncture of retrosternal organs like the heart and lungs, which can lead to conditions such as tamponade or pneumothorax. Instances of fatal cardiac tamponade following sternal puncture in the lower part of the sternum associated with a congenital sternal foramen have been reported.<sup>21</sup> On oblique radiographs, sternal foramina may be detectable, although the superimposition of mediastinal structures can partially obscure the anomaly. Helical or Multislice CT imaging provides the clearest visualization of bone structures without superimposition and is the preferred imaging modality for confirming the diagnosis of sternal foramina. However, in cross-sectional imaging of the sternum, sternal foramina can be mistakenly interpreted as osteolytic lesions.<sup>22</sup> Other variations of the sternum include a double-ended xiphoid process and a single xiphoid foramen. A cleft sternum, resulting from the incomplete midline fusion of the sternum, exposes the heart and major blood vessels and is often associated with craniofacial haemangioma and omphalocele. Sternal foramina may also be linked with accessory fissures in the left lung. Performing blinded sternal interventions in patients with a sternal foramen can lead to fatal injuries in the pericardium, right

ventricle of the heart, or aorta. In lean individuals, the distance between the skin and the pericardium is typically only about 10-20 mm. Among reported injuries resulting from a lack of awareness of sternal foramina, 14 cases involved cardiac tamponade, eight of which were fatal.<sup>23</sup> Therefore, it is essential to review previous CT scans or conduct pre-procedural ultrasound scans to exclude the presence of a sternal foramen before undertaking such interventions. It is imperative to exercise caution when inserting a needle, particularly if it seems to be penetrating deeper than the level of the adjacent sternal surface, which may indicate the presence of a sternal foramen (SF). Needles should be directed towards the upper part of the sternal body to avoid the 'danger zone' located between the fourth and sixth costochondral junctions. Additionally, conducting a sternal biopsy under CT guidance enhances safety.<sup>24</sup> Furthermore, awareness of this anomaly holds significance in forensic medicine. The presence of sternal holes can potentially be misinterpreted as penetrating traumatic injuries or instances of bullet penetration, or they may be mistaken for acquired lesions such as fractures or lytic lesions.<sup>25</sup> Therefore, understanding the existence of sternal foramina is crucial for accurate forensic evaluation.

## 7. Conclusion

Awareness of this variation is crucial for radiologists, clinicians, and forensic experts alike. Before conducting intrinsic procedures such as bone marrow biopsy or acupuncture, it's essential to consider the presence of potential sternal foramen for serious complications like cardiac tamponade and pneumothorax following sternal puncture. Therefore, it is advisable to obtain radiographs to rule out sternum variations before proceeding with such procedures. This precaution can help mitigate the risk of adverse outcomes associated with sternal puncture in individuals with S.

## 8. Source of Funding

None.

## 9. Conflict of Interest


None.


## References

1. Sinnatamby CS. Last anatomy regional and applied. 12th ed. USA: Elsevier; 2011.
2. Graeber GM, Nazim M. The anatomy of the ribs and the sternum and their relationship to chest wall structure and function. *Thorac Surg Clin.* 2007;17(4):473-89.
3. Xie YZ, Wang BJ, Yun JS, Chung GH, Ma ZB, Li XJ, et al. Morphology of the human xiphoid process: dissection and radiography of cadavers and MDCT of patients. *Surg Radiol Anat.* 2014;36(3):209-17.
4. Standring S. The Anatomical Basis of Clinical Practice. In: Gray's Anatomy. London: Churchill Livingstone Elsevier; 2008.

5. Larsen WJ. Human embryology. 2nd ed. New York: Churchill Livingstone; 1997. p. 77–8.
6. Moore MK, Stewart JH, McCormick WF. Anomalies of the human chest plate area: Radiographic findings in a large autopsy population. *Am J Forensic Med Pathol.* 1988;9(4):348–54.
7. Ashley GT. The relationship between the pattern of ossification and the definitive shape of the mesosternum in man. *J Anat.* 1956;90(1):87–105.
8. Paraskevas G, Tzika M, Anastasopoulos N, Kitsoulis P, Sofidis G, Natsis K. Sternal foramina: incidence in Greek population, anatomy and clinical considerations. *Surg Radiol Anat.* 2015;37(7):845–51.
9. Gkantsinikoudis N, Chaniotakis C, Gkadaris G, Georgiou N, Kapetanakis S. Morphological approach of the sterna foramen an Anatomic study and short review of the literature. *Folia Morphol (Warsz).* 2016;76(3):484–90.
10. Kirum GG, Munabi IG, Kukiriza J, Tumusiime G, Kange M, Ibingira C, et al. Anatomical variations of the sternal angle and anomalies of adult human sterna from the Galloway osteological collection at Makerere University Anatomy Department. *Folia Morphol (Warsz).* 2017;76(4):689–94.
11. El-Busaid H, Kaisha W, Hassanali J, Hassan S, Ogeng'o J, Mandela P. Sternal foramina and variant xiphoid morphology in a Kenyan population. *Folia Morphol (Warsz).* 2011;71(1):19–22.
12. Arumugam K, Hemalatha GA. Morphometric study of sternal foramen in adult human dry sternum. *Int J Anat Var.* 2018;11(4):111–4.
13. Babinski MA, Rafael FA, Steil AD, Rodrigues CF, Sgrotta EA. High prevalence of sternal foramen: Quantitative, anatomical analysis and its clinical implication in acupuncture practice. *Int J Morphol.* 2012;30(3):1042–9.
14. Cooper PD, Stewart JH, McCormick WF. Development and morphology of the sternal foramen. *Am J Forensic Med Pathol.* 1988;9(4):342–7.
15. Kumarasamy SA, Agrawal R. A large sternal foramen. *Int J Anat Var.* 2011;4:195–6.
16. Kumar J, Dhattaswall SK, Pal V. The sternal foramen: The possible forensic misinterpretation of an anatomic abnormality. *J Ind Acad Foren Med.* 2015;137:315–6.
17. Tandon A, Garo RD. Sternal foramen case report. *Med J Dr DY Patil Univ.* 2016;9:127–8.
18. Duraikannu C, Noronha OV, Sundarrajan P. MDCT evaluation of sternal variations: Pictorial essay. *Indian J Radiol Imaging.* 2016;26(2):185–94.
19. Selthofer R, Nikolić V, Mrcela T. Morphometric analysis of the sternum. *Coll Antropol.* 2006;30(1):43–7.
20. Bayarogullari H, Yengil E, Davran R, Ağlagül E, Karazincir S, Balci A. Evaluation of the postnatal development of the sternum and sternal variations using multidetector CT. *Diagn Interv Radiol.* 2014;20(1):82–9.
21. Halvorsen TB, Anda SS, Naess AB. Fatal cardiac tamponade after acupuncture through congenital sternal foramen. *Lancet.* 1995;345(8958):1175.
22. Yekeler E, Tunaci M, Tunaci A, Dursun M, Acunas G. Frequency of sternal variations and anomalies evaluated by MDCT. *AJR Am J Roentgenol.* 2006;186(4):956–60.
23. Skandalakis J. Skandalakis Surgical Anatomy: The Embryologic And Anatomic Basis Of Modern Surgery. India: Jaypee; 2004.
24. Uzun C, Atman ED, Ustuner E, Mirjalili SA, Oztuna D, Esmer T. Surface anatomy and anatomical planes in the adult turkish population. *Clin Anat.* 2016;29(2):183–90.
25. Gossner J. Relationship of sternal foramina to vital structures of the chest: a computed tomographic study. *Anat Res Int.* 2013;2013:780193. doi:10.1155/2013/780193.

### Author biography

**Shaheen Sajid Abbas Rizvi**, Assistant Professor  <https://orcid.org/0009-0003-2981-1982>

**Sharadkumar Pralhad Sawant**, Professor and Head  <https://orcid.org/0000-0001-7843-3322>

**Cite this article:** Rizvi SSA, Sawant SP. Morphometric assessment of sternal foramina and sternal variations. *Indian J Clin Anat Physiol* 2024;11(1):42–49.