

Content available at: <https://www.ipinnovative.com/open-access-journals>

Indian Journal of Clinical Anatomy and Physiology

Journal homepage: <https://www.ijcap.org/>

## Case Report

# A case report on the bilateral absence of fourth tendinous slip of the flexor digitorum brevis muscle in the foot: Exploring evolutionary and surgical relevance

Archishnu Vedanta Parida<sup>1</sup>, Devendra Pal Singh<sup>1</sup>, Sipra Rout<sup>1\*</sup>

<sup>1</sup>Dept. of Anatomy, All India Institute of Medical Sciences, Bhubaneswar, Odisha, India



### ARTICLE INFO

#### Article history:

Received 10-12-2023

Accepted 22-12-2023

Available online 20-01-2024

#### Keywords:

FDB

Musculo cutaneous flap

Phylogenetic degeneration

### ABSTRACT

The flexor digitorum brevis (FDB) muscle extends across the central region of the sole, positioned deep beneath the plantar aponeurosis. It inserts into the lateral four toes through four slender musculotendinous slips. Functionally, this muscle reinforces the foot arch by facilitating flexion at the interphalangeal and metatarsophalangeal joints of the lateral toes. In clinical contexts, the FDB muscle serves as a musculocutaneous flap in reconstructive surgeries, addressing various foot deformities. Despite its small size, the FDB muscle carries significant evolutionary importance, indicating potential phylogenetic degeneration in humans due to adaptations to diverse lifestyles. The anatomical variation presented in this case report holds importance, as the presence or absence of the FDB muscle can play a crucial role in maintaining arch integrity and holds relevance from a surgical perspective.

This is an Open Access (OA) journal, and articles are distributed under the terms of the [Creative Commons Attribution-NonCommercial-ShareAlike 4.0 License](https://creativecommons.org/licenses/by-nc-sa/4.0/), which allows others to remix, tweak, and build upon the work non-commercially, as long as appropriate credit is given and the new creations are licensed under the identical terms.

For reprints contact: [reprint@ipinnovative.com](mailto:reprint@ipinnovative.com)

## 1. Introduction

The flexor digitorum brevis (FDB) muscle has a significant role in clinical and surgical importance in current medical practice. Its use during procedures like soft tissue reconstructive surgeries and flap surgeries has furnished this seemingly insignificant muscle a substantial credit. This is one of the intrinsic muscles of the sole that lies immediately deep to the central part of the plantar aponeurosis.<sup>1</sup> It represents a morphological continuation of the plantaris tendon distally. It provides four slender tendons for the lateral four toes, which split at the level of the metatarso-phalangeal joint, to allow the passage for flexor digitorum longus (FDL) tendons before getting inserted to the lateral side of the respective middle phalanx. The FDB muscle has shown considerable morphological variations over the years. The observed phenomenon is ascribed to phylogenetic degeneration, primarily due to

diverse anatomical presentations as shown in Figure 1. These presentations include the absence or hypotrophy of the fourth slip, which is projected for the little toe.<sup>2</sup>

## 2. Presentation of Case

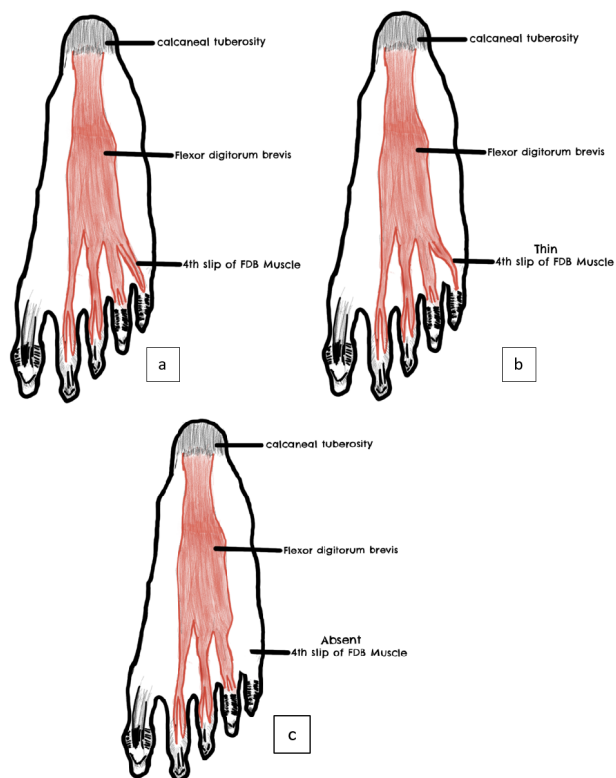
While conducting routine cadaver dissection for undergraduate students in the Anatomy department, we noted the absence of the fourth tendon of the FDB in the foot of a female cadaver approximately 63 years old. This absence was bilateral, as illustrated in Figure 2. The remaining three tendinous slips were normal, and inserted into the second, third, and fourth toes, respectively. There was no observed additional muscle or tendinous slip for the fifth toe. All other muscles and neurovascular structures in the sole were found to be normal on both sides.

## 3. Discussion

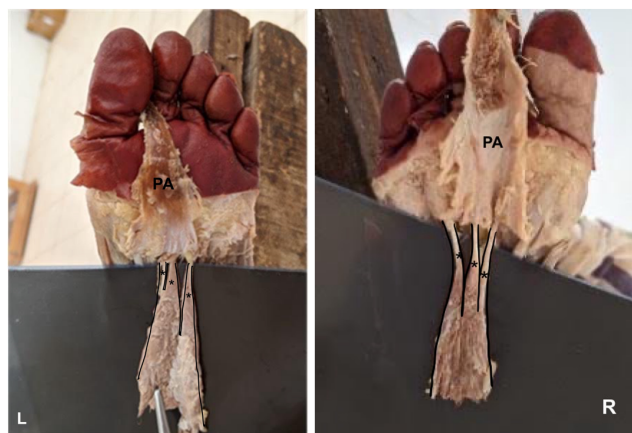
The Flexor Digitorum Brevis is anatomically one of the most variable muscles in the human body.<sup>3</sup> Among its

\* Corresponding author.

E-mail address: [siprarout@gmail.com](mailto:siprarout@gmail.com) (S. Rout).



**Figure 1:** Schematic representation of variable anatomical presentations of fourth slip of FDB muscle. **a):** Muscular slip, **b):** Thin slender slip, **c):** Absent



**Figure 2:** Bilateral absence of the fourth slip of FDB can be observed on both sides i.e. Right (R) and left (L) side. PA: Plantar aponeurosis, FDB: Flexor digitorum brevis muscle, (\*) showing the three existing slips

four tendinous slips, the fourth one is commonly observed to have degenerated, constituting 60-70% of cases during cadaveric dissection. FDB helps to brace the longitudinal arch of the foot by flexing the proximal interphalangeal (IP joint) and metatarsophalangeal (MP joint) joints of the lateral four toes.<sup>3</sup> The Muscular flap of this muscle is used in the reconstruction of the heel pad and it is frequently used to correct crossover toe deformity so architecture of the foot is maintained.<sup>4,5</sup> Besides this also assists in toe grip by contributing to the ability to grasp with the toes. This action is involved in activities such as maintaining balance, especially when walking on uneven surfaces.

### 3.1. Evolutionary significance of FDB muscle

In a study conducted by Dr. Rebecca Fisher in 2009 on the Red Panda (*Ailurus fulgens*), it was noted that the FDB originates from the plantar surface of the tendon of the Flexor Digitorum Superficialis (FDS) at the level of the plantar tubercles of the calcaneal tuberosity.<sup>6</sup> In one limb, the FDB was observed to be fused proximally with the Abductor Digit Minimi, and distally it fused with the Quadratus Plantae at the level of the metatarsal bases. However, in another limb, the FDB gave rise to three fascicles with five tendons extending to all of the digits. This variability may be attributed to the evolutionary process, adapting to the specific requirements of the Red Panda, where the FDB is crucial for supporting the great toe needed for climbing trees.

The function of the FDB muscle is to flex the proximal interphalangeal joints and metatarsophalangeal joints of the lateral four toes. This can be attributed to the usage regularity of the fifth toe in humans which is minimal when compared to the little finger. It has no opposition action in humans. The variations presented in this paper may be the most likely result of phylogenetic degeneration which is due to a gradual reduction in the use of the little toe leading to disuse atrophy in humans.

### 3.2. Surgical importance of FDB

Clinically the FDB is used as a musculocutaneous flap in cases of reconstruction of heel pad and also used to correct deformities of the foot like claw foot and hammer toe.<sup>7,8</sup> A study done by García, Alberto & Bayod, on Claw toe deformity, showed the usage of Flexor digitorum longus (FDL) tendon transfer as a gold standard for its correction.<sup>9</sup> The usage of the FDB tendon as an alternative has been recently proposed as an alternative method to treat such deformity correction. On comparison it was found that the reduction in the dorsal displacement of the proximal phalanx (PP) for the second and third toes was very similar (about 4.3mm for each intervention), both achieving a significant reduction in MPJ dorsiflexion when compared to no intervention (displacements are reduced by

approximately 51%). In the fourth and fifth toes, only a small correction in the deformity was achieved with both techniques (10% and 7%, respectively). FDB and FDL tendon transfer reduced the stress level when compared with the non-operated pathologic foot (the reduction of stresses for the second and third PP ranged between 20% and 40%). FDB transfer resulted in a more uniform distribution of stress along the entire toe, although differences were small in all cases. These results confirm that both tendon-transfer techniques are effective in the treatment of claw toe deformity. Therefore, the choice of technique is at the discretion of the surgeon.

The FDB is also related to toe deformities such as the congenital curly toe and hammer toes.<sup>8</sup> For patients who require a proximal interphalangeal (PIP) joint arthroplasty or fusion in addition to a Weil osteotomy, the transfer of the FDB tendon to the PIP joint has restored the windlass mechanism and observed to decrease the incidence of floating toes.<sup>4,10</sup>

FDB transfer to the interosseous and lumbrical muscles has been effectively used in treating dynamic claw toe deformity.<sup>11</sup> Transposition of the FDB tendon has been described for flexible hammer toes.<sup>12</sup> Its clinical relevance extends to soft tissue reconstruction; the FDB lap has been used to cover heel and distal plantar defects.<sup>10,13</sup> Hence, in-depth knowledge should be gained, as it will be of benefit to surgeons while performing such surgeries.

The FDB muscle, particularly its fourth slip, holds notable surgical significance in medical practice. Nevertheless, a considerable proportion of tendons directed towards the little toe, specifically the fourth slip, undergoes phylogenetic degeneration. According to the findings from a meta-analysis conducted by Yammine K., 2015, the true prevalence rate stands at 31.3%, with a crude prevalence rate of 47%. Notably, there is a bilateral prevalence rate of 38.2%, and in the Indian population, a true prevalence rate of 77.3% was observed. The odds ratio of 1.5 significantly favours the female gender field.<sup>14</sup> Understanding the frequency of agenesis in the fourth slip of the flexor digitorum brevis, along with variations linked to demographic characteristics, is crucial for procedures such as tendon repair, tendon transfer, or soft tissue reconstruction in foot surgery.

### 3.3. Buffer action of FDB muscle contributes to its elastic strain energy

Some studies have pointed out that the FDB tendon acts as a buffer for the contractile tissues, sparing the muscle from experiencing high and potentially damaging strains and strain rates during rapid decelerations of the body.<sup>15,16</sup> According to Smith RE et al. (2022), the FDB muscle uses elastic strain energy to contribute to both work generation and energy absorption at the foot.<sup>17</sup> The FDB utilizes its tendinous tissues to enhance power output during arch recoil

when mechanical energy is produced at the foot, as well as to buffer power input into its muscle fascicles while the foot dissipates energy.

The FDB exhibits a strong capacity to play a crucial role in maintaining postural control. It contributes approximately 14.5% torque to counteract gravity, ensuring postural stability, especially during horizontal perturbations.<sup>18</sup> Managing and rehabilitating the muscles of the plantar foot, along with the resulting mechanical benefits, can be valuable in clinical settings. It adds an extra dimension to postural and pedal rehabilitation. Therefore, the lack or degeneration of slips in the tendons of the FDB could potentially have an impact.

## 4. Conclusion

The FDB muscle is small but can be a prime example of evolutionary significance which is suggestive of phylogenetic degeneration in humans due to lifestyle change. The absence of both bilateral and unilateral FDB muscle in humans as seen in our observed case and in other case reports as discussed is evidence of phylogenetic degeneration. In some cases of 5<sup>th</sup> slip as well in primates adds to the fact that as the muscle is more used in cases of red pandas and other primates, they might be going in line of phylogenetic evolution. Clinically the FDB muscle is used as a Musculocutaneous flap in reconstructive surgeries involving various deformities of the foot. The anatomical variation seen in this case report is significant because the presence or absence can be of significant importance.

## 5. Source of Funding

None.

## 6. Conflict of Interest

None.

## References

1. Stecco C, Corradin M, Macchi V, Morra A, Porzionato A, Biz C. Plantar fascia anatomy and its relationship with Achilles tendon and paratenon. *J Anat.* 2013;223(6):665–76.
2. Lobo SW, Menezes RG, Mamata S, Baral P, Hunnargi SA, Kanchan T, et al. Phylogenetic variation in flexor digitorum brevis: a Nepalese cadaveric study. *Nepal Med Coll J.* 2008;10(4):230–2.
3. Nathan H, Gloobe H. Flexor digitorum brevis—anatomical variations. *Anat Anz.* 1974;135(3):295–301.
4. Lee LC, Charlton TP, Thordarson DB. Flexor digitorum brevis transfer for floating toe prevention after Weil osteotomy: a cadaveric study. *Foot Ankle Int.* 2013;34(12):1724–8.
5. Malhotra K, Davda K, Singh D. The pathology and management of lesser toe deformities. *EFORT Open Rev.* 2016;1(11):409–19.
6. Fisher RE, Adrian B, Elrod C, Hicks M. The phylogeny of the red panda (*Ailurus fulgens*): evidence from the hindlimb. *J Anat.* 2008;213(5):607–28.
7. Attinger CE, Ducic I, Cooper P, Zelen CM. The role of intrinsic muscle flaps of the foot for bone coverage in foot and ankle defects in diabetic and nondiabetic patients. *Plast Reconstr Surg.* 2002;110(4):47–54.

8. Tokioka K, Nakatsuka T, Tsuji S, Ishida K, Obana K, Osawa K, et al. Surgical correction for curly toe using open tenotomy of flexor digitorum brevis tendon. *J Plast Reconstr Aesthet Surg.* 2007;60(12):1317–22.
9. García-González A, Bayod J, Prados-Frutos JC, Losa-Iglesias M, Jules KT, DeBengoa-Vallejo RB, et al. Finite-element simulation of flexor digitorum longus or flexor digitorum brevis tendon transfer for the treatment of claw toe deformity. *J Biomech.* 2009;42(11):1697–704.
10. Girdlestone GR. Physiotherapy for hand and foot. *Physiotherapy.* 1947;32(11):167–9.
11. Errichiello C, Marcarelli M, Pisani PC, Parino E. Treatment of dynamic claw toe deformity flexor digitorum brevis tendon transfer to interosseous and lumbrical muscles: a literature survey. *Foot Ankle Surg.* 2012;18(4):229–32.
12. Vallejo RBB, Iglesias MEL, Frutos JCP, Rodriguez MF, Jules KT, et al. Dorsal approach to transfer of the flexor digitorum brevis tendon. *J Am Podiatr Med Assoc.* 2011;101(4):297–306.
13. Sakai N, Yoshida T, Okumura H. Distal plantar area reconstruction using a flexor digitorum brevis muscle flap with reverse-flow lateral plantar artery. *Br J Plast Surg.* 2001;54(2):170–3.
14. Yammine K. The fourth slip of the flexor digitorum brevis muscle of the human foot. A systematic review and meta-analysis. *Ital J Anat Embryol.* 2015;120(1):59–70.
15. Konow N, Azizi E, Roberts TJ. Muscle power attenuation by tendon during energy dissipation. *Proc Biol Sci.* 1731;279(1731):1108–13.
16. Konow N, Roberts TJ. The series elastic shock absorber: tendon elasticity modulates energy dissipation by muscle during burst deceleration. *Proc Biol Sci.* 1804;282(1804):20142800.
17. Smith RE, Lichtwark GA, Kelly LA. Flexor digitorum brevis utilizes elastic strain energy to contribute to both work generation and energy absorption at the foot. *J Exp Biol.* 2022;225(8):jeb243792.
18. Okai LA, Kohn AF. Quantifying the Contributions of a Flexor Digitorum Brevis Muscle on Postural Stability. *Motor Control.* 2015;19(3):161–72.

### Author biography

**Archishnu Vedanta Parida**, Tutor

**Devendra Pal Singh**, Tutor

**Sipra Rout**, Associate Professor  <https://orcid.org/0000-0002-1705-9469>

**Cite this article:** Parida AV, Singh DP, Rout S. A case report on the bilateral absence of fourth tendinous slip of the flexor digitorum brevis muscle in the foot: Exploring evolutionary and surgical relevance. *Indian J Clin Anat Physiol* 2023;10(4):261-264.