

Content available at: <https://www.ipinnovative.com/open-access-journals>

Indian Journal of Clinical Anatomy and Physiology

Journal homepage: <https://www.ijcap.org/>**Short Communication****Craniosynostosis with scaphocephaly-embryological basis and clinical relevance****Mouna Subbaramaiah^{1,*}, Vyshak B N¹**¹Dept. of Anatomy, Kempegowda Institute of Medical Sciences, Bengaluru, Karnataka, India**ARTICLE INFO***Article history:*

Received 18-09-2023

Accepted 30-09-2023

Available online 21-10-2023

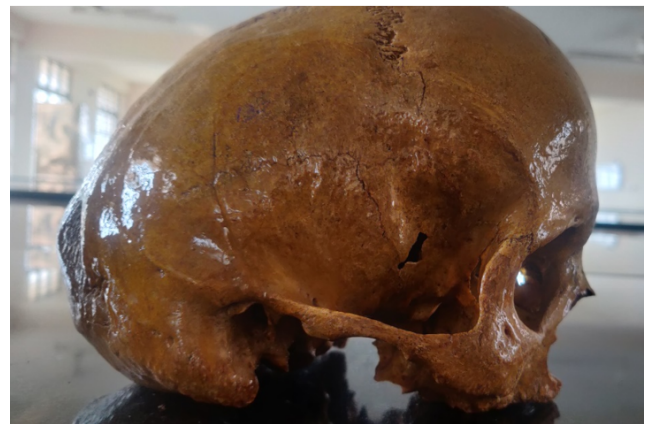
This is an Open Access (OA) journal, and articles are distributed under the terms of the [Creative Commons Attribution-NonCommercial-ShareAlike 4.0 License](https://creativecommons.org/licenses/by-nc-sa/4.0/), which allows others to remix, tweak, and build upon the work non-commercially, as long as appropriate credit is given and the new creations are licensed under the identical terms.

For reprints contact: reprint@ipinnovative.com

Since ancient times, people have been aware of the skull's odd form. An aberrant form of the skull results from cranial synostosis, which is the early pathologic union of one or more cranial vault sutures. The fused sutures result in uneven bossing in some regions and limited development in others. The location and timing of the improperly fused suture will determine the shape of the skull.¹ Craniosynostosis is an uncommon congenital disorder that affects one in 1800–2000 newborns. Additionally, males are three times more prone than girls to acquire sagittal synostosis.² Scaphocephaly, which is caused by an early closure of the sagittal suture and causes the skull to resemble a boat because the calvarium continues to expand in the antero-posterior direction while growing less in the transverse direction, is the outcome. Depending on the condition, such as Apert, Crouzon, Carpenter, Pfifer, etc., the craniosynostosis may emerge as an isolated rare occurrence or as an associated event. In syndromic situations, several sutures are implicated.³ It can occur in conjunction with block vertebra or spinal synostosis.⁴

Hereby reporting a case of cranial synostosis involving the sagittal suture found in a museum specimen of Kempegowda institute of medical sciences. The calvaria of the skull was oval. The vault had a moderately sloping forehead and frontal bossing, and it was reasonably long and thin. The cranium roof was clearly curved in the back, falling to the occipital squama. The occipital plane

was almost perpendicular to the cranial base, significantly longer than the nuchal plane. The occiput was posteriorly somewhat protuberant. The lambdoid suture was hardly discernible but was still there. On both sides of the calvaria, the temporal lines were clearly defined, and the squama of the temporal bone was substantial. The bony face was very slender. This skull was distinguished by its alveolar prognathism and bilaterally well-marked maxillary incisure. The nasal cavity looked to be considerably deeper, and the nasal bones were more convex. The upper rim of the orbit was projecting. (Figures 1, 2 and 3)

**Fig. 1:** Lateral view

* Corresponding author.

E-mail address: msjkims@gmail.com (M. Subbaramaiah).



Fig. 2: Superior view

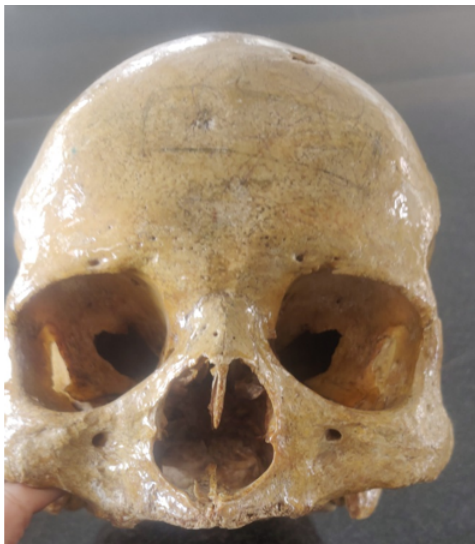

Fig. 3: Frontal view

The embryonic skull starts to grow nine weeks after fertilization. At nine weeks, the base of the skull has developed along with the sphenoidal wings, cribriform plates, dural attachment to crista galli, and petrous ridges. Early brain growth occurs at these locations, which dural bands reflect off of. By 12 weeks, ossification had taken place in the dura mater region between the main bands. Bone extends in all directions toward the dura from these core locations. By 16 weeks, the development has almost completely covered the main dura bands, but fontanelles are still present where the bone growth has not yet reached.

These unossified areas are crucial for the flexibility of the skull during birthing. In the end, the development of sutures is a reaction to the overlapping radial growth patterns of bone from central locations rather than being explicitly influenced by genetics. They arise from internal pressures that affect the normal development of the skull and brain.⁵

Cranial sutures are essential for the correct development of the skull. Premature closure of the cranial sutures alters the contour of the cranial vault by causing general or localized deformation of the skull.⁶

'Z-pattern' synostosis (left coronal, right sagittal, and bilateral lambdoid),⁷ synostosis of the sagittal suture that extended over the occipital bone, or the Mercedes-Benz pattern of synostosis are all examples of synostoses.⁸ It is recognized that each of the aforementioned craniosynostoses alters the contour of the skull. It is still debatable what causes sutures to close too soon. The etiology of craniosynostosis has been linked to genetically determined local growth factor expression and biomechanical stresses.⁹

Delashaw et al. provide a further explanation of compensatory growth by identifying four key variables.

1. Premature fusion of the cranial vault bones results in a single bone plate with reduced growth potential.
2. Excessive bone deposition directed away from the bone plate occurs at perimeter sutures in an abnormally asymmetric manner.
3. Perimeter sutures farthest from the sutural stenosis compensate for growth more than perimeter sutures adjacent to the prematurely fused suture.
4. The margins of a non-perimeter suture that is next to the prematurely fused suture have improved symmetric bone deposition.⁶

Surgery is required for both aesthetic and practical reasons. Increased intracranial pressure, which has detrimental effects on the brain and eyesight in many situations, may be involved. The purpose of therapy is to remodel the skull and enhance cranial volume. In the majority of instances, the procedure may be performed without risk in 9 to 12 months. The traditional method of therapy involves open surgery; however certain facilities have reported outstanding outcomes when using restricted endoscopic procedures in some situations.³

Single suture synostosis is treated using a relatively novel adjunct that involves spring-assisted gradual active bone movement. The most frequent use has been to treat sagittal synostosis.¹⁰

The above article deals with the aetiopathogenesis, presentation and management of craniosynostoses and is an eye-opener for detection of the same to early intervention and prevention of complications.

1. Conflict of Interest

None.

References

1. Dimopoulos VG, Kapsalakis IZ, Fountas KN. Skull morphology and its neurosurgical implications in the Hippocratic era. *Neurosurg Focus*. 2007;23(1):E10.
2. Noggle CA, Dean RS, Horton AM. The Encyclopedia of Neuropsychological Disorders. Springer Publishing; 2012. p. 238–9.
3. Sharma RK. Craniosynostosis. *Indian J Plast Surg*. 2013;46(1):18–27.
4. Mouna S, Archana R, Jagannatha SR. A Case Series of Synostosis/Blocks Observed in Indian Human Vertebra: Clinical and Developmental Perspective. *Natl J Clin Anat*. 2023;12(1):50–4.
5. Smith DW, Töndury G. Origin of the calvaria and its sutures. *Am J Dis Child*. 1978;132(7):662–6.
6. Delashaw JB, Persing JA, Broaddus WC, Jane JA. Cranial vault growth in craniosynostosis. *J Neurosurg*. 1989;70(2):159–65.
7. Schmelzer RE, Fearon JA. 'Z-pattern' craniosynostosis: a novel presentation of trisutural fusion. *J Craniofac Surg*. 2007;18(3):568–74.
8. Rhodes JL, Kolar JC, Fearon JA. Mercedes Benz pattern craniosynostosis. *Plast Reconstr Surg*. 2010;125(1):299–304.
9. Persing JA, Jane JA, Shaffrey M. Virchow and the pathogenesis of craniosynostosis: A translation of his original work. *Plast Reconstr Surg*. 1989;83:738–42.
10. Lauritzen C, Sugawara Y, Kocabalkan O, Olsson R. Spring mediated dynamic craniofacial reshaping. Case report. *Scand J Plast Reconstr Surg Hand Surg*. 1998;32(3):331–8.

Author biography

Mouna Subbaramaiah, Professor

Vyshak B N, MBBS Student

Cite this article: Subbaramaiah M, Vyshak B N. Craniosynostosis with scaphocephaly-embryological basis and clinical relevance. *Indian J Clin Anat Physiol* 2023;10(3):197-199.