

Content available at: <https://www.ipinnovative.com/open-access-journals>

Indian Journal of Clinical Anatomy and Physiology

Journal homepage: <https://www.ijcap.org/>

Original Research Article

Morphometric analysis of adult human mandible and their ratios

Neeta Gautam Shroff^{1,*}, Shamama Shaikh¹, Gautam A Shroff¹, Vaishali Mandhana¹, Sana Khan¹¹Dept. of Anatomy, MGM Medical College, Aurangabad, Maharashtra, India

ARTICLE INFO

Article history:

Received 23-07-2023

Accepted 16-08-2023

Available online 21-10-2023

Keywords:

Mandible

Morphometric

Inferior alveolar nerve

Reconstruction

Evolution

ABSTRACT

Background: Mandible is the strongest bone in the face region required for the process of mastication. The inferior alveolar nerve travels inside the bone in the mandibular canal to supply the lower teeth. The measurement of various parameters of mandible allows the proper localisation of nerve for anaesthetic block. Also, the ratios between factors assists during surgeries.

Materials and Methods: A cross-sectional observational study was conducted on 97 dry adult human mandibles. Height of symphysis menti, ramus breadth and height, and distance of mandibular foramen from mandibular notch and base of mandible of both sides are measured. Ratios between ramus height and breadth and distances of mandibular foramen from above mentioned landmarks were computed.

Results: The mean height of symphysis menti was found to be 25.52 ± 4.32 mm. The mean values of height of ramus on right side was 46.18 ± 4.43 mm and on left was 46.57 ± 4.24 mm. The mean breadth of ramus was 32.29 ± 3.57 mm (right side) and 32.59 ± 3.75 mm (left side). It was found that mandibular foramen was closer to the mandibular notch than to the base of mandible on both sides. The ratios between the right and left side showed no significant differences.

Conclusion: Inferior alveolar nerve block is required in various dental procedures for which mandibular foramen localisation is must. Dimensions of mandible help in surgical restructuring. Similarly, it aids in understanding the evolution of the bone.

This is an Open Access (OA) journal, and articles are distributed under the terms of the [Creative Commons Attribution-NonCommercial-ShareAlike 4.0 License](https://creativecommons.org/licenses/by-nc-sa/4.0/), which allows others to remix, tweak, and build upon the work non-commercially, as long as appropriate credit is given and the new creations are licensed under the identical terms.

For reprints contact: reprint@ipinnovative.com

1. Introduction

Mandible is the strongest and the only moveable bone in the face region. The movement of mandible occurs at the temporomandibular joint on each side by muscles of mastication that is – Masseter, Temporalis, Medial and Lateral Pterygoids. Over the years as Homosapiens changed their eating habits from raw to cooked food, the mandible has also evolved. Posture, locomotion and mastication are basic evolutionary factors which has changed the external and internal mandibular features.¹ These modifications include alteration in the location of temporal region and

increase in breadth of the lower jaw. Mandible is one of the few human bones that entraps a nerve within its body. The inferior alveolar nerve passes through the mandibular foramen present on the medial wall of the ramus of the mandible, passes through the mandibular canal, and exits as a mental nerve from the mental foramen present on the outer surface of the body of the mandible. Susan Standing et al. have stated that Meckel's cartilage around the inferior alveolar nerve develops into the mandible. "Each half of mandible develops from centers that appear near mental foramen at 6th week of intra-uterine life whereas condylar and coronoid process develop from secondary cartilages."² In this study, we have measured the distance of various landmarks on 97 adult human mandibles and analyzed

* Corresponding author.

E-mail address: neetagshroff@gmail.com (N. G. Shroff).

variations and their proportions. The ratios between ramus height and breadth and distance of mandibular foramen from superior and inferior margins are useful for surgical correction of prognathism.

2. Materials and Methods

A total of 97 dry human adult mandibles of unknown sex were studied after the approval of Institutional Ethical Committee of the following number: MGM-ECRHS/2023/102

2.1. Inclusion criteria

1. Human mandible
2. Adult mandible

2.2. Exclusion criteria

1. Mandible showing fracture line are excluded.
2. Deformed mandibles are excluded.
3. Mandible of children and elderly are excluded on morphological basis.

This study is cross-sectional observational study. Measurement of the parameters listed below on the mandible was done using a digital sliding vernier calliper.

1. Height of symphysis menti: Perpendicular distance from the lower margin of body to lowest point on alveolar margin of incisor teeth in millimetres
2. Distance of mental foramen from the upper alveolar margin in millimetres (MFU).
3. Distance of mental foramen from the lower margin of body of mandible in millimetres (MFL).
4. Height of ramus of mandible: Perpendicular distance from midpoint of mandibular notch to inferior margin of ramus in millimetres (RH).
5. Breadth of ramus of mandible: Smallest perpendicular antero-posterior distance of ramus passing through mandibular foramen in millimetres (RB).
6. Perpendicular distance of the superior margin of mandibular foramen from the midpoint of mandibular notch in millimetres (MANU)
7. Perpendicular distance of inferior margin of mandibular foramen from the lower margin of body of ramus in millimetres (MANL).

Statistical analysis was carried out using Microsoft Office Excel 2021 and SPSS 22.

3. Results

The mean, standard deviation and minimum – maximum values (in mm) of various parameters have been displayed in Table 1. It was found that there was no significant difference in the right and left side values.

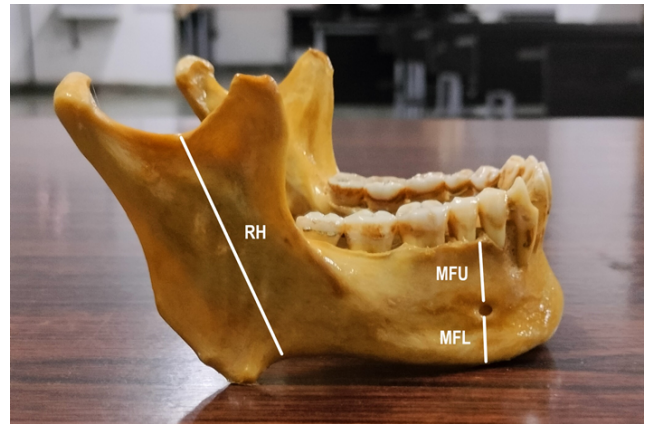


Fig. 1: Measurement of RH, MFU and MFL

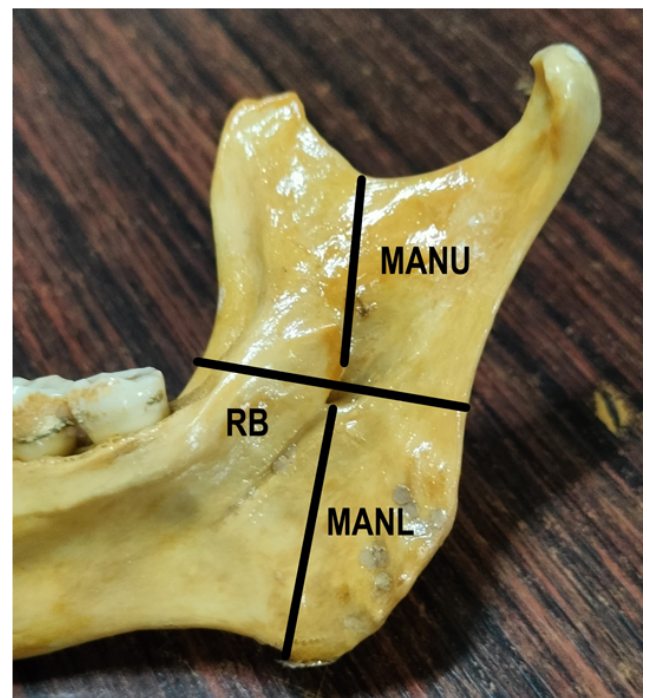


Fig. 2: Measurement of RB, MANU and MANL

The mean height of symphysis menti was found to be 25.52 ± 4.32 mm. The mean values of height of ramus on right side was 46.18 ± 4.43 mm and on left was 46.57 ± 4.24 mm. The mean breadth of ramus was 32.29 ± 3.57 mm on right side and 32.59 ± 3.75 mm on left side.

The superior margin of mandibular foramen was situated 16.29 ± 2.31 mm (right side) and 16.47 ± 2.34 mm (left side) from the midpoint of mandibular notch. The inferior margin of mandibular foramen was located 23.71 ± 3.90 mm (right side) and 24.06 ± 4.16 mm (left side) from the lower margin of body of ramus.

The Skewness and Kurtosis of the various parameters are given in Table 2. It was found that values of the parameters

Table 1: Mean, SD and Min.-Max.values of various parameters

Parameter	Side	Mean (mm)	Standard Deviation (mm)	Min. – Max. (mm)
Symphysis menti	-	25.52	4.32	11.69 – 35.15
MFU	Right	12.33	2.31	8.36 – 18.94
	Left	11.96	2.29	8.47 – 19.55
MFL	Right	11.92	1.52	7.94 – 15.39
	Left	12.08	1.58	8.86 – 15.92
RH	Right	46.18	4.43	28.48 – 54.35
	Left	46.57	4.24	34.99 – 59.44
RB	Right	32.29	3.57	23.61 – 41.92
	Left	32.59	3.75	21.52 – 42.46
MANU	Right	16.29	2.31	11.97 – 22.59
	Left	16.47	2.34	11.58 – 21.36
MANL	Right	23.71	3.90	14.57 – 32.78
	Left	24.06	4.16	9.27 – 34.27

MFU, MFL and MANU of both sides and RB (right side) and MANL (right side) are positively skewed. Whereas, values of height of symphysis menti, RH on both sides and RB (left side) and MANL (left side) are negatively skewed. According to coefficient of Kurtosis of the values of all parameters, the frequency curve is platykurtic.

Table 2: Skewness and Kurtosis of various parameter values

Parameter	Side	Skewness	Kurtosis
Symphysis menti	-	- 0.300	0.213
MFU	Right	0.580	-0.190
	Left	0.675	0.090
MFL	Right	0.112	-0.485
	Left	0.026	-0.379
RH	Right	-0.907	1.735
	Left	-0.085	0.349
RB	Right	0.267	0.294
	Left	-0.056	0.270
MANU	Right	0.206	-0.242
	Left	0.040	-0.633
MANL	Right	0.078	-0.130
	Left	-0.644	1.499

The mean ratios and their standard deviation between RH and RB and MANU and MANL of both sides have been tabulated in Table 3. The mean ratio of RH/RB on right was 1.441 ± 0.170 and on left was 1.442 ± 0.174 . The mean ratio of MANL/MANU was 1.487 ± 0.348 (right side) and 1.485 ± 0.325 (left side). It was found that ratios of right and left side show no significant differences.

Table 3: Mean and SD of ratios

Parameter	Side	Mean	SD
RH/RB	Right	1.441	0.170
	Left	1.442	0.174
MANL/MANU	Right	1.487	0.348
	Left	1.485	0.325

4. Discussion

The temporomandibular joint is a unique joint in mammals which has evolved over years beginning its development from the mammal-like reptiles.³ It has been found that insertion of jaw closing musculature in mammal-like reptiles has slowly changed their orientation leading to reduced force on the joint during contraction of said muscles. Reduction in force over jaw joint supplemented the increase in strength of bite.⁴

No significant differences were found in the values of right and left side of parameters which is uniform with previous studies.^{5–10}

The mean distance between the mandibular notch and mandibular foramen was 16.29 ± 2.31 mm (right side) and 16.47 ± 2.34 mm (left side) which is consistent with the findings of an East European study on 125 mandibles with the values as 17.41 ± 3.22 mm (right) and 18.01 ± 3.44 mm.⁵ However, the findings of some previous studies (B. Matundu et al.,⁶ Varsha Shenoy et al.,⁷ Md. Mesbahul Hoque et al.⁸ are different than the present study.

The distance of inferior border of mandibular foramen from mandibular base was 23.71 ± 3.90 mm (right side) and 24.06 ± 4.16 mm (left side) in this study which is consistent with Varsha Shenoy et al.⁷ and Shalini et al.⁹ The present study concludes that mandibular foramen is closer to the mandibular notch than the base of mandible which is coherent with B. Matundu et al.,⁶ Shalini et al.⁹ Tshite et al.¹⁰

This accurate localization of mandibular foramen is necessary for adequate anaesthesia in dental procedures.

Since the ratios on both sides had no significant differences, they are useful for mandibular prognathism surgical correction by surgeries like bilateral sagittal split osteotomy and vertical ramus osteotomy.

On the evolutionary aspect, the result for mean height of symphysis menti in this study involving modern human was 25.52 ± 4.32 mm which less than the symphysial height

found in the mandibular remains of early human species as determined by Hertha De Villiers et al.¹¹ (34mm), Tuinplaas et al.¹² (40mm) and Otjiseva et al.¹³ (37mm) indicating the presence of larger mandibles in the early human species.

5. Conclusion

Since a few studies have shown that mandibular foramen through which the inferior alveolar nerve passes maintains its location after skeletal maturity.^{14,15}

It is of utmost importance to know its position for adequate inferior alveolar nerve block and for a successful dental procedure.

The ratios calculated between the mandibular parameters are essential for corrective osteotomies. Evaluation of mandibular parameters is necessary for anthropological studies and a better understanding of the evolution of man.

6. Source of Funding

None.


7. Conflict of Interest

None.

References

1. Delaire J. The evolution of the lower jaw and the jaw joint, from reptiles to man. *Rev Stomatol Chir Maxillofac.* 1998;99(1):3–10.
2. Standring S. *Gray's Anatomy: The Anatomical Basis of Clinical Practice.* 41st ed. Netherlands: Elsevier; 2016. p. 539.
3. Kermack KA. Evolution of Mammalian Dental Structures. *Proc Roy Soc Med.* 1972;65:389–92.
4. Crompton AW. The Evolution of the Mammalian Jaw. *Evolution.* 1963;17(4):431–9.
5. Jain N, Kažoka D, Jain S, Pilmane M. Anatomical variations in position of mandibular foramen: An East European morphometric study in dry adult human mandibles for achieving a successful inferior alveolar nerve block. *Ital J Anat Embryol.* 2019;124:392–402.
6. Mantundu B, Adefolaju GA, Manda J. A morphometric study of the mandibular foramen in dry adult human mandibles in a black Malawian population. *Int J Morphol.* 2021;39(2):390–5.
7. Shenoy V, Vijayalakshmi S, Saraswathi P. Osteometric Analysis of the Mandibular Foramen in Dry Human Mandibles. *J Clin Diagn Res.* 2012;6(4):557–60.
8. Hoque M, Ara S, Begum S, Kamal A, Momen A. Study of Morphometric Analysis of Mandibular Foramen in Bangladeshi Dry Adult Human Mandible. *Bangladesh J Anat.* 2013;11(2):58–61.
9. Shalini R, Ravivarman C, Manoranjitham R, Veeramuthu M. Morphometric study on mandibular foramen and incidence of accessory mandibular foramen in mandibles of south Indian population and its clinical implications in inferior alveolar nerve block. *Anat Cell Biol.* 2016;49(4):241–8.
10. Tshite K, Faculty of Health Sciences, University of the Witwatersrand, Johannesburg. Location of Mandibular foramen on Mandibles of adult black South African population: a morphometric analysis and investigation into possible radiographic correlation; 2017. Available from: <https://wiredspace.wits.ac.za/server/api/core/bitstreams/8ee0e2f4-5d8d-4067-b78f-9b6384f4883e/content>.
11. DeVilliers H. A Second Adult Human Mandible from Border Cave, Ingwavuma District, KwaZulu, South Africa. *S Afr J Sci.* 1976;72:212–5.
12. Tobias PV. Human skeletal remains from the cave of Hearths, Makapansgat, Northern Transvaal. *Amer. Am J Phys Anthropol.* 1971;34(3):335–67.
13. DeVilliers H. The first fossil human skeleton from South West Africa. *Trans R Soc S Afr.* 1972;40:187–96.
14. Afsar A, Haas DA, Rossouw PE, Wood RE. Radiographic localization of mandibular anesthesia landmarks. *Oral Surg Oral Med Oral Pathol Oral Radiol Endod.* 1998;86(2):234–41.
15. dePocobello CPL, deCampos M, Pereira RSS. Contribuição ao estudo da posição do forame mandibular nas radiografias panorâmicas / A comparation of the position of the mandibular foramen, in panoramic radiographs and dry skulls. *Arq Odontol.* 2003;39(1):45–52.

Author biography

Neeta Gautam Shroff, Assistant Lecturer  <https://orcid.org/0009-0000-7696-6379>

Shamama Shaikh, Assistant Professor

Gautam A Shroff, Professor and HOD

Vaishali Mandhana, Associate Professor

Sana Khan, Assistant Lecturer

Cite this article: Shroff NG, Shaikh S, Shroff GA, Mandhana V, Khan S. Morphometric analysis of adult human mandible and their ratios. *Indian J Clin Anat Physiol* 2023;10(3):153-156.