

Content available at: <https://www.ipinnovative.com/open-access-journals>

Indian Journal of Clinical Anatomy and Physiology

Journal homepage: <https://www.ijcap.org/>

## Short Communication

# A novel insight towards classification of joints

Payal Arvind Kasat<sup>1,\*</sup>, Ranjan Pampi<sup>2</sup>, Gayatri Muthiyan<sup>3</sup>

<sup>1</sup>Dept. of Anatomy, Dr B C Roy Multi Speciality Medical Research Centre, Kharagpur, West Bengal, India

<sup>2</sup>Dept. of Anatomy, Topiwala National Medical College, Mumbai, Maharashtra, India

<sup>3</sup>Dept. of Anatomy, All India Institute of Medical Sciences, Nagpur, Maharashtra, India



### ARTICLE INFO

#### Article history:

Received 13-04-2023

Accepted 14-06-2023

Available online 08-07-2023

#### Keywords:

Cartilaginous joint

Articulation

### ABSTRACT

A joint or articulation or articular surface is the connection made between bones in the body. They link the skeletal system to allow for different degrees and types of movement. Joints are classified both structurally and functionally. The short communication aims to initiate an innovative classification of joint on the basis of general morphology as follows: 1. Simple (one pair of articulating surfaces; male and female): e.g. Fibrous joint: Metopic suture between two frontal bones, sagittal suture between two parietal bones; Cartilaginous joint: Synchondroses: manubriosternal joint, occipitospheoid joint; Symphyses: pubic symphysis, intervertebral discs, symphysis menti; Synovial joint: interphalangeal joint, first carpometacarpal joint, shoulder joint, sacroiliac joint; and 2. Compound (more than one pair of surfaces): e.g. Fibrous joint: Coronal suture between one frontal and two parietal bones; Cartilaginous joint: ends of the long bones with multiple secondary centres of ossification which fuse later (epiphysis) can be technically considered as compound cartilaginous joints during developmental phase; Synovial joint: elbow joint, wrist joint, knee joint etc.

This is an Open Access (OA) journal, and articles are distributed under the terms of the [Creative Commons Attribution-NonCommercial-ShareAlike 4.0 License](https://creativecommons.org/licenses/by-nc-sa/4.0/), which allows others to remix, tweak, and build upon the work non-commercially, as long as appropriate credit is given and the new creations are licensed under the identical terms.

For reprints contact: [reprint@ipinnovative.com](mailto:reprint@ipinnovative.com)

## 1. Introduction

A joint or articulation or articular surface is the connection made between bones in the body.<sup>1</sup> They link the skeletal system into a functional whole. They are constructed to allow for different degrees and types of movement. Some joints, for example the knee, elbow and shoulder, are self-lubricating, almost frictionless. They are able to withstand compression and maintain heavy loads while still executing smooth and precise movements.<sup>2</sup> Other joints such as sutures between the bones of the skull permit very little movement (only during birth) in order to protect the brain and the sense organs.<sup>2</sup> The connection between a tooth and the jaw bone is also called a joint. It is described as a fibrous joint known as gomphosis or peg and socket joint. Joints are

classified both structurally and functionally.<sup>3</sup>

## 2. Aim

The short communication aims to initiate an innovative classification of joint on the basis of general morphology.

## 3. Classification of Joints

The standard textbooks in Anatomy<sup>4,5</sup> clearly classify Synovial joints according to General Morphology into:

1. Simple (one pair of articulating surfaces; male and female): For example, interphalangeal joint, shoulder joint etc.
2. Compound (more than one pair of surfaces): For example, elbow joint, wrist joint, knee joint etc.
3. Complex (with intracapsular meniscus or disc).

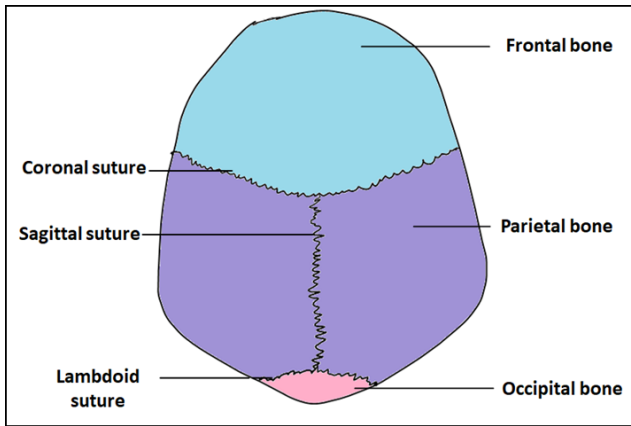
\* Corresponding author.

E-mail address: [payalk554@yahoo.com](mailto:payalk554@yahoo.com) (P. A. Kasat).

However, this classification should not be restricted only to synovial joints. It should also accommodate the fibrous and cartilaginous joints. Thus, Classification of joints according to general morphology should be as follows:

### 3.1. Simple (one pair of articulating surfaces; male and female : For e.g

Fibrous joint: Metopic suture between two frontal bones, sagittal suture between two parietal bones (Figure 1)



**Fig. 1:** Illustration showing coronal suture (compound fibrous joint), sagittal suture (simple fibrous joint) and lambdoid suture (compound fibrous joint)

Cartilaginous joint:

1. Synchondroses: manubriosternal joint, occipitospheroid joint.
2. Symphyses: pubic symphysis, intervertebral discs, symphysis menti.

Synovial joint: interphalangeal joint, first carpometacarpal joint, shoulder joint, sacroiliac joint

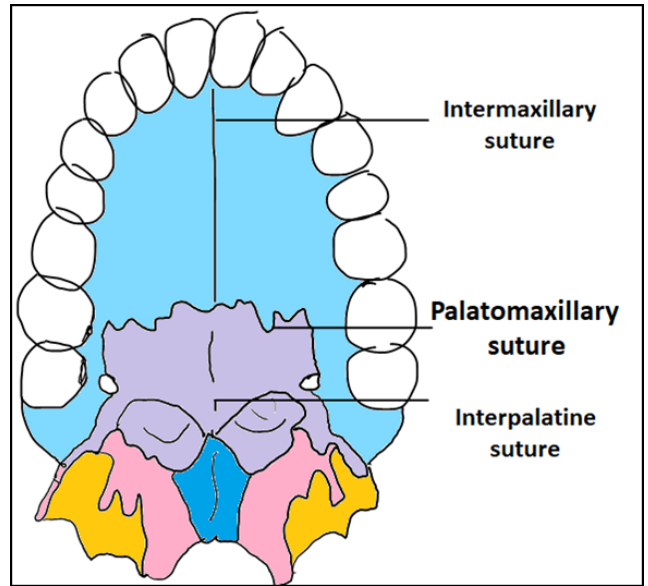
### 3.2. Compound (more than one pair of surfaces : For e.g

Fibrous joint: (Figures 1 and 2)

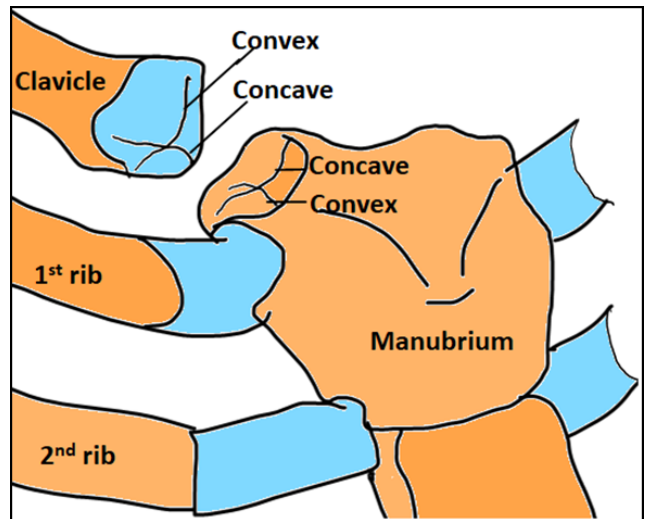
1. Coronal suture between one frontal and two parietal bones,
2. Lambdoid suture between two parietal and one occipital bone,
3. Palatomaxillary suture between horizontal plates of palatine bone and palatine processes of maxillary bone.

Cartilaginous joint: ends of the long bones with multiple secondary centers of ossification which fuse later (epiphysis) can be technically considered as compound cartilaginous joints during developmental phase.

Synovial joint: elbow joint, wrist joint, knee joint etc.



**Fig. 2:** Illustration showing palatomaxillary or cruciform suture (compound fibrous joint)



**Fig. 3:** Illustration showing Sternoclavicular joint (compound cartilaginous joint)

Mixed: Sternoclavicular joint or articulation<sup>6</sup>(Figure 3)

The bone areas entering in its formation are the sternal end of clavicle, clavicular notch of sternum and the cartilage of the first rib. The cartilage of the first rib is visible from the outside as the suprasternal notch. Structurally this is a saddle variety of synovial joint. Functionally this is diarthrosis and multiaxial joint.

## 4. Conclusion

An innovative classification of joints on the basis of general morphology could be included in the medical

curriculum considering the uniformity it imparts to the overall understanding of joints and their classification.

## 5. Conflict of Interest

The authors have none to declare.

## Acknowledgments

I would like to thank the Occupational Therapy and Physiotherapy students of Dr. D. Y. Patil Medical College, Nerul, Navi Mumbai who raised queries regarding classification of joint which lead to this innovative insight.

## References

1. Whiting WC, Rugg S. *Dynatomy: Dynamic Human Anatomy*. 2nd ed. Champaign, IL: Human Kinetics Inc; 2006. p. 46–51.
2. Saladin K. *Anatomy & Physiology: The Unity of form and function*. 7th ed. McGraw-Hill Education; 2014.
3. Edinburg S. *The Anatomical Basis of Clinical Practice*. In: Gray's Anatomy. Edinburgh: Elsevier Churchill Livingstone; 2006.
4. American Psychological Association. Available from: <http://www.dictionary.com/browse/compound-joint>.
5. Williams PL, Warwick R, Dyson M, Bannister LH. Nomenclature of Joints. In: *Arthrology: Gray's Anatomy*. Edinburgh: Elsevier Churchill Livingstone; 1989. p. 463.
6. Lippert LS. *Clinical Kinesiology and Anatomy*. 4th ed. United States: F.A. Davis Company; 2006. p. 95–6.

## Author biography

**Payal Arvind Kasat**, Assistant Professor

**Ranjan Pampi**, Assitant Professor

**Gayatri Muthiyan**, Associate Professor

**Cite this article:** Kasat PA, Pampi R, Muthiyan G. A novel insight towards classification of joints. *Indian J Clin Anat Physiol* 2023;10(2):127-129.