

Content available at: <https://www.ipinnovative.com/open-access-journals>

Indian Journal of Clinical Anatomy and Physiology

Journal homepage: <https://www.ijcap.org/>

## Case Report

# Persistent median artery with absence of superficial palmar arch- Case report

Amit Purushottam Tirpude<sup>1</sup>, Rahul K Ukey<sup>1</sup>, Urvi Sharma<sup>1,\*</sup>

<sup>1</sup>Dept. of Anatomy, All India Institute of Medical Sciences, Raipur, Chhattisgarh, India



### ARTICLE INFO

#### Article history:

Received 06-05-2023

Accepted 27-05-2023

Available online 08-07-2023

#### Keywords:

Palmar arch

Persistent median artery

### ABSTRACT

Variations in the vascular supply of palm is commonly described. While regular cadaveric dissection of undergraduate students one such variation was reported in our college is the persistent median artery with absent superficial palmar arch. Palm arterial supply is by both palmar arches (superficial and deep). In our study, the ulnar and median arteries supply the palm of the cadaver's right extremity without forming an arch. Awareness of arterial supply of the palm is essential in surgical emergencies and procedures related to angiography.

This is an Open Access (OA) journal, and articles are distributed under the terms of the [Creative Commons Attribution-NonCommercial-ShareAlike 4.0 License](https://creativecommons.org/licenses/by-nc-sa/4.0/), which allows others to remix, tweak, and build upon the work non-commercially, as long as appropriate credit is given and the new creations are licensed under the identical terms.

For reprints contact: [reprint@ipinnovative.com](mailto:reprint@ipinnovative.com)

## 1. Introduction

The structural diversity in the vasculature of the upper limb are frequent and have been previously documented by a number of researchers.<sup>1,2</sup> The majority of upper limb vascular abnormalities are caused by deviations in RA from its typical pattern in terms of its emergence.<sup>3</sup> This type of variations can restrain therapeutic, and surgical procedures.<sup>4</sup> It has been reported that 2.4% to 14.3% of upper extremities have high emergence of RA, which is described as the RA coming from brachial or axillary artery (AA) close to the antecubital fossa.<sup>5,6</sup>

Superficial palmar arch is formed by ulnar and radial artery (superficial branches). Significant variation is seen in the branching pattern and emergence of SPA in the hand. The SPA has been classified as complete or incomplete based on the presence or absence of anastomosis between the arteries that contribute to the formation of this palmar arch.<sup>7</sup> In an incomplete superficial palmar arch, there is no anastomosis between the radial and ulnar artery, preventing it from reaching the thumb and index finger.

Incomplete superficial palmar arches can be classified into four categories, according to Coleman et al.<sup>8</sup> Type A occurs in 3.6% instances, it is characterised by superficial branches of radial and ulnar arteries reaching the hand, but failing to form an anastomosis with one another, supplying the fingers and palm separately. In type B (13.4%), ulnar artery forms the SPA, but, thumb and index finger are not supplied by it. Type C (3.8%) is formed by both ulnar and the median arteries, but there is absence of anastomosis between the two. In type D (1.1%), blood supply to fingers and palm is provide by the median, radial and the ulnar artery but no anastomosis is seen between these vessels.

In addition to an incomplete SPA and higher origin of radial artery on one side, a persisting median artery was also found in the corpse. The median artery supplies hand and forearm throughout gestation and normally subsides before 8th week of embryonic period. However, in adults, median artery may persist and may cause complications like carpal tunnel and pronator teres syndrome.<sup>9</sup>

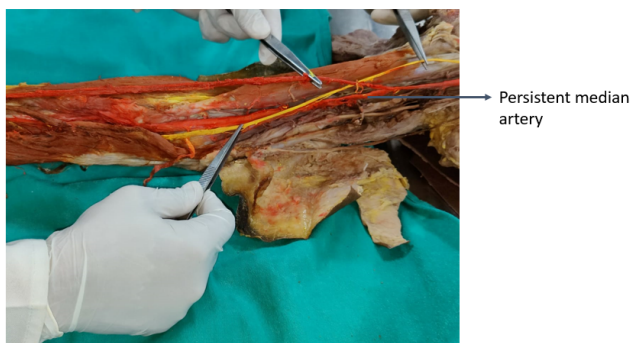
Understanding the differences in vascular supply of the hand is critical in the approach for surgeries like composite tissue transplants and revascularisation.<sup>10</sup>

\* Corresponding author.

E-mail address: [urvisharma75@gmail.com](mailto:urvisharma75@gmail.com) (U. Sharma).

## 2. Case Report

During a routine dissection of upper limb in 45 year old formalin fixed cadaver of male variation encountered was an incomplete superficial palmar arch with persistent unilateral median artery along with the variations in the radial artery in right hand of cadaver (Figure 1) Origin of radial artery was from brachial artery at upper level i.e. at a distance of 19 cm from the head of radius. The radial artery was running superficially to the biceps and then passes between biceps and brachioradialis. In the forearm it runs laterally and was going superficial to the flexor tendons. Length of radial artery in the forearm was 24 cm. At the wrist, radial artery turned in lateral direction and terminates by entering in the floor of anatomical snuff box. The median artery emerge from the common interosseous artery and distance measured from head of radius was 2 cm and it runs on the medial aspect of the forearm superficial to the flexor tendons and terminates by supplying lateral 1.5 digits. In the forearm length of median artery was 22 cm. Superficial palmar arch on the lateral aspect of hand is formed by median artery, length of median artery measured in forearm was 2.5 cm from the flexor retinaculum. On the medial aspect ulnar artery formed the superficial palmar arch but these arteries are not anastomosing thus forming the incomplete superficial palmar arch (Figure 2). Also, higher origin of brachioradialis was noted.

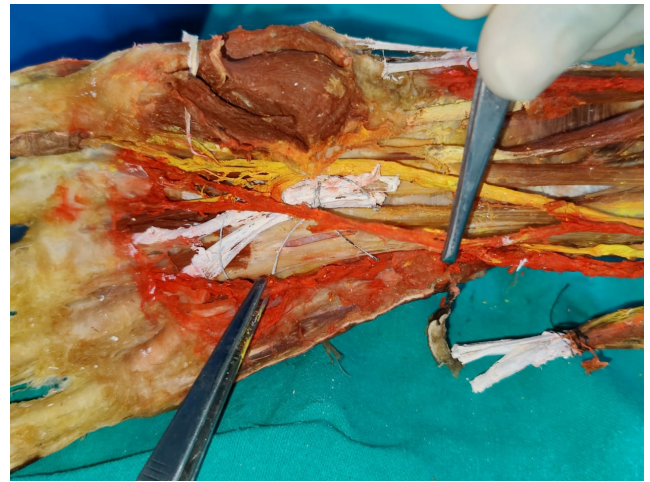


**Fig. 1:** Median artery emerging from common interosseous artery

## 3. Discussion

The superficial palmar arch is found underneath the palmar aponeurosis and is superficial to the branches of median nerve and long flexor tendons. The prevalence of incomplete superficial palmar arch ranges between 3.6% and 54.76%.<sup>11</sup>

Superficial palmar arch is categorised into two types complete and incomplete.<sup>12</sup> In complete palmar arch anastomosis is present between the vessels while in incomplete palmar arch, no anastomosis between the vessels is seen.<sup>13</sup> In the present report median and ulnar artery are not anastomosing with each other which results in incomplete palmar arch. Ikeda et al. classified palmar arch



**Fig. 2:** Incomplete superficial palmar arch

into 4 types A, B, C and D.<sup>14</sup> In our study type C incomplete superficial palmar arch was seen median ulnar type and its incidence reported is 0.9%. It is made up of the ulnar artery's terminal segment and the remaining median artery. According to Coleman and Anson complete arch was seen in 78.5% cases and incomplete in 21.5% cases.<sup>11</sup> In our report superficial palmar arch can be labelled as group 2 (Incomplete superficial palmar arch) and type C (Median and ulnar arteries were present but they were not anastomosing). The incidence of median artery ranges from 1.5% to 27.1%.<sup>15,16</sup> The median artery can be derived from ulnar, radial and interosseous artery.<sup>16</sup> In the present study median artery was originating from the interosseous artery. Median artery terminates either in palmar or antebrachial pattern.<sup>13</sup> In antebrachial type it is short, thin and conclude before reaching the wrist while in palmar type it is long, larger in size and reaches the palm.<sup>13</sup> In our study, median artery was palmar type. The origin of antebrachial type is from interosseous artery and its incidence is 70-100% while origin of palmar type is from common interosseous trunk.<sup>13</sup> The median artery is the upper extremity's axis vessel during early embryonic development. It supports the superficial palmar arch during the development of radial and ulnar arteries.<sup>17</sup> The perseverance of the median artery is interpreted as the maintenance of primordial arterial pattern whereas the antebrachial pattern constitute its partial decline.<sup>18</sup>

The clinical significance of median artery persistence at wrist level is well reported as a source of carpal tunnel syndrome,<sup>19</sup> incidence of 1.8-6% has been reported in which carpal tunnel syndrome was due to the persistence median artery.<sup>20</sup>

To the best of our knowledge, this is the first case report of an incomplete palmar arch with higher origin of radial artery and unilateral persisting artery in a corpse. This report accentuate the need for clinicians to have thorough

understanding of anatomical variations of the arterial supply for the hand before any surgery which involves vessels of the forearm and the hand.

#### 4. Source of Funding

None.

#### 5. Conflict of Interest

None.


#### References

- Natsis K, Noussios G, Paraskevas G, Lazaridis N. Study of two cases of high-origin radial artery in humans. *Eur J Anat.* 2009;13(2):97–103.
- Pelin C, Zagyapan R, Mas N, Karabay G. An unusual course of the radial artery. *Folia Morphol (Warsz).* 2006;65(4):410–3.
- Ashraf T, Ziauddin P, Sultana H, Memon MA, Shamsi F, Arif J. Size of radial and ulnar artery in local population. *J Pak Med Assoc.* 2010;60(10):817–9.
- Bidarkotimath S, Ramakrishna A, Arunachalam K. An anatomical study of primary pattern of arteries of upper limb with relevance to their variations. *Nitty Univ J Health Sci.* 2012;2(1):8–14.
- Yokoyama N, Takeshita S, Ochiai M, Koyama Y, Hoshino S, Isshiki T, et al. Anatomic variations of the radial artery in patients undergoing transradial coronary intervention. *Catheter Cardiovasc Interv.* 2000;49(4):357–62.
- Yoo BS, Yoon J, Ko JY, Kim JY, Lee SH, Hwang SO, et al. Anatomical consideration of the radial artery for transradial coronary procedures: arterial diameter, branching anomaly and vessel tortuosity. *Int J Cardiol.* 2005;101(3):421–7.
- Jaschtschinski SN. Morphologie und Topographie des Arcus volaris sublimis und profundus des Menschen. *Anat Heft.* 1897;7:161–8.
- Coleman SS, Anson BJ. Arterial patterns in the hand based upon a study of 650 specimens. *Surg Gynecol Obstet.* 1961;113(4):409–24.
- Eid N, Ito Y, Sibata MA, Otsuki Y. Persistent median artery-cadaveric study and review of the literature. *Clin Anat.* 2011;24(5):627–33.
- Joshi SB, Vatsalawamy P, Bahetee BH. Variation in formation of superficial palmar arches with clinical implications. *J Clin Diagn Res.* 2014;8(4):6–9.
- Coleman SS, Anson B. Arterial patterns in the hand based upon a study of 650 specimens. *Surg Gynecol Obstet.* 1961;113(4):409–24.
- Gellman H, Botte MJ, Shankwiler J, Gelberman RH. Arterial patterns of the deep and superficial palmar arches. *Clin Orthop Relat Res.* 2001;383(383):41–6.
- Kavitha K, Sushma, D'Souza P, Kumar V. Absence of superficial Palmar arch with persistent median artery - A case report. *Nitte Univ J Health Sci.* 2014;4(3):109–11.
- Ikeda A, Ugawa A, Kazihara Y, Hamada N. Arterial patterns in the hand based on a three-dimensional analysis of 220 cadaver hands. *J Hand Surg.* 1988;13(4):501–9.
- Sanudo JR, Chikwe J, Evans SE. Anomalous median nerve associated with persistent median artery. *J Anat.* 1994;185(2):447–51.
- Quain R. The Anatomy of Arteries of Human Body. London: Taylor and Walton; 1884. p. 235–71.
- Standring S, Ellis H, Healy JC, Johnson D, Williams A. Gray's Anatomy. 39th ed. Edinburgh: Churchill Livingstone; 2005.
- Muller E. Beitrage zur Morphologie des Gefasssystems. I. Die Armarterien des Menschen. *Anatomischer Hefte.* 1903;22:377–575.
- Keen JA. A study of the arterial variations in the limbs with special reference to symmetry of vascular patterns. *Am J Anat.* 1961;108:245–61.
- Rodríguez-Baeza A, Nebot J, Ferreira B, Reina F, Pérez J, Sañudo JR, et al. An anatomical study and ontogenetic explanation of 23 cases with variations in the main pattern of the human brachio-antebrachial arteries. *J Anat.* 1995;187(Pt 2):473–9.

#### Author biography

**Amit Purushottam Tirpude**, Associate Professor  
 <https://orcid.org/0000-0003-0223-2270>

**Rahul K Ukey**, Assistant Professor  <https://orcid.org/0000-0002-7775-5132>

**Urvi Sharma**, Senior Resident  <https://orcid.org/0000-0002-9354-9996>

**Cite this article:** Tirpude AP, Ukey RK, Sharma U. Persistent median artery with absence of superficial palmar arch- Case report. *Indian J Clin Anat Physiol* 2023;10(2):124-126.