

Content available at: <https://www.ipinnovative.com/open-access-journals>

Indian Journal of Clinical Anatomy and Physiology

Journal homepage: <https://www.ijcap.org/>

Original Research Article

Study to examine diverse locations of greater palatine foramen in dry human skulls

Vaishakhi Gonsai^{1,*}, Janki Jadav², Sanjay Kanani¹, Ankur Zalawadia¹¹Dept. of Anatomy, GMERS Medical College, Gandhinagar, Gujarat, India²Dept. of Anatomy, Smt. NHL Municipal Medical College, Ahmedabad, Gujarat, India

ARTICLE INFO

Article history:

Received 03-03-2023

Accepted 08-06-2023

Available online 08-07-2023

Keywords:

Greater palatine foramen

Hard palate

Maxillary molars

Pterygopalatine ganglion

Nerve block

ABSTRACT

Introduction: Greater palatine foramen gives passage to greater palatine nerve which innervates posterior part of hard palate. Anesthetic block is given to greater palatine nerve for surgical procedures over upper molar, maxillary sinus & nasal region. In this study, we measured the location of greater palatine foramen (GPF), according to clinically identifiable anatomical landmarks.

Materials and Methods: All measurements were taken bilaterally & directly on dry human skulls. Observations were recorded in millimeters, using a digital vernier caliper. After the data collection, data were analyzed using the standard statistical software (SPSS).

Results: The situation of the GPF in relation to 3rd maxillary molar was in 25% of the skulls. The average values of the distance between the GPF & midline palatine suture (MPS) & posterior border of hard palate (PBHP) were 15.9 mm (SD 1.2) & 5.9 mm (SD 1.1), respectively.

Conclusion: Diverse locations of greater palatine foramen arouse difficulties in locating exact position during anaesthesia. Therefore, understanding the different positions of greater palatine foramen can help surgeons to improve their surgical procedures.

This is an Open Access (OA) journal, and articles are distributed under the terms of the [Creative Commons Attribution-NonCommercial-ShareAlike 4.0 License](https://creativecommons.org/licenses/by-nc-sa/4.0/), which allows others to remix, tweak, and build upon the work non-commercially, as long as appropriate credit is given and the new creations are licensed under the identical terms.

For reprints contact: reprint@ipinnovative.com

1. Introduction

Knowledge of human anatomy grants a great understanding about the situation of structures in the human body and provides a better guide for professionals in the health area.¹

In skull, there is presence of various foramina and every foramen passes important anatomical structures. Any deviation from established location may possess great challenges during surgeries involving structures related to these foramina. Greater palatine foramen is one of the foramen, known for its diverse location leading to adversities in dental surgeries.

The hard palate results from the fusion of the palatine processes of the maxilla bones and the horizontal plates of the palatine bones.² Palatine processes of maxillae bones

and horizontal plates of palatine bones fused with each other by cruciform suture.² Greater palatine foramen is situated in postero-lateral angles of hard palate.³ The foramen transmits greater palatine nerve & vessels.³

The maxillary artery is one of the terminal branches of external carotid artery and is divided into three segments by the lower head of the lateral pterygoid muscle.³ The greater palatine artery arises from the third segment of the maxillary artery and enters into greater palatine foramen alongside the greater palatine nerve.² The mucous membrane of the inferior meatus of the nose, hard palate, gingivae of the maxillary teeth and nasal septum receive blood supply from the greater palatine artery.⁴

Among four parasympathetic ganglions of head and neck region, pterygopalatine ganglion is largest parasympathetic ganglion. It is located in pterygopalatine fossa. Greater palatine nerve is a ganglionic branch of maxillary nerve,

* Corresponding author.

E-mail address: dr.vaishakhi@gmail.com (V. Gonsai).

which passes through pterygopalatine ganglion without relay.² After entering greater palatine foramen, greater palatine nerve along with greater palatine vessels runs through greater palatine canal up to incisive foramen. It supplies the mucous membrane & glands of hard palate and gingivae of maxillary teeth.²

Knowledge of location of greater palatine foramen is needed to achieve anaesthesia over hard palate & gingivae of maxillary teeth. Diverse locations of greater palatine foramen produce difficulties while performing anaesthesia of maxillary nerve.⁵

Due to this condition, thorough anaesthesia is not achieved with the use of the maxillary nerve block during various dental surgeries.⁶ The first explanations about the location of greater palatine foramen were given by Matsuda.⁷

Most frequent method is used for a maxillary nerve block is via greater palatine canal. Maxillary nerve block through greater palatine canal was first described in 1917 by Mendel.⁸ A needle is inserted in greater palatine foramen and pushed forward until it is in the inferior part of the pterygopalatine fossa. In pterygopalatine fossa, anesthetic agent is given.⁹

Our study was undertaken to define the diverse locations of the greater palatine foramen in regards to several anatomical landmarks.

2. Materials and Methods

The study was performed on 50 dry human skulls. The skulls were obtained from Department of Anatomy, G.M.R.S. Medical College, Gandhinagar. Following observations were recorded in millimeters, using digital vernier caliper:

1. Position of the GPF in relation to upper molar teeth.
2. Distance between medial wall of GPF & midline palatine suture (MPS).
3. Distance between posterior wall of GPF & posterior border of hard palate (PBHP).

All measurements were taken bilaterally & directly on dry skulls. After the data collection, data were analyzed through the standard statistically software (SPSS). The mean, standard deviation, minimum and maximum for each measurement were assessed. The t-test was used to confirm the significant differences between the means obtained from the distances of each antimeres of the GPF & reference points.

3. Result

This study is conducted on 50 dry human skulls procured from designated medical college.

Observations concerning the relative position of the greater palatine foramen to the maxillary teeth are presented

in Table 1.

Observations concerning the distance between medial wall of greater palatine foramen & midline palatine suture (MPS) & distance between posterior wall of greater palatine foramen & posterior border of hard palate (PBHP) are presented in Table 2.

Data obtained from statistics analysis suggested no significant difference in the measurement between the right & left sides with regard to the distance of greater palatine foramen (GPF) to the midline palatine suture (MPS) & greater palatine foramen (GPF) to posterior border of hard palate (PBHP).

Table 3 shows t-test comparing the mean of antimeres of each reference point. While there was no statistical difference in distance between GPF and MPS of left and right side but statistical difference was found in distance between GPF and PBHP of left and right side

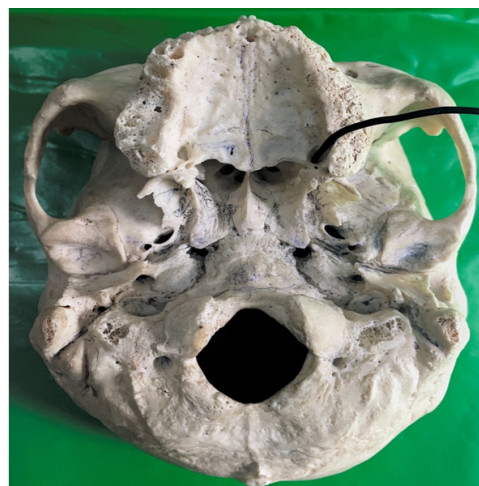

Fig. 1: Illustrates probe in greater palatine foramen

4. Discussion

Anaesthesia over hard palate is essential for dental surgery. To achieve that, anaesthetic agent is given in greater palatine nerve. It is essential for the dentists and oral surgeon have knowledge about the location of the greater palatine foramina for periodontal procedures, drainage of abscesses and dental extractions.¹⁰ In this study, GPF was localized using easily identifiable marks, according to clinical experience gained during regional anaesthesia procedures.

In Table 4, results of various studies related to position of greater palatine foramen in relation to anatomical landmarks are summarized. Westmoreland & Blanton¹¹ observed 50.70% of GPF were located medial to 3rd maxillary molar. In the study by Ajmani,¹² 48.46% of GPF in Nigerian & 64% of GPF in Indian skulls were located medial or opposite of the 3rd maxillary molar. Saralaya &

Table 1: Variations in the location of greater palatine foramen in relation to maxillary molars

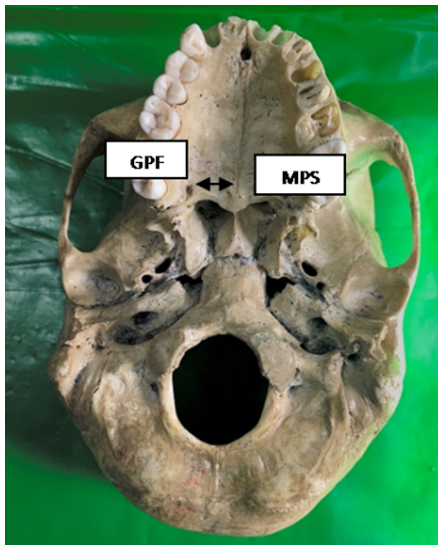
Group	Medial to 2nd molar	Between 2nd & 3rd molars	Medial to 3rd molar	Behind 3rd molar
Right	8	10	25	7
Left	8	10	25	7
Total	16	20	50	14
Percentage	8	10	25	7

Table 2: Distance (mm) of greater palatine foramen from midline palatine suture (MPS) & distance (mm) of greater palatine foramen from posterior border of hard palate (PBHP) (values in mm)

Parameters	Mean	SD	Minimum	Maximum	Median
Right GPF-MPS Distance(mm)	15.9	1.2	13.9	18.3	15.7
Left GPF-MPS Distance (mm)	15.9	1.2	13.9	18.3	15.7
Right GPF-PBHP Distance (mm)	5.9	1.1	4.2	8.7	6.04
Left GPF-PBHP Distance (mm)	5.9	1.1	4.2	8.7	6.04

Table 3: T-test comparing the mean of antimere of each reference point

	Mean	Standard Deviation	t	P
Right GPF to MPS	15.9	1.2	1.426	0.160
Left GPF to MPS	15.9	1.2		
Right GPF to PBHP	5.9	1.1	2.772	0.008
Left GPF to PBHP	5.9	1.1		

**Fig. 2:** Shows distance between Greater palatine foramen (GPF) & Midline palatine suture (MPS)**Fig. 3:** Illustrates the measurement of distance from greater palatine foramen (GPF) to Median palatine suture (MPS)

Nayak¹³ observed 74.6% of GPF were located medial to 3rd molar. Hassanali & Mwaniki¹⁴ observed 76% of GPF (in Kenyan skulls) were located medial to 3rd molar. In the study of Wang,¹⁵ 33.5% of GPF (in Chinese skulls) were located medial to 3rd maxillary molar. In the study of Langengger,¹⁶ 62% of GPF were located medial to 3rd molar. In our study, second most common site of GPF was between 2nd & 3rd molar (10%). GPF was medial to 2nd molar in 8% skulls & it was behind 3rd molar.

In study of Ajmani,¹² the distance from GPF to PBHP was found 3.5mm & 3.7mm in Nigerian & Indian skulls, respectively. According to Westmoreland & Blanton,¹¹ the distance from GPF to PBHP was found 1.9mm, in study of Wang,¹⁵ distance was 4.11mm, in study of Saralaya & Nayak,¹³ distance was 4.2mm, in study of Methathrathip,¹⁷ distance was 2.1mm, in study of Jaffar & Hamadah¹⁸ distance was 4.86mm, in study of Bruno R. Chrcanovic¹⁹ distance was 3.39mm and in study of V. Nimigeen²⁰ distance was 4.4mm.

Table 4: Studies reporting relationships between GPF & different anatomical landmarks

Study	GPF-MPS (mm)		GPF-PBHP (mm)	Relation to 3 rd maxillary molar (%)
	Right	Left		
Westmoreland and Blanton, 1982	14.8	15.0	1.9	50.70
Langenger et al., 1983				62.00
Hassanali and Mwaniki, 1984				76.00
Wang et al., 1988	16.0	16.0	4.11	33.50
Ajmani, 1994 (Nigerian skulls)	15.4*		3.5	48.46
Ajmani, 1994 (Indian skulls)	14.7	14.6	3.7	64.69
Jaffar and Hamadah, 2003	15.7*		4.86	55.00
Methathrathip et al., 2005	16.2*		2.1	71.90
Saralaya and Nayak, 2007	14.7	14.7	4.2	74.60
Bruno R. Chrcanovic et al., 2010	14.68	14.44	3.39	54.87
V.Nimigean et al., 2013		14.5*	4.4	91.00
This study		15.9	5.9	25.00

* No distinction between right and left sides

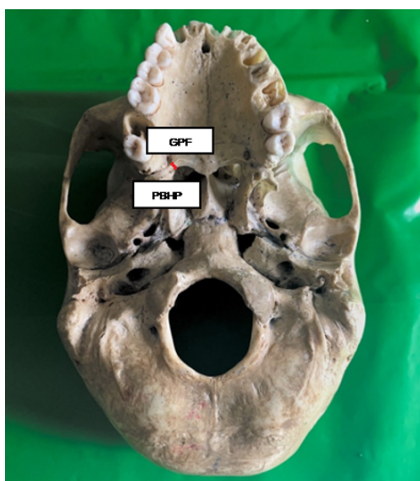

Fig. 4: Shows distance between Greater palatine foramen (GPF) & Posterior border of hard palate (PBHP)

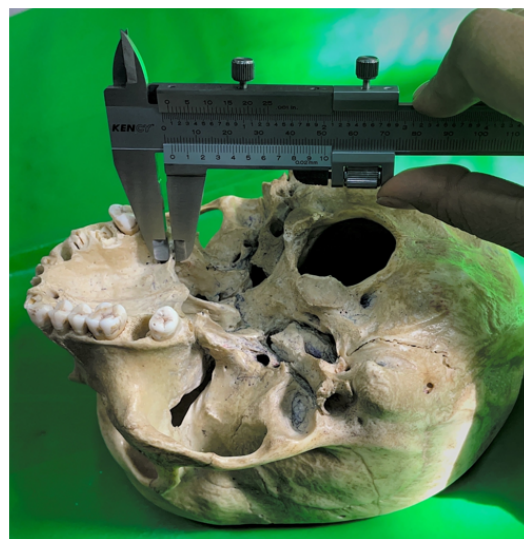


Fig. 5: Illustrates the measurement of distance from greater palatine foramen (GPF) to Posterior border of hard palate (PBHP)

In the study of Westmoreland & Blanton,¹¹ the distance between GPF & MPS on the right side was a mean of 14.8mm & 15.0mm on the left. Ajmani¹² reported a distance of 15.4mm from the sagittal plane in Nigerian skulls & 14.7mm on the right & 14.6mm on the left in Indian skulls. Saralaya & Nayak,¹³ found 14.7mm on both sides. Wang¹⁵ found distance between GPF & MPS about 16mm. Methathrathip¹⁷ found 2.1mm.

In the study of Jaffar & Hamadah¹⁸, Bruno R. & Antônio L.19 and Dave M. R. et al,²¹ authors have not found any statistical difference between GPF-PBHP and GPF-MPS. In our study, we found statistical difference in distance between GPF and PBHP of left and right side. Although how this statistical difference can contribute clinically is uncertain and future larger studies can further enlighten us about this difference.

5. Conclusions

In this study, greater palatine foramen was near to 3rd maxillary molar tooth was found in 25% of the skulls. In regard of distance between GPF-MPS & GPF-PBHP, findings of this study are in line with previous studies except right and left side difference of GPF to PBHP. Diverse locations of greater palatine foramen arouse difficulties in locating exact position during anaesthesia. Therefore, understanding the different positions of greater palatine foramen can help surgeons to improve their surgical procedures.

6. Source of Funding

Authors of this study declare that present study did not receive any grants or funds from funding agencies.


7. Conflicts of Interests

The authors declare that they have no conflicts of interests.

References

- Teixeira CS, Souza VR, Marques CP, Junior WS, Pereira KF. Topography of the greater palatine foramen in macerated skulls. *J Morphol Sci.* 2010;27(2):88–92.
- Data AK. Essentials of human anatomy, Head & Neck, Part-II. 5th ed. Kolkata: Books International Publication; 2009. p. 152–4.
- Singh V. Textbook of Anatomy, Head & Neck & Brain. vol. III. 2nd ed. India: Elsevier; 2014. p. 23–137.
- Standring S. Gray's Anatomy – The Anatomical basis of clinical practice. 41st ed. Netherlands: Elsevier Health Sciences; 2016. p. 553.
- Blanton PL, Jeske AH. The key to profound local anesthesia: neuroanatomy. *J Am Dent Assoc.* 2003;134(6):753–60.
- Mercuri LG. Intraoral second division nerve block. *Oral Surg Oral Med Oral Pathol.* 1979;47(2):109–13.
- Matsuda Y. Location of the dental foramina in human skulls from statistical observations. *Int J Orthodontia Oral Surg Radiogr.* 1927;13(4):299–305. Available from: [https://doi.org/10.1016/s0099-6963\(27\)90124-0](https://doi.org/10.1016/s0099-6963(27)90124-0).
- Mendel N, Puterbaugh PG. Conduction, Infiltration & General Anesthesia in Dentistry. 4th ed. Brooklyn NY, editor. Chicago: Dental Items of Interest Publishing Company; 1938. p. 140.
- Douglas R, Wormald PJ. Pterygopalatine fossa infiltration through the greater palatine foramen: where to bend the needle. *Laryngoscope.* 2006;116(7):1255–7.
- Malamed FS. Handbook of local anesthesia. 6th ed. Elsevier Publication; 2012. p. 422.
- Westmoreland EE, Blanton PL. An analysis of the variations in position of the greater palatine foramen in the adult human skull. *Anat Rec.* 1982;204(4):383–8.
- Ajmani ML. Anatomical variation in position of the greater palatine foramen in the adult human skull. *J Anat.* 1994;184(Pt 3):635–7.
- Saralaya V, Nayak SR. The relative position of the greater palatine foramen in dry Indian skulls. *Singapore Med J.* 2007;48(12):1143–6.
- Hassanali J, Mwaniki D. Palatal analysis and osteology of the hard palate of the Kenyan African skulls. *Anat Rec.* 1984;209(2):273–80.
- Wang TM, Kuo KJ, Shih C, Ho LL, Liu JC. Assessment of the relative locations of the greater palatine foramen in adult Chinese skulls. *Acta Anat (Basel).* 1988;132(3):182–6.
- Langenegger JJ, Lownie JF, Cleaton-Jones PE. The relationship of the greater palatine foramen to the molar teeth and pterygoidhamulus in human skulls. *J Dent.* 1983;11(3):249–56.
- Methathrathip D, Apinhasmit W, Chompoopong S, Lertsirithong A, Ariyawatkul T, Sangvichien S. Anatomy of greater palatine foramen and canal and pterygopalatine fossa in Thais: considerations for maxillary nerve block. *Surg Radiol Anat.* 2005;27(6):511–6.
- Jaffar AA, Hamadah HJ. An analysis of the position of the greater palatine foramen. *J Basic Med Sci.* 2003;3(1):24–32.
- Chrcanovic BR, Custódio AL. Anatomical variation in the position of the greater palatine foramen. *J Oral Sci.* 2010;52(1):109–13.
- Nimigean V, Nimigean VR, Buşincu L, Sălăvăstru DI, Podoleanu L. Anatomical and clinical considerations regarding the greater palatine foramen. *Rom J Morphol Embryol.* 2013;54(3):779–83.
- Dave MR, Yagain VK, Anadkat S. A Study of the Anatomical Variations in the Position of the Greater Palatine Foramen in Adult Human Skulls and its Clinical Significance. *Int J Morphol.* 2013;31(2):578–83.

Author biography

Vaishakhi Gonsai, Tutor  <https://orcid.org/0009-0001-8461-7643>

Janki Jadav, Tutor

Sanjay Kanani, Assistant Professor

Ankur Zalawadia, Professor & Head

Cite this article: Gonsai V, Jadav J, Kanani S, Zalawadia A. Study to examine diverse locations of greater palatine foramen in dry human skulls. *Indian J Clin Anat Physiol* 2023;10(2):95-99.