

Content available at: <https://www.ipinnovative.com/open-access-journals>

Indian Journal of Clinical Anatomy and Physiology

Journal homepage: <https://www.ijcap.org/>

Original Research Article

Morphometric study of nasal bones and piriform apertures in human skulls

Mohini M Joshi^{1,*}, Sushama K Chavan²¹Dept. of Anatomy, Rural Medical College, Pravara Institute of Medical Sciences, Loni, Maharashtra, India²Dept. of Anatomy, MIMER Medical College, Pune, Maharashtra, India

ARTICLE INFO

Article history:

Received 18-09-2021

Accepted 17-11-2021

Available online 07-12-2021

Keywords:

Morphometry

Nasal bone

Piriform aperture

Shape

ABSTRACT

Background: The piriform aperture (PA) is the skeletal aperture located in the middle part of the face. There are many variations in morphometric measurements of nasal bones, piriform apertures and their shapes in different population.

Objective: Objective of present study was to study morphological and morphometric features of nasal bone and piriform aperture.

Material and Methods: Adult human skulls available from collection of dried skulls were used for study purpose. Skull bones of unknown age and sex were obtained. Height, width of nasal bone, height, upper and lower width of piriform aperture, shapes of nasal bone and piriform aperture were observed.

Result: Height, upper width and lower width of piriform aperture were greater in male as compared to female. This difference was not statistically significant for upper width of piriform aperture ($p=0.49$) and for lower width of piriform aperture ($p=0.65$) while the difference in height of piriform aperture was statistically significant. ($p < 0.0001$). Differences in Height and width of nasal bone were not statistically significant among male and female nasal bones. Most common shape of nasal bone observed was Type A followed by Type B and C. Most common shape of piriform aperture was triangular to oval (50.00) in both the gender.

Conclusion: Majority finding of the present study are in concordance with Indian population studies while significant differences have been noted in comparison to the morphometric measurements of Turkish, Korean, Brazilian and Anatolian population. These variations might be because of differences in ethnicity.

This is an Open Access (OA) journal, and articles are distributed under the terms of the [Creative Commons Attribution-NonCommercial-ShareAlike 4.0 License](https://creativecommons.org/licenses/by-nc-sa/4.0/), which allows others to remix, tweak, and build upon the work non-commercially, as long as appropriate credit is given and the new creations are licensed under the identical terms.

For reprints contact: reprint@ipinnovative.com

1. Introduction

The piriform aperture (PA) is the skeletal aperture located in the middle part of the face and limited by the frontal processes of the maxillary bones, the nasal bones, and the anterior nasal spine, palatal process of the maxilla inferiorly. It corresponds to the anterior limit of the skeletal nose, and a major component of the size of the nose and^{1,2} the features of the piriform aperture have been reported as classic indicator of sexual differentiation.³ The measurements of PA can be an anatomical landmark

used for ethnic differentiation in human identification and provide information for surgical procedures and nasal reconstruction in otolaryngology. There are many variations in nasal bone shape among the different population e.g. the nose is much broader with thickened upper nasal region in East Asians. It is longer and more prominent in Middle Eastern and Southern European populations. Most Egyptian skulls are typically North African Caucasians. The shape of nose in them is broad and lack of a sharp lower border. It is therefore necessary that in cases of unidentified skeletal remains, the ancestry should be estimated.⁴ The knowledge of the morphometric measures

* Corresponding author.

E-mail address: atharvamohini@gmail.com (M. M. Joshi).

is of immense importance for performing rhinoplasty, osteotomies and plastic reconstructions.⁵ The respiratory mechanics may be affected due to trauma to the piriform aperture.⁶ Their form and size may also serve as a basis for anthropological studies. Knowledge of dimensions and shape of the piriform aperture in human skulls, are essential for better understanding of Anatomical structure. With these backgrounds in mind the objective was to study morphological features of nasal bone and piriform aperture.

2. Materials and Methods

Present study was approved by Institutional Ethical and Research committee [Registration No: PIMS/DR/RMC/2018/251] of a Pravara Institute of Medical Sciences, Loni. Adult human skulls available from collection of dried skulls in the department of Anatomy and from undergraduate students were used for study purpose. Skull bones of unknown age and sex were obtained.

2.1. Sex determination

Female skulls are smaller in size, having sharper supraorbital margins, smaller teeth, smaller muscle ridges, smaller and pointed mastoid process narrower zygomatic arch and smaller frontal sinus as compared to male skull. External occipital protuberance is prominent in male skulls and palate is larger in males.⁷

2.2. Inclusion criteria

Skulls in perfect anatomical conditions will be selected.

2.3. Exclusion criteria

Fractured skulls will be excluded because they may alter the piriform aperture measurements.

2.4. Sample size

After fulfilling inclusion and exclusion criteria 54 available skulls were selected for the study.

2.5. Material

1. Thread
2. Scale
3. Vernier caliper

Following measurements of nasal bone and piriform aperture were noted.

1. Height of piriform aperture: The height of the piriform aperture was measured between the inferior margin of the internasal suture to the anterior nasal spine (Figure 1).

2. Upper width of piriform aperture: Upper width of piriform aperture was measured between the right and left naso-maxillary junction. (Figure 2)
3. Lower width of piriform aperture: Lower width of the piriform apertures was measured between the right and left margin of the anterior surface of the maxilla. (Figure 3)
4. Height of nasal bone: The height of Nasal bones were measured from the nasion to the rhino. (Figure 4)
5. Width of nasal bone: The width of the nasal bones was measured between the upper points of the lateral borders of the nasal bone. (Figure 5)
6. Shape of nasal bone were classified as A, B,C, D and E as mentioned by Hwang et al.¹
7. Shape of piriform aperture: The shapes of piriform aperture were classified as long narrow, triangular, triangular to oval and tending to roundness.

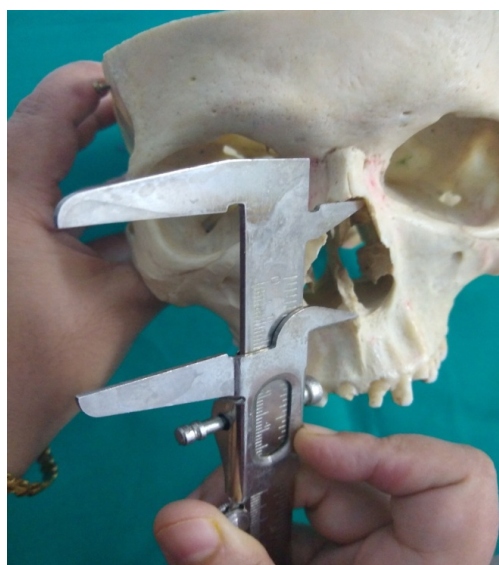


Fig. 1: Showing measurement of height of Piriform Aperture was measured between the inferior margin of the internasal suture to the anterior nasal spine

2.6. Statistical analysis

All the data was entered into Microsoft Excel and descriptive statistics like mean, standard deviation and inferential statistics in the form of unpaired t test was applied for analysis.

3. Results

It is evident from Table 1 that height, upper width and lower width of piriform aperture were greater in male as compared to female. This difference was not statistically significant for upper width of piriform aperture ($p=0.49$) and for lower width of piriform aperture ($p= 0.65$) while the difference in

Table 1: Showing measurements of the piriform aperture in skulls by sex

Type of measurements	Sex	Sample size	Mean±S.D	t	P value
Height of piriform aperture	Male	29	32.4±1.7	9.56	<0.0001
	Female	25	28.1±1.6		
Upper width of piriform aperture	Male	29	16.1±2.2	0.68	0.49
	Female	25	15.7±2.1		
Lower width of piriform aperture	Male	29	24.8±1.3	0.44	0.65
	Female	25	24.6±1.9		

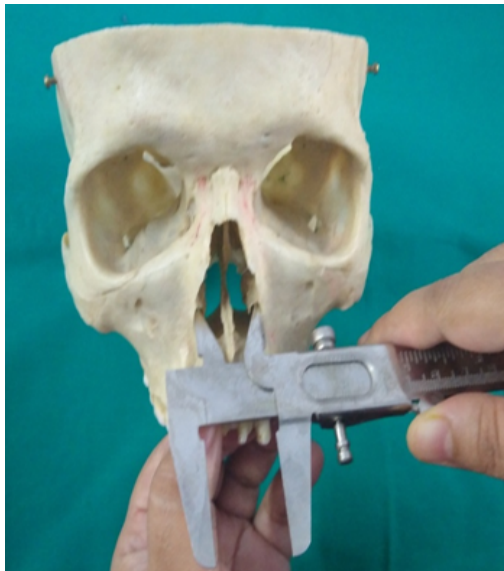

Fig. 2: Showing measurement of upper width of Piriform Aperture was measured between the right and left naso-maxillary junction

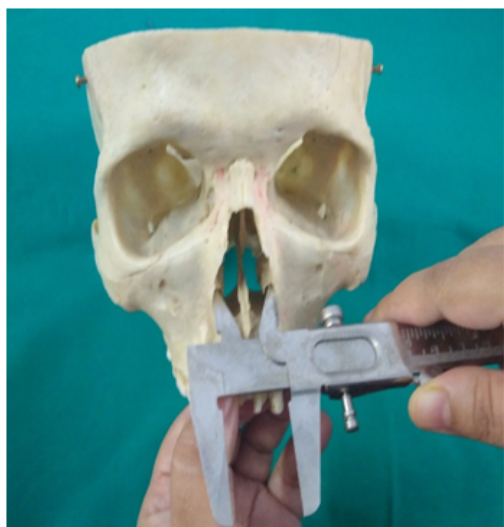

Fig. 3: Showing measurement of Lower Width of Piriform Aperture was measured between the right and left margin of the anterior surface of the maxilla

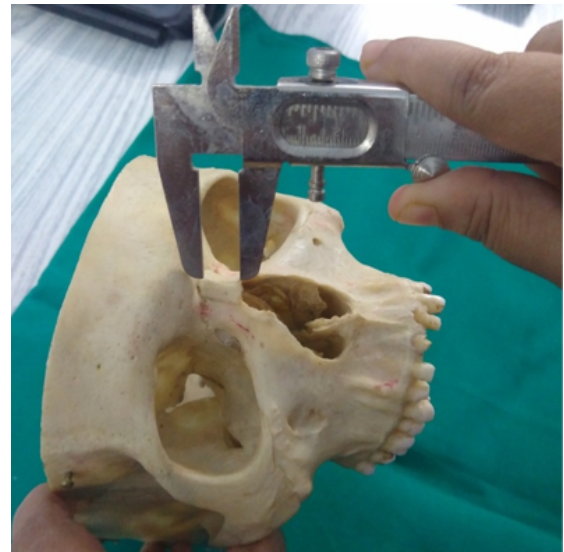

Fig. 4: Showing measurement of height of nasal bone were measured from the nasion to the rhino

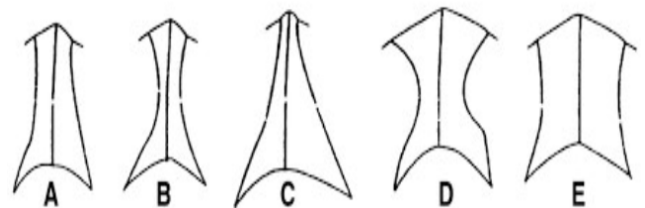


Fig. 5: Shapes of nasal bone were classified as A, B,C,D and E as mentioned by Hwang et al

height of piriform aperture was statistically significant. ($p < 0.0001$).

Differences in Height and width of nasal bone were not statistically significant among male and female nasal bones.(Table 2)

Shapes of nasal bone were classified as A, B,C,D and E as mentioned by Hwang et al. Most common shape of nasal bone observed was Type A followed by Type B and C. (Table 3)

It is evident from Table 4 that most common shape of piriform aperture was triangular to oval (50.00) in both the gender followed by tending to roundness (31.48).

Table 2: Showing measurements of the nasal bone in skulls by sex

Type of measurements	Sex	Sample size	Mean±S.D	t value	P value
Height of Nasal bone	Male	29	16.8±2.1	0.85	0.39
	Female	25	16.4±1.3		
Width of nasal bone	Male	29	10.7±1.4	0.72	0.47
	Female	25	10.4±1.6		

Table 3: Showing shape of nasal bone

S.No.	Type of Shape of nasal bone	Number of skulls(n=54)	Percentage
1	Type A	23	42.59
2	Type B	10	18.51
3	Type C	09	16.66
4	Type D	07	12.96
5	Type E	05	09.25
6	Total	54	100

Table 4: Showing shape of piriform aperture

S.No.	Shape of Piriform Aperture	Male	Female	Total (%)
1	Long and Narrow	01	01	02(3.70)
2	Triangular	05	03	08(14.81)
3	Triangular to Oval	15	12	27(50.00)
4	Tending to Roundness	08	09	17(31.48)
	Total	29	25	54(100.00)

4. Discussion

Adult human skulls were used for morphometric study of nasal bone and piriform aperture. It is evident from Table 1 that height, upper width and lower width of piriform aperture were greater in male as compared to female. The difference in height of piriform aperture was statistically significant. (<0.0001). Height of piriform aperture in a study by Durga Devi et al⁸ on south Indian population was 31.2 ± 1.3 mm in male 27.2 ± 1.3 mm in female while in a study done by Cantin et al on Brazilian dry skull was 50.82 mm in male 47.53 mm in female.³ Moredduet al studied on 3D computerized tomography scan (C.T. scan), the values were 32.54 mm in females and 36.35 mm in males.⁶ In a study by Hwang et al on Korean population piriform aperture height was 30.1 mm and 28 mm in males and females respectively.¹ Yüzbaşıoğlu et al studied skull CT on Turkish population 33.4 mm and 30.1 mm males and females respectively.⁹ In present study PA height was 32.4 ± 1.7 mm in males and 28.1 ± 1.6 mm in females. In a study done by Asghar et al⁷ on North Indian the mean Height of PA was 29.57 ± 3.28 mm in females and 31.16 ± 3.58 mm in males which corresponds with present study. Upper width of piriform aperture was 15.6 ± 2.4 mm in male 16.6 ± 2.8 mm in female in a study conducted by Durga Devi et al on south Indian population.⁸ Hwang et al¹ showed upper width of PA 16.8 ± 2.6 mm in male 17.0 ± 2.0 mm in female but in the present study upper width of PA was 16.1 ± 2.2 mm in male and 15.7 ± 2.1 mm in female, (Table 1) which was in concordance with observations by Durga et

al.⁸ In present study, upper width of piriform aperture was greater in male as compared to female. This difference was not statistically significant for upper width of piriform aperture ($p=0.49$). Hwang et al reported lower width of PA 25.7 ± 1.7 mm in males and 25.4 ± 2.1 in females.¹ Durga Devi et al observed lower width of PA in male 24.03 ± 1.4 mm and 24.4 ± 2.3 mm in female.⁸ In present study, lower width of piriform aperture was 24.8 ± 1.3 mm in male and 24.6 ± 1.9 mm in female. It is evident from Table 1 that lower width of piriform aperture was greater in male as compared to female and this difference was not statistically significant ($p=0.65$).

Height of Nasal bone in present study is 16.8 ± 2.1 mm in male and 16.4 ± 1.3 in female. (Table 2) In a study of Turkish population by Yüzbaşıoğlu N et al, height of nasal bone was 18.7 mm in male and 17.2 mm in female.¹⁰ Hwang et al reported height of nasal bone 25.9 mm in male and 24.5 mm in female.¹ Karadag D et al in a study carried out in Antolian population observed that height of nasal bone was 30.61 mm in male and 29.01 mm in female.¹⁰ Baek et al in a study carried out study in Korean population and that height of nasal bone was 22 mm in male and 17.3 in females.¹¹ In a South Indian population study by Durga et al reported that nasal bone height was 16.3 ± 1.9 mm in male and 17.4 ± 2.3 mm in female, values of which correlates with present study. In a study carried out by Asghar et al height of nasal bone was 17.76 mm in male and 17.25 mm in female.⁷

In present study width of nasal bone was 10.7 ± 1.4 mm in male and 10.4 ± 1.6 mm in female. (Table 2). In a study by Yüzbaşıoğlu et al width of nasal bone was 11.8 mm in male

and 12 mm in female. 9] while in North Indian population width of nasal bone was 12.6mm in male and 11.8 mm in female.⁷ In a study by Durga et al width of nasal bone was 11.3±1.6 in males and in female it was 12.05±1.7 mm in south Indian population.⁸

In present study shapes of nasal bone were classified as A, B, C, D and E as mentioned by Hwang et al.¹ Most common shape of nasal bone observed was Type A (42.59%) followed by Type B (18.51%) and C(16.66%) and Type D(12.96%) and Type E (09.25) (Table 3). In a study carried out in Korean population by Hwang, commonest shape of nasal bone were Type B (52.3%) next Type A,[43.2%] followed by Type C(4.5%) while Type D and Type E were not found.¹ In a study carried out in South Indian population in relation to the shape of nasal bone, Type A was 35.2%, Type B 19.6%, Type C 17.6%, Type D 15.6% and Type E 11.7%.⁸

In present study shape of piriform aperture was Triangular to Oval in 50% followed by tending to roundness 31.48%, Triangular 14.81% and Long and Narrow 3.70%. (Table 4) In a study by Durga Devi et al shape of piriform aperture was triangular to oval 45.09% and tending to roundness in 39.21%.⁸ Asghar et al observed shape of piriform aperture triangular to oval 83.5% tending to roundness in 15%.⁷

5. Conclusion

Height, upper width and lower width of piriform aperture were greater in male as compared to female but only the difference in height of piriform aperture was statistically significant. Differences in Height and width of nasal bone were not statistically significant among male and female nasal bones. Most common shape of nasal bone observed was Type A followed by Type B and C. Most common shape of piriform aperture was triangular to oval in both the gender. Majority finding of the present study were in concordance with North and south Indian population studies while significant differences have been noted in comparison to the morphometric measurements of Turkish, Korean, Brazilian and Anatolian population. These variations might be because of differences in ethnicity.

6. Source of Funding

None.

7. Conflict of Interest

The authors declare no conflict of interest.

References

- Hwang TS, Song J, Yoon H, Cho BP, Kang HS. Morphometry of the nasal bones and piriform apertures in Koreans. *Ann Anat.* 2005;187:411–4.
- Gray H, Standing S, Ellis H, Berkovitz BKB. Gray's anatomy: the anatomical basis of clinical practice. 39th ed. Edinburgh: Elsevier Churchill Livingstone; 2005.
- Cantin LM, Suazo GIC, Zavando MDA. Sexual dimorphism determination by piriform aperture morphometric analysis in Brazilian human skulls. *Int J Morphol.* 2009;27:327–31.
- Vioarsdottir US, Higgins PO, Stringer CA. Geometric morphometric study of regional differences in the ontogeny of the modern human facial skeleton. *J Anat.* 2002;201:211.
- Citardi MJ, Hardeman S, Hollenbeak C, Kokoska M. Computer aided assessment of bony nasal pyramid dimensions. *Arch Otolaryngol Head Neck Surg.* 2000;126(8):979–84.
- Moreddu E, Puymeraill L, Michel J, Achache M, Dessi P, Adalian P, et al. Morphometric measurements and sexual dimorphism of the piriform aperture in adults. *Surg Radiol Anat.* 2013;35(10):917–24.
- Asghar A, Dixit A, Rani M. Morphometric Study of Nasal Bone and Piriform Aperture in Human Dry Skull of Indian Origin. *J Clin Diagn Res.* 2016;10(1):AC05–7. doi:10.7860/JCDR/2016/15677.7148.
- Devi DG, Archana R, WMSJohnson. Morphometric Study of Nasal Bone and Piriform Aperture in Human Dry Skull Of South Indian Origin. *Int J Anat Res.* 2018;6(4.3):5970–3.
- Yüzbasioğlu N, Yılmaz MT, Çicekcibasi AE, Eeker M, Sakarya ME. The Evaluation of Morphometry of Nasal Bone and Piriform Aperture using Multidetector Computed Tomography. *J Craniofac Surg.* 2014;25(6):2214–9.
- Karadag D, Ozdoll NC, Beriat K, Akinci T. CT evaluation of the bony nasal pyramid dimensions in Anatolian people. *Dentomaxillofac Radiol.* 2011;40:160–4.
- Baek HJ, Kim DW, Ryu JH, Lee YJ. Identification of Nasal Bone Fractures on Conventional Radiography and Facial CT: Comparison of the Diagnostic Accuracy in Different Imaging Modalities and Analysis of Inter observer Reliability. *Iran J Radiol.* 2013;10(3):140–7.

Author biography

Mohini M Joshi, Professor

Sushama K Chavan, Professor

Cite this article: Joshi MM, Chavan SK. Morphometric study of nasal bones and piriform apertures in human skulls. *Indian J Clin Anat Physiol* 2021;8(4):269–273.