

Content available at: <https://www.ipinnovative.com/open-access-journals>

Indian Journal of Clinical Anatomy and Physiology

Journal homepage: <https://www.ijcap.org/>

Original Research Article

A study of psoas minor muscle morphology

Deepthi Simhadri^{1,*}, T Navakalyani¹, D Suseelamma²¹Dept. of Anatomy, Government Medical College, Mahabubnagar, Telangana, India²Dept. of Anatomy, S V S Medical College, Mahabubnagar, Telangana, India

ARTICLE INFO

Article history:

Received 23-06-2021

Accepted 12-08-2021

Available online 01-10-2021

Keywords:

Frequency

Muscle variation

Psoas minor

Vestigial muscle

ABSTRACT

Introduction: Psoas minor is long, slender skeletal muscle it lies anterior to psoas major. It is an inconstant muscle. It was absent in 40-70% of subjects.**Aim & Objectives:** To determine the frequency and morphometry of psoas minor muscle.**Materials and Methods:** 20 cadavers were dissected during routine dissection for undergraduate students at Ayaan institute of medical sciences, Moinabad, Hyderabad and Government medical college, Mahabubnagar.**Results & Observation:** Bilateral variations were observed in one specimen, unilateral variations were observed in two specimens.**Conclusion:** Out of forty specimens Psoas minor was present in three specimens. In one specimen bilateral variations observed, other two specimens unilateral. If it is present, clinical importance to radiologists, surgeons and physiotherapists as it can mimic certain abdominal emergencies.This is an Open Access (OA) journal, and articles are distributed under the terms of the [Creative Commons Attribution-NonCommercial-ShareAlike 4.0 License](https://creativecommons.org/licenses/by-nc-sa/4.0/), which allows others to remix, tweak, and build upon the work non-commercially, as long as appropriate credit is given and the new creations are licensed under the identical terms.For reprints contact: reprint@ipinnovative.com

1. Introduction

There can be an occurrence of a variable muscle called psoas minor, which could be unilaterally or bilaterally present. Psoas minor, if present, will be located in front of the psoas major. It is seen to have a small belly and a long tendon.

This muscle arises from the sides of bodies of T₁₂ and L₁. It is inserted into the iliopubic eminence, pectineal line and iliac fascia. The nerve supply for the muscle is derived from the ventral ramus of the first lumbar spinal nerve. It acts as a weak flexor of the trunk. It is a small muscle, it appears only 60% of cadavers.¹

It arises from upper most fibers of psoas major descends on the anterior surface of psoas major muscle, it forming a slender tendon. It is inserted into thickened lower part of fascia which is covering psoas major and iliacus. It is

inserted medially to arcuate line of ilium and laterally with iliac fascia to inguinal ligament. L₁ nerve supplies psoas minor.

1.1. Action

Flexor of hip joint and lateral flexors of lumbar vertebral column.²

The psoas minor muscle is supplied by branches of lumbar plexus (L1-L3). It is an inconstant muscle which represents the thin ligament or broadening of medial part of iliopsoas. It is an inner hip muscle. It contributes to stabilization of the pelvis. A unilateral contraction may weakly assist in flexing the lumbar vertebrae. Bilateral activation flex the trunk to front. This muscle plays a subordinate role.³

If it is present it lies anterior to psoas major and is confined to abdomen only, has common origin to psoas major, is inserted to iliopubic eminence.⁴

* Corresponding author.

E-mail address: deepthisimhadri.12@gmail.com (D. Simhadri).

It is only present in two out of every three individuals, lying on surface of psoas major. It lies in the gutter between the bodies and transverse process of the lumbar vertebrae. It is a weak flexor of the lumbar spine.⁵

Darwin describes that psoas minor is vestigial muscle like ear muscles, various small tendinous muscles. Darwin mentioned some variants of muscle like psoas tertius, psoas quadrates, psoas accessories it is well-developed in quadrupeds the brachiate and run at high speed. These functions are not required for bipedal gait hence muscle has receded during evolution. Trisomy 18 patients it is consistently absent.⁶ This reference is not coming sequentially)

1.2. Clinical importance

The major clinical implications of the PMM (Psoas minor muscle) is that of psoas minor syndrome and its ability to spread infection and malignancy to the retroperitoneal region of the body. Psoas minor syndrome presents as pain in the iliac fossa due to increased tension of the PMM. Pain is exacerbated by palpation of the taut tendon.

The symptoms appear due to compression of retroperitoneal neurovascular structures. Symptoms from psoas minor syndrome can also mimic that of diverticulitis and appendicitis and needs to be ruled out. The accepted treatment is a tenotomy. Patients with psoas minor syndrome will have difficulty performing various exercises, especially jumping.⁷

The psoas muscles is enclosed in the psoas sheath is formed by psoas fascia, is a part of lumbar fascia. Pus from trabecular infection of the lumbar vertebrae may spread into psoas minor muscle is called psoas abscess. The typical posture of a laterally rotated lower limb following fracture of neck of the femur is produced by contraction of psoas muscle.⁸

2. Aim

To study the morphology and prevalence of Psoas minor muscle in the Telangana population.

3. Materials and Methods

This study was carried out in the Department of Anatomy, Ayaan institute of medical sciences, Moinabad and government medical college, Mahabubnagar, on a total of 20 cadavers (All male) during routine dissection for under graduate MBBS students.

Dissection steps

1. After completion of anterior wall dissection, removing the abdominal organs turn the body in prone position.
2. Expose the muscles of the posterior abdominal wall by removing the fascia covering the psoas muscles.

3. Identify the origin, course, insertion of psoas minor muscles.

Followed by cunninghams practical manual

The length, width, and circumference of the muscles were measured by using vernier calipers. The collected data were interpreted in a descriptive manner.

4. Results

Psoas minor arises from sides of L1-L5, it descends along with psoas major ends in long fleshy tendon. It is present in posterior abdominal wall, is covered by psoas fascia. It is inserted into ilio pubic eminence.

The PMM was present in three out of twenty cadavers (15%). Out of those twenty cadavers, the muscle was bilateral in one cadaver, unilateral on the left side in another cadaver, and unilateral on the right side in another cadaver.

The average length of the muscle was 19.66 mm (range:16.7 mm – 22.5 mm), average width was 2.78 mm (range: 1.0 mm - 3.2 mm) and average circumference was 2.79 mm (range: 1.7 mm - maximum 5.6 mm), average tendon length -16mm-19mm. I have taken maximum width and circumference between origin and insertion.



Fig. 1: Showing bilateral variations of psoas minor lies on anterior surface of psoas major

5. Discussion

Joshi et al. in 2010 stated that the psoas minor muscle plays an important role in the flexion of lumbar vertebrae and is well-developed in rabbits and apes. In his study on 30 cadavers, he concluded that the psoas minor was absent in 70% population.⁶

Sachin P et al studied in 20 cadavers (16 males, 4 female), psoas minor was present in 7 cadavers. Psoas minor was present unilaterally in one cadaver, bilaterally in six cadavers.

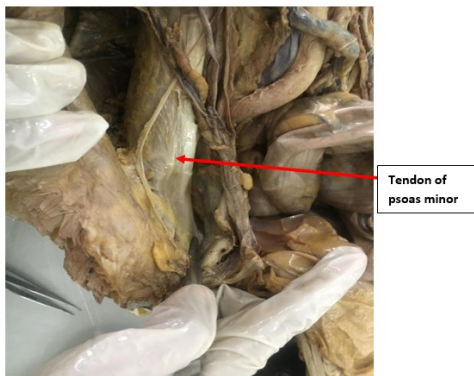
The average value of total muscle length was 215.2 ± 11.09 mm, length of muscle belly was 67.7 ± 3.42 mm, length of tendon was 145.7 ± 3.5 mm, width and thickness

Table 1: Showing length and width of fleshy belly and tendon of psoas minor

Psaos minor muscle	Fleshy belly		Tendon	
	Length	Width	Length	Width
Right side	16.8mm	2.68mm	5cm	1.7cm
Left side	17.2mm	3.1mm	3mm	2.7mm
Right side	19.5mm	2.92mm	6mm	1.9mm

Table 2:

S. No	Gender	Presence	Side	Measurement of belly	Measurement of tendon	Shape
Cadaver 1	Male	Psoas minor	Right	16.8mm length 2.68 mm width	5mm length 1.7mm width	Slender

**Fig. 2:** Showing tendon of psoas minor attached to ilio pubic eminence on right side

of muscle belly were 13.6 ± 1.09 mm and 3.4 ± 0.39 mm, respectively.⁸

In the present study dissected 20 cadavers. Psoas minor was present in 3 cadavers. Psoas minor was present bilaterally in one cadaver, unilaterally in two cadavers.

Deepshika S et.al observed that it was present in 55.5%, bilateral in 22.2% cases, unilateral 33.3% cases. It was found anteromedial to psoas major, lateral to common iliac artery. It was showed a variation in distal attachment one case.⁹

Our study is similar to above study because distal attachment variable. I was found in one specimen.

Guerra.et.al dissected in 22 fetuses, it was present in 13, among these it was present bilaterally in 10 fetusus, unilaterally in 3 fetuses. The distribution of psoas minor was analysed according to sex and age.¹⁰

Jewel et al, stated that psoas muscle group is comprised long fusiform muscles-major, minor and tertius. Psoas major muscle is present in all individuals. Psoas muscle group have differences not only in their structure, morphology and innervation.¹¹

Sonali A observed that psoas minor was present in 40% of cadavers, bilateral in 35%, unilateral 5%, psoas accessories was found in unilaterally in 15% cases.¹²

5.1. Variations of origin

Mathew.et.al observed common variations of psoas minor muscle are related spinal level of origin. Typically it originates from thoracic vertebra T₁₂ & L₁. It can also originate from sub diaphragmatic fascia and medial arcuate ligament and crus of diaphragm. All the variations of psoas minor muscle having two heads observed in this study.⁷

In our study observed psoas minor in three specimens out of forty specimens. It arises from T₁₂ and L₁ vertebra.

In 1889 Clarkson and Rainy as described the psoas accessories arise from undersurface of tendon of psoas minor passes downward to fuse with internal surface of iliacus and psoas major muscle.⁸

In our study 40 hip specimens dissected in three specimens psoas minor muscles were inserted into iliopubic eminence.

5.2. Variations of insertion

Guerra et al. described variations of psoas minor tendon is inserted into pectineal line, neck of femur, lesser trochanter with iliopsoas, iliac fascia, inguinal ligament or pectineal ligament.¹⁰

Ojha et al. studied 30 cadavers, observed in five cases. Muscle belly was thick and tendon insertion was short, broad and attached to iliopubic eminence, pectin pubis. Tendon merges with obturator fascia medially and iliac fascia laterally. In three cases muscle belly is thin, tendon is long and fanned¹² (in this reference muscle belly is thin and tendon is long and fanned, in 3 cases).

Pamela D et al. observed that it is a obligatory muscle, arises as vertical fascicles inserted into last thoracic, first lumbar vertebrae iliopubic eminence.¹³

During the evolution, some muscles of the human body regress are called as vestigial muscles, which are recognized by their short belly and long tendon namely Palmaris longus in upperlimb, Plantaris in lowerlimb and Psoas minor in the trunk. Psoas minor is found only in 40- 60% of population. However, the incidence varies with race and ethnicity.

6. Conclusion

The Psoas minor is present only in 40- 60% of subjects. Hence, problems associated with Psoas minor can be an important in differential diagnosis for conditions like appendicitis and restriction of movements at the hip joint. Psoas minor can be affected as a result of sports injuries.

Therefore, awareness of its occurrence is essential to clinicians for proper diagnosis and treatment.

7. Source of Funding

None.


8. Conflict of Interest

The authors declare no conflict of interest.

References

1. Parveen O, Seema P, Anjali J. Morphology of Psoas minor muscle- a cadaveric study. *Int J Cur Res Rev*. 2016;8(16):35–9.
2. Roman's GJ. Cunningham manual of practical anatomy. vol. II. 15th ed.; 1986. p. 183.
3. Available from: <https://www.kenhub.com/en/library/anatomy/psoas-minor-muscle>.
4. Neeta VK. Clinical anatomy a problem solving approach. Jaypee Brothers Medical Publisher; 2011. p. 712.
5. Sinnatamby SC. Last's Anatomy, Regional & Applied. 12th ed. USA: Churchill Livingstone; 2011. p. 272.
6. Joshi SD, Joshi SS, Dandekar UK, Daimi SR. Morphology of Psoas minor & Psoas accessorius. *J Anat Soc India*. 2010;59(1):31–4.
7. Protas M, Voin V, Wang JMH, Iwanaga J, Loukas M, Tubbs RS. A Rare Case of Double-Headed Psoas Minor Muscle with Review of its Known Variants. *Cureus*. 2017;9(6):e1312.
8. Patil S, Ghosh S, Vasudeva N. Biometrics of Psoas Minor Muscle in North Indian Population. *J Surg Acad*. 2015;5(1):14–8.
9. Chaurasia B. Human anatomy regional and applied dissection and clinical. 8th ed. CBS Publishers & Distributors; 2019. p. 401.
10. Singh D, Agarwal S. Morphological Study of Psoas Minor Muscles with Embryological Basis and Clinical Insights. *J Clin Diagn Res*. 2021;15(4):AC10–4.
11. Guerra DR, Reis FP, Bastos AA, Brito C, Silva RJS, Aragão JA. Anatomical study on the psoas minor muscle in human fetuses. *Int J Morphol*. 2012;30(1):136–9.
12. Krasimir M, Dragieva P, Nikolova D, Stoyanov G, Zaharieva M, Kozhuharov Y, et al. Unilateral psoas minor: a case report. *Scripta Scientifica Vox Studentium*. 2017;1(1). doi:10.14748/ssvs.v1i1.4097.
13. Dragieva P, Zaharieva M, Kozhuharov Y, Markov K, Stoyanov GS. Psoas Minor Muscle: A Cadaveric Morphometric Study. *Cureus*. 2018;10(4):e2447.

Author biography

Deepthi Simhadri, Assistant Professor  <https://orcid.org/0000-0002-6840-4808>

T Navakalyani, Professor and HOD

D Suseelamma, Professor

Cite this article: Simhadri D, Navakalyani T, Suseelamma D. A study of psoas minor muscle morphology. *Indian J Clin Anat Physiol* 2021;8(3):166-169.