

## Sexual Dimorphism in Human Sacrum in Maharashtra Population

Renuka S. Ahankari<sup>1\*</sup>, M.P.Ambali<sup>2</sup><sup>1</sup>Associate Professor, Department of Anatomy, MIMSR Medical College & YCM Hospital, Latur, Maharashtra.<sup>2</sup>Professor, Department of Anatomy, Krishna Institute of Medical Sciences, Karad Dist. Satara**\*Corresponding Author:**

E-mail: adgaonkarrenuka36@gmail.com

**Abstract**

Identification of sex in human skeletal remains is a big challenge to the anatomists, forensic experts, and anthropologists. Human pelvis is one of the most important skeletal element in view of sex identification. The differences in male and female pelvis are attributed to the functional need at the time of parturition.

Like many other bones in the body, sacrum, which itself is a part of pelvis, can also be used to determine the sex amongst the skeletal remains. Greeks considered it as the last bone to decay after birth. Defining the criterias so as to identify male sacrum & female sacrum gains its importance not only in medicolegal but also in fixation surgeries of spine due to degenerative and traumatic conditions. So considering the importance of accurate knowledge of sex differences in male and female sacrum we decided to find out the best parameter and index which will identify the sex of a given sacrum with maximum accuracy.

To pursue this aim, we studied 150 Male and 150 Female sacra from Maharashtra population, by visiting different medical colleges. The parameters were measured & the indices were calculated. Then the results were compared with previous studies. A totally new index –Articular Index was introduced in our study. The ventral straight length, length of auricular surface, corpora-basal index, and articular index were found more reliable criterias to determine the sex of a given sacrum.

**Key words:** Articular index, Auricular Index, Corporo-basal Curvature index,

Access this article online	
Quick Response Code:	Website: www.innovativepublication.com
	DOI: 10.5958/2394-2126.2016.00022.0

**Introduction**

Sexual dimorphism in any human bone can be analyzed through following ways.

1. Visual morphological assessment.
2. Statistical methods (particularly when skeletal remains are few and poorly preserved) [17].
3. DNA analysis using amelogenin and Y markers (chances of failure are more as DNA is not always available & the results can be misinterpreted) [13].

Following is a statistical analysis of Sexual dimorphism as seen in human bones with varying degree of accuracy [15].

Bone	Accuracy of Sex identification
1. Skull + Femur	97.35%
2. Coccyx + Sacrum	97.18%
3. Pelvis	95%
4. Femur	39.84%
5. Atlas	31.18%

In our study we aim at studying differences in features of Male & Female sacrum, by analyzing them


statistically as it is seen that comparatively much less studies have been done on Sacrum as a separate bone. [6]. These differences can serve as a guide while performing implementation of orthopaedic instruments in the correction of spine instability due to degenerative and traumatic conditions [1].

**Material and Methods**

For the present study, 150 male and 150 female adult sacra were taken. All the bones were fully ossified, dry and without any damage or deformity.

The bones were obtained from different Medical Colleges of Maharashtra in the Department of Anatomy of each college.

**Instruments:** Sliding Vernier Caliper & Standardized flexible steel tape (as shown in the figure below) were used for the measurement of various parameters.



(A: Sliding Vernier Caliper, B: Sacrum, C: Standardized flexible steel tape)

In order to avoid observer's error, all the parameters were measured and recorded single handedly & all the measurements were recorded in millimeters. Each of the parameters was measured three times and then their mean was taken as the final reading.

### 1. Maximum Length of Sacrum – Mid-ventral straight length of Wilder.

It was measured along the midline of sacrum with the sliding vernier caliper from middle of antero-superior margin of promontory to middle of antero-inferior margin of last sacral vertebra.




Fig. 1: Distance between points A & B

### 2. Maximum Width of Sacrum –

By using sliding caliper, two points were taken at the lateral most part of alae of sacrum at the upper part of auricular surface and the distance was measured along anterior aspect of sacrum at the level of 1st sacral vertebra. It was recorded in millimeters.

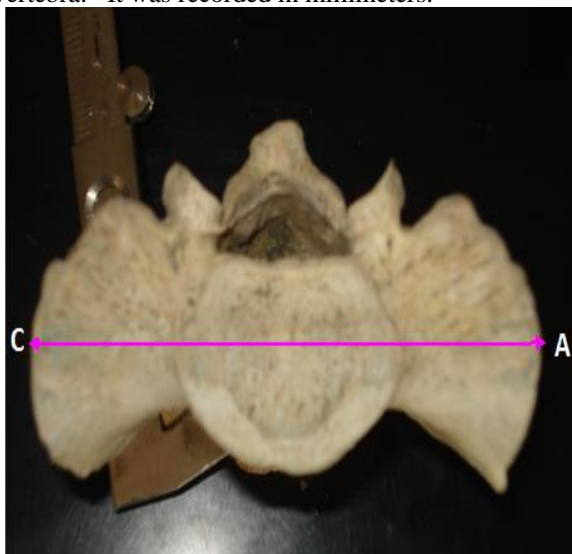

Fig. 2: Distance between points C & D

### 3. Sacral Mid-ventral Curved Length

It was measured a point in the middle of antero-superior border of sacral promontory to another point in the middle of antero-inferior border of 5<sup>th</sup> sacral vertebra.

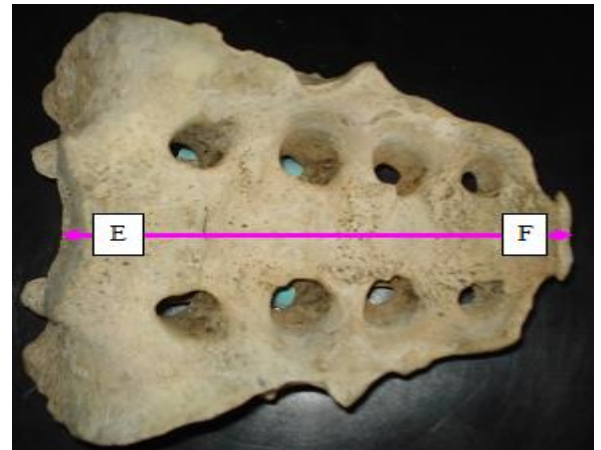


Fig. 3: Distance between points E & F.

### 4. Transverse Diameter of Body of 1st Sacral Vertebra.

It is the maximum transverse diameter of 1st sacral vertebra measured by taking one point on each side of lateral most point on superior surface of body of 1st sacral vertebra. It is also recorded in millimeters by using caliper.

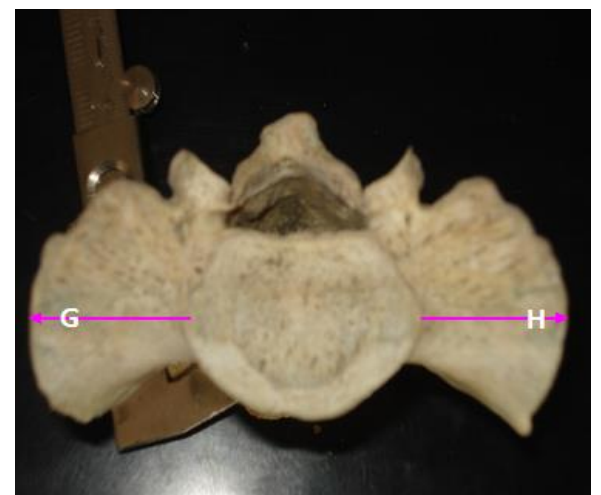

Fig. 4: Distance between points G & H.

### 5. Width of Articular Surface

It is measured by taking one point on the maximum convexity on anterior margin of the auricular surface which is somewhat inverted L shaped ( $\Gamma$ ) and another diagonally opposite point on its concave margin; which corresponds with its posterior margin. Both side measurements are taken and mean of them is taken as the final reading.

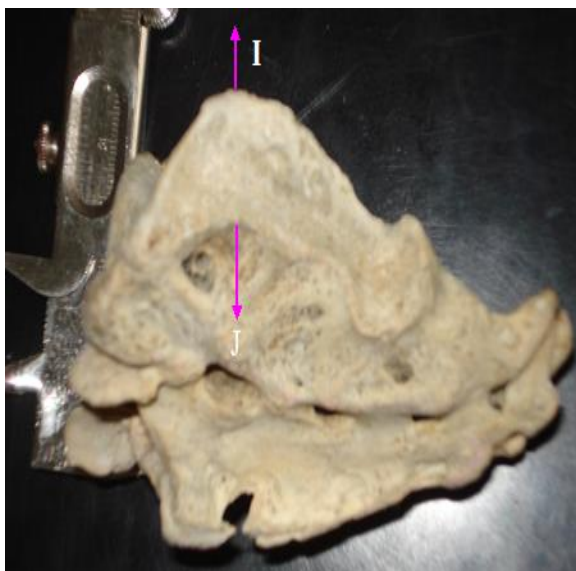


Fig. 5: Distance between points I & J

**6. Maximum Length of Articular surface**

It was recorded as the distance between a point on the upper most part of auricular surface [Highest point of (summit) inverted 'L (r)] and another point on the lower most part of the auricular surface.

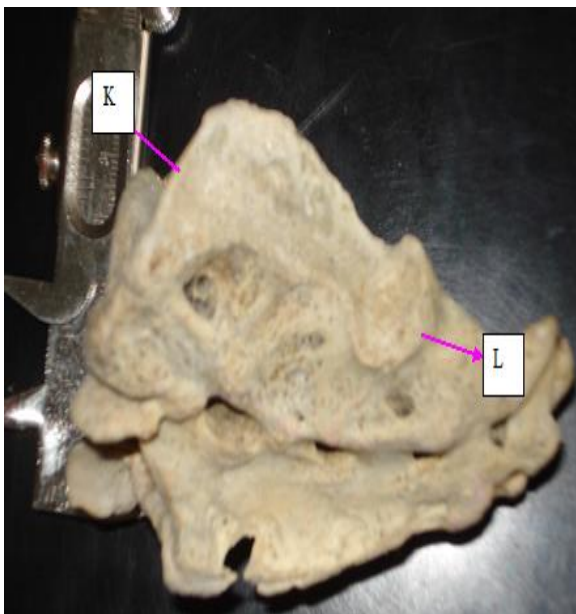


Fig. 6: Distance between points K & L

By using these different parameters, following indices are calculated by using different formulae as stated below:-

1. Curvature Index:-  

$$\frac{\text{Straight length}}{\text{Mid ventral curved length}} \times 100$$
2. Corporo-basal Index -  

$$\frac{\text{Transverse diameter of Body of S}_1}{\text{Width of Sacrum}} \times 100$$
3. Auricular Index:-  

$$\frac{\text{Length of Auricular surface}}{\text{Width of Sacrum}} \times 100$$

In addition to above indices which were studied by S.R. Mishra etal [2003]<sup>59</sup> following new index was added in the present study –

1. Articular Index -  

$$\frac{\text{Width of articular surface}}{\text{Length of articular surface}} \times 100$$

The articular surface of sacrum is nothing but its auricular surface, which articulates with ilium to form sacro-iliac joints. This is the area which is mainly involved in weight transmission and it is also important in sliding movements during parturition in females. So the ratio between width of this articular surface on both sides and that of their length is calculated.

**Statistical Methods**

After completing measurements they were tabulated and analyzed by statistical methods which included univariate statistics and discriminant function analysis.

A standard computer program was used to analyse the data. The data was summarized into range (minimum- maximum), mean and standard deviation sex wise. Comparison of each study factor was done by applying Student's 't' test (unpaired). To determine the demarcating point i.e. the point which will find whether the sacrum is of male or female, mean ± 3SD (Standard Deviation) range was obtained. Considering the range of male, female demarcating point was determined while considering the range of female, male demarcating point was determined.

## Observations

Our observations are tabulated as below -

Sr No.	Parameter	Sex	Range	Mean	S.D.	't' Value	P Value	D.. P.	% of bones Id. By D.P.
1.	Straight Length of sacrum	M	89-123	107.41	5.62	17.82	<0.001	>118.1	<b>39</b>
		F	68-119	92.57	8.51			<90.55	<b>27</b>
2	Width of sacrum	M	90-118	101.15	5.4	1.578	>0.05	Can't be obtained	-----
		F	87.5-116.6	104.12	5.93				-----
3	Transverse Dia. Of S1	M	36.1-57	46.78	3.96	7.411	<0.001	>56.88	<b>20</b>
		F	31.6-54	43.11	4.59			<34.9	<b>0</b>
4	Curved Length of Sacrum	M	96-134	116.48	5.93	6.984	<0.001	>134.21	<b>8</b>
		F	91-130	110.89	7.80			< 98.69	<b>0</b>
5	Length of auri. part of lat.surface	M	43.4-64.25	54.65	3.82	17.395	<0.001	>58.47	<b>16.7</b>
		F	36.8-56.2	46.95	3.84			<43.17	<b>16</b>
6	Width of non-auricular part of lat. surface	M	14.55-31.35	21.76	2.99	1.653	>0.05	Can't be obtained	-----
		F	14.55-30.25	22.32	2.80				-----
7	Curvature index	M	82.98-112.55	92.36	5.50	14.757	<0.001	> 98.26	<b>14.7</b>
		F	64.15-94.18	83.47	4.93			< 75.86	<b>5.3</b>
8	Corporobasal Index	M	34.7-53.58	44.57	4	7.054	<0.001	>52.69	<b>10.2</b>
		F	31.13-50.85	41.41	3.76			<32.57	<b>7</b>
9	Auricular index	M	40.19-65.50	52.07	4.3	14.690	<0.001	>56.64	<b>15.3</b>
		F	33.45-55.26	45.18	3.82			<39.17	<b>7.3</b>
10	Articular index	M	25.41-56.49	39.97	5.66	10.98	<0.001	< 27.89	<b>0</b>
		F	<b>32.59-66.98</b>	<b>47.78</b>	<b>6.63</b>			> <b>56.95</b>	<b>21.05</b>

Thus from above table it is clear that ventral straight length of sacrum, curved length of sacrum, transverse diameter of Ist Sacral vertebra are the parameter's which can identify male sacrum more accurately whereas width of sarum, width of auricular surface of lateral mass are the parameters which are not significant statistically i.e. they are unable to classify the sacrum into a male or a female sacrum. Amongst the indices curvature index, corpora-basal index & auricular index are stronger to identify male sacra whereas articular index can identify female sacra more accurately.

## Discussion

The ventral straight length of sacrum shows higher degree of sexual dimorphism as proven statistically. In our study, it shows higher values in the males. Our findings co relate with most of the workers [5,8,9,12,13]. There are variable findings about Mid ventral curved length of Sacrum. The workers like Dhapate[5] & Siddiqui[12] found it statistically significant, with higher values in males. Tague[14] found it insignificant whereas Flander[6] found it significant only in Black races but not in white races.

According to Plochocki, J. H. [7], whose findings correlate with us, although sexually dimorphic, metric observations of sacral curvature are not as reliable at predicting sex as other skeletal elements. Anterior sacral curvature should only be used for sex estimation in the absence of other, more reliable, indicators. The maximum width of sacrum is not significant statistically, as found by almost all the workers including our study, although our mean values are higher than Davinongs [4] but lower than Siddiqui A [12], & Raju etal[9].

We found that the transverse diameter of body of Ist sacral (S<sub>1</sub>) vertebra is a statistically highly significant parameter in sexing the sacrum with higher mean value in males than females. The findings in present study are much nearer to the findings of Rajderkar S.S.[10] Dhapate [5 ].

The mean transverse diameter of body of Ist sacral vertebra is lower than the findings of both Davinongs [4] & Flander L. [6]. The mean values of the length of auricular surface of lateral mass of sacrum, are higher in males and that of width of auricular surface of lateral mass of sacrum are higher in females.

Following table shows comparison of our study with various other workers:

Sr. No.	Authors Parameter in mm.	Davinongs (4) 1963		Raju etal (91) 1980		Rajderkar S.S. (8) 1992.		Dhapate (5)1993		Siddiqui A (12)2000		Mishra et al 2003 (135)		Present Study 2008	
		M	F	M	F	M	F	M	F	M	F	M	F	M	F
1	Straight length	96.5	88.1	104.9	92.7	108.4	98.73	101.1	91.8	104.9	91.1	107.53	90.58	107.41	92.57
2	Maximum width of Sacrum	99.9	101.1	105.3	103	105.1	104.4	104.7	103.3	102.9	103.9	105.34	105.79	101.2	104.12
3	Curved Length of Sacrum	104.3	97.1	112.7	104.8	113.45	104.8	107.2	99.2	104.9	103.9	119.56	100.95	116.48	110.89
4	Tra. Dia. Of S1	47.4	44.1	47.3	42.1	46.11	41.9	45.4	40.1	49.2	42.2	49.12	42.81	46.78	43.11
5	Length of auri Part of lat surface.	-	-	-	-	-	-	-	-	-	-	62.54	54.57	54.65	46.95
6	Width of auri Part of lat surface	-	-	-	-	-	-	-	-	-	-	-	-	21.76	22.32
7	Curvature Index	92.54	90.80	92.77	88.51	95.66	94.27	-	-	106.02	114.42	95.22	90.72	92.36	83.47
8	Corporobasal Index	47.42	43.62	44.92	40.96	44.08	40.15	-	-	-	-	46.54	40.47	44.57	41.41
9	Auricular index	-	-	-	-	-	-	-	-	-	-	59.78	51.69	52.07	45.18
10	Articular index	-	-	-	-	-	-	-	-	-	-	-	-	39.97	47.78

Amongst the indices, the mean values of curvature index, corporobasal index, auricular index are higher in males whereas the Articular index a new index in our study, [which probably is studied for the first time] is significantly higher in the females.

Although it was found that width of auricular (articular) surface is not significant statistically, the articular index is significantly higher in females as

compared to males. The mean values for articular index for males and females are respectively:- 39.97 mm & 47.78 mm. The demarcating point tells us that any sacrum with articular index < 27.89 is a male sacrum and the one with articular index > 56.95 is a female sacrum. Thus this new index may prove to sex the sacra accurately.

#### Articular Index

	Investigators	Male				Female				(S.S.D.)
		N	X	Range	S.D.	N	X	Range	S.D.	'p' value
1	Present Study	150	39.97	25.41-56.49	5.66	150	47.78	32.59-66.98	6.63	< 0.001

Key:

N = Number of specimen

X = Mean

S.D. = Standard Deviation

S.S.D. = Statistical Significance ('p' value)

## Summary & Conclusion

In the present study we have studied 150 male and 150 female sacra gathered from various medical colleges in Maharashtra.

The parameters were:

- 1] Ventral Straight length, 2]Mid ventral curved length,
- 3] Maximum width of sacrum
- 4] Transverse diameter of Body of Ist sacral vertebra,
- 5]Length of Auricular surface and
- 6] Width of auricular surface

The indices were 1] Curvature index, 2]Corporo-basal index, 3] Auricular index & 4] Articular index

Out of these, except width of sacrum and width of auricular surface all were found statistically significant. The present study shows that certain parameters are much useful as far as the sex identification of sacrum is concerned, while certain other parameters are either less significant or absolutely insignificant.

Hence it can be concluded that to sex the sacra with 100% accuracy, a single most parameter is not useful instead it requires that multiple parameters & indices to be applied & tested on each of the given sacrum to reach at a more correct result. [1].

The variable figures of same parameter or index in different areas or races tell us that anthropometric standards, although studied in past extensively need to be evaluated from time to time as external influences like physical stress, life style, and nutrition are always changing.[6-8]

## Acknowledgement

The authors are thankful to the H.O.D.S of Department of Anatomy of various colleges in Maharashtra for they allowed us to use the necessary material for our research.

We are equally thankful to Dr.S.V.Kakade, statistician, Dept. Of Preventive and Social Medicine, Krishna Institute Of Medical Sciences, Deemed University, Karad, for his valuable help in carrying out the task of statistical analysis of the data.

We convey our sincere thanks to Mr.Gaikwad, Mrs. Sawant for helping us in designing & printing of our work.

## Conflict of Interest: None

## Source of Support: Nil

## Bibliography

1. Basaloglu H., Turgut M., Taser FA, Cevlan T, Basaloglu HK, Sevlan AA. Morphometry of the sacrum for clinical use. *Journal of Surg. Radiol. Anat.* 2005; (6): p. 467 – 71.
2. Charnalia VM. Sex differences and determination in human sacra in South India. *Journal of Anatomical Society Of India* 1967; (1); p. 33.
3. Chaurasia BD. *Human anatomy.* 2005; Vol.2, 4<sup>th</sup> Edition; P.. 187.

4. Davinongs V. The pelvic girdle of the Australian Aborigine, sex differences and sex determination. *AmJ. Phys. Anthropol.* 1963; 21 (4):p. 443 – 455.
5. Dhapate [Determination of sex from dry Sacra in Marathwada Region.1993. p.67.
6. Flander L. Univariate and Multivariate methods for sexing the sacrum. *Amj. Phys. Anthropol.*1978; 49: p. 103-110.
7. Plochocki, J. H. Sexual Dimorphism of Anterior Sacral Curvature. *Journal of Forensic Sciences.* 2011;56: p. 161–164.
8. Rajderkar S.S. Sex Determination in Sacrum.1992; p.84..
9. Raju P.B.,Singh S. and R. Padmnabhan. Sex determination and sacrum. *Journal of Anat. Society of India.*1980; 30:p. 13-15.
10. Sahana S.N. *Human Anatomy Description and Applied.*1980; Central Book Agency Calcutta. P.. 278-284.
11. Santiago Safont, Assumpcio, Malgesa & M. Eulalia Subira Sex assessment on the basis of long bone circumference. *Amj. Phy. Anthropology.*2000; 113: p.317-328.
12. Siddiqui A. Sexing Sacrum by Multivariate Analysis 2000. p78
13. S.R. Mishra, Singh PJ, Agarwal a, Gupta KN. Identification of sex of sacrum of Agra Region. *Journal of Anat. Society of India.* 2003; 52: p.132-136.
14. Tague Robert G. Variation in the pelvic size between males and females. *Amj. phys. Anthropol.*1989; 80 :p.59-71
15. Taylor. *Principles and practice of Medical Juris prudence* 11<sup>th</sup> Ed. Sir Sydneyp.150.
16. Vinod Kumar, G.S. Longia, P.N. Jain. Anthropometrical Study of Human Sacrum *Journal of Anatomical Society of India.*1984; 33:p.57
17. Vark G.N. Van, Schafsma W. Advanced quantitative analysis of skeletal morphology.1992 p.153-56.
18. Weist H. The auricular surface of the sacroiliac joint and their relation to the movements of the sacrum. *Acta Anat.*1954; 22: 1-14.
19. Williams & Warwick *Grays Anatomy.*1989. 37<sup>th</sup> edition; p.432-433.