

A Study of Morphometric Variations of Celiac Trunk Using Computed Tomographic Angiography

Hamzah M. Hafezji^{1,*}, Deepa S. Gupta²

¹Tutor cum Resident, ²Professor and Head, Department of Anatomy, SMIMER Surat

*Corresponding Author:

E-mail: dr.hamzah_786@yahoo.com

Abstract

Aims and Objectives: Evaluate the normal anatomy of celiac trunk and prevalence of anatomical variations of celiac trunk in the South Gujarat population.

Materials and Methods: Total 50 subjects irrespective of age and sex, who underwent CT angiography of abdominal aorta for medical or surgical indications, were selected for the study. Subjects allergic to contrast medium or having history of malignancy or previous abdominal surgery or aorto-arteritis were excluded from the study. The angiography images were obtained using spiral CT scanner from department of radio-diagnosis of Surat Municipal Institute of Medical Education and Research (SMIMER) and reformatted as 3D images to evaluate celiac arterial anatomy and its variations with respect to level of origin, length, diameter and branching pattern.

Results: Variation in the vertebral level of origin of celiac trunk was observed in about 60 % cases. The length and dimensions of the trunk also displayed a wide range of variation. Variant branching patterns are found in 32 % of subjects with bifurcation of celiac trunk into splenic and common hepatic arteries and left gastric arises from some different sources.

Conclusion: The knowledge of morphometric variations of celiac trunk is indispensable for diagnostic and operative procedures of abdomen. Without a thorough understanding of the arterial architecture and the knowledge of variations, surgery may carry a considerable risk leading to lethal complications. A high celiac trunk may lead to its compression. Variation in branching pattern is considerably important in hepato-biliary surgery and chemo-embolization for malignancy.

Key words: Angiography, celiac trunk, computerized tomography, variation.

Access this article online	
Quick Response Code:	Website: www.innovativepublication.com
	DOI: 10.5958/2394-2126.2016.00021.9

Introduction

The celiac trunk, the first ventral branch of aorta, arises below the aortic opening of diaphragm at the level of intervertebral disc between T12 & L1 vertebrae. It is about 1.5-2 cm long, passes forward and to the right and divides into left gastric artery (LGA), common hepatic artery (CHA), and splenic artery (SA). This classical trifurcation as hepato-gastro-splenic trunk is known as the 'Tripus halleri'. The celiac trunk and its branches supply the derivatives of foregut which includes gastrointestinal tract from the distal third of the esophagus up to the hepato-pancreatic ampulla in the second part of the duodenum and also derived adnexae which includes liver, biliary tree, spleen, dorsal pancreas, greater omentum, and lesser omentum.

The celiac trunk is subjected to morphological variability. Previous studies have suggested variations with respect to level of origin, dimensions, branching pattern of celiac trunk.^{2,3} Various studies suggested different level of origin of the celiac trunk at the

vertebral level T-12,⁴ at the T12-L1 disc level⁵ and at the T11-T12 disc level.⁶ The length and diameter also show variability; length ranging from 5 mm to 40 mm has been reported by Rio Branco,⁷ 10 mm to 20 mm by Tandler,⁸ and 10 mm to 15 mm by LaserJet and Ruiz-Liard.⁹ The diameter was found ranging from 4 mm to 10 mm,⁷ 10 mm to 12 mm,¹⁰ and 6 mm on average.⁹

Studies have also suggested anomalies in the branching pattern of the celiac trunk which include other patterns of branching besides classical trifurcation. One of the branches of the celiac trunk may sometimes arise directly from the abdominal aorta. On rare occasions, the celiac trunk may be completely absent and all three branches then originate independently from the aorta.^{19, 21}

Owing to recent advances in the technology of spiral and multi-detector computed tomography, thin-section dynamic CT has replaced conventional angiography for preoperative imaging.¹¹ Rawat has commented that multislice CT is an excellent modality for pre-operative evaluation of vascular anatomy and also it is safe, cost effective, time saving, and highly accurate.¹²

Therefore, in the present study to evaluate the normal anatomy and variants of the celiac trunk, computed tomographic angiography has been used.

Materials and methods

The present retrospective study was carried out after approval of institutional ethical committee in the Departments of Anatomy and Radio diagnosis, of Surat

Municipal Institute of Medical Education and Research (SMIMER), Surat, Gujarat. The study included 50 subjects (30 males and 20 females) who underwent the computed tomographic angiography of the abdominal aorta, for medical or surgical indications during October, 2014 to September, 2015. Scans of subjects having history of malignancy or previous abdominal surgery or aorto-arteritis and other collagen vascular diseases were excluded from the study as these factors are likely to distort the vascular anatomy.

The angiography images were obtained using spiral CT scanner machine. With the help of computer software utilizing various image processing techniques, the images are reformatted as 3D images, volume rendered images (VR) and maximum intensity projections (MIP) to evaluate celiac arterial anatomy and its variations with respect to level of origin, length, diameter and branching pattern. The axial images were used for final confirmation of variant anatomical findings.

Observations and results

[A] Variations in Level of origin: (Figs. 1 [a]-[d]).

The celiac trunk was found to arise at various levels ranging from the T-12 vertebral level to L-1 & L-2 disc level. The site of origin of the celiac trunk in majority (40 %) is T-12 vertebral level [Fig. 1(b)]. The celiac trunk originated opposite the T-11 & T-12 disc level in 12 % [Fig. 1 (a)], opposite the T-12 & L-1 disc level 32 % [Fig. 1 (c)], at the L-1 vertebral level in 12 % [Fig. 1 (d)] and L-1 & L-2 disc level in 4 % cases. The findings are depicted in Table 1.

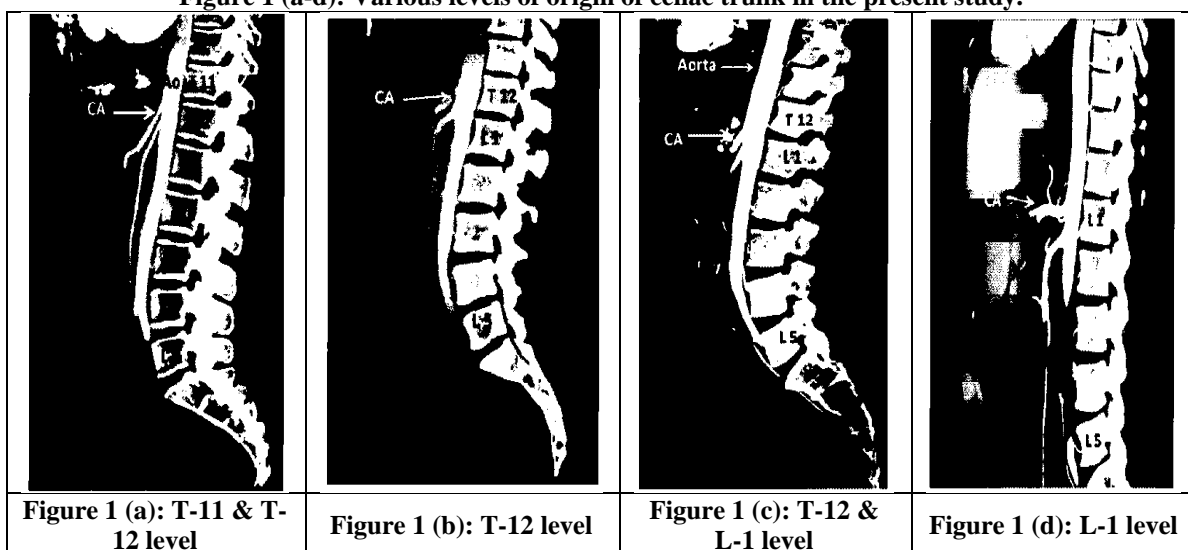
[B] Variations in length and diameter:

The length of the celiac trunk was measured from the point of its origin from the aorta up to the origin of its first branch. The length of the celiac trunk was found to range between 8 mm and 26 mm. The diameter of the celiac trunk was measured in its first centimeter near its origin. The diameter of the celiac trunk was found to range between 4 mm and 9 mm.

Table 1: Level of origin of celiac trunk in the present study

Vertebral level of origin	Males n = 30	Females n = 20	Total n = 50	Percentage
T 11 – T 12	2	4	6	12 %
T 12	12	8	20	40 %
T 12 – L 1	11	5	16	32 %
L 1	4	2	6	12 %
L 1 – L 2	1	1	2	4 %

Figure 1 (a-d): Various levels of origin of celiac trunk in the present study.



[C] Variations in branching patterns : (Figs. 2 [a]-[e])

Among the 50 subjects studied, trifurcation was found in 68% [Fig. 2 (a)] and the rest 32 % displayed other patterns of branching. The observed prevalence is depicted in Table 2.

The variant branching pattern includes bifurcation of celiac trunk into common hepatic and splenic arteries while left gastric arise from some other sources [Fig. 2 (b-e)]. The different sources of left gastric artery are depicted in Table 3.

Table 2: Prevalence of branching pattern of celiac trunk in the present study

Celiac trunk morphology	Males	Females	Total	%age
	n = 30	n = 20	n = 50	
Classical trifurcation	21	13	34	68 %
Variant branching patterns	9	7	16	32 %

Table 3: Different sources of origin of left gastric artery in present study

Source of left gastric artery	Number of cases	Percentage
Aorta	3	6 %
Upper surface of celiac artery	8	16 %
Common Hepatic artery	3	6 %
Superior mesenteric artery	2	4 %
Total	16	32 %

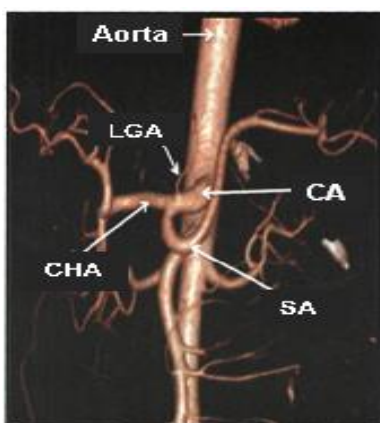


Fig. 2 (a): Trifurcation of celiac trunk (CA) into left gastric (LGA), splenic (SA) and common hepatic (CHA) arteries.

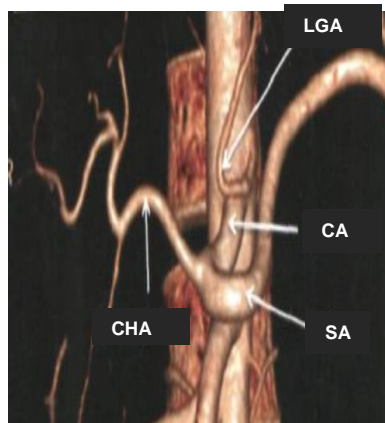


Fig. 2 (b): Bifurcation of celiac trunk (CA) with left gastric artery (LGA) from aorta

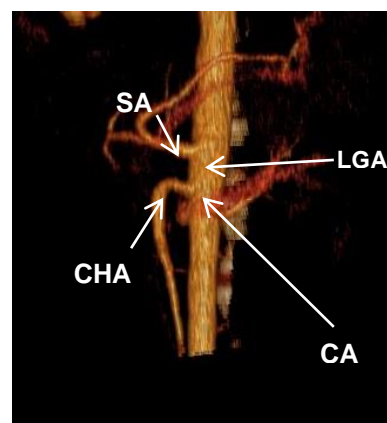


Fig. 2 (c): Bifurcation of celiac trunk (CA) with left gastric artery (LGA) from upper surface of celiac artery

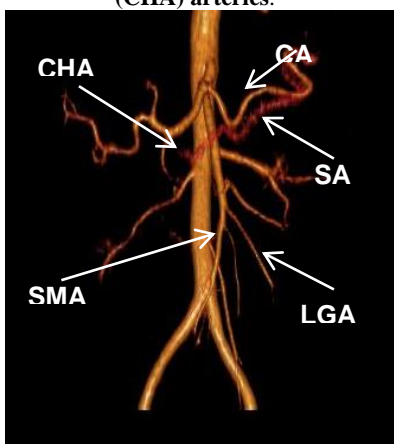


Fig. 2 (d): Bifurcation of celiac trunk (CA) with left gastric artery (LGA) from superior mesenteric artery(SMA)

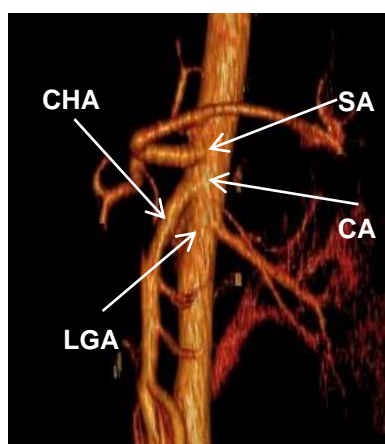


Fig. 2 (e): Bifurcation of celiac trunk (CA) with left gastric artery (LGA) from common hepatic artery (CHA).

Figure 2 (a-e): Variation of branching pattern of celiac trunk.

Table 4: Variations in the level of origin and dimensions of celiac trunk in different studies

	Vertebral Level of Origin	Diameter (in mm)	Length (in mm)
Present study(CT angiography)	T12 to L1-L2	4 - 9	8 - 26
Moncada et al ¹⁶ (CT abdomen)	T12 to L1	8 - 16	8 - 22
Latarjet et al ⁹ (Cadeveric Study)	T12 to L1-L2	8 - 12	6 - 24
Garima Sehgal et al ¹⁰ (CT angiography)	T11-T12 to L1	4 - 10	6 - 22
Wadhwa et al ¹⁵ (Cadeveric study)	T12 to L1	6 - 14	6 - 20

Table 5: Variations in the branching pattern of celiac trunk in different studies

Study by	Trifurcation of celiac trunk (%)	Absent celiac trunk (%)	Other branching patterns (%)
Present study	68	-	32
Winston et al ¹⁸	51	-	49
Vandamme et al ¹	86	-	14
Garima et al ¹⁰	28	4	68
Iezzi et al ¹⁷	72	-	28
Rossi et al ²¹	68	2	26

Discussion

The celiac trunk is the chief artery of the foregut and through its branches, namely left gastric, common hepatic, and splenic arteries, it supplies the primary organs of the supra-colic compartment of abdomen which includes the stomach, pancreas, duodenum, spleen, and liver.¹³ Knowledge of variations of celiac trunk is important in the accurate interpretation of disease in diagnostic imaging as well as in deciding the optimum elective procedure in surgical or interventional radiological management.¹⁴

In the present study, the celiac trunk displayed origin at various levels ranging from T-11 & T-12 disc level to L-1 & L-2 disc level. Similar variations of origin have been previously reported by authors with varying frequencies of origin at different levels.^{5,6,15}(Table-4). Variation in the level of origin requires individualization of treatment plan for carcinoma of stomach, pancreas and the hepato-biliary tree as the lymph nodes at risk lie adjacent to this vessel. A high celiac trunk origin may lead to the celiac axis compression syndrome (CACS) characterized by intense postprandial epigastric pain, nausea, and vomiting.

In the present study, the length of celiac trunk was found to range between 8 mm and 26 mm which correspond to the findings of Moncada et al,¹⁶ who reported length between 8mm and 22 mm. The diameter of the celiac trunk was found to range from 4 mm to 9 mm which corresponds with findings of Garima Sehgal et al¹⁰ who reported diameter between 4 mm and 10 mm. (Table 4)

In the present study, the prevalence of trifurcation was high(68%) which corresponds with findings of Rossi et al (68%). It is lower than findings of Vandamme and Bonte,¹(trifurcation in 86% cases in an angiographic study) and Iezzi et al,¹⁷ (trifurcation in 72.1 % cases by multidetector row CT angiography) while it is higher

than findings of Winston et al,¹⁸ (trifurcation in 51% cases) and Garima Sehgal et al (trifurcation in 28 % in a CT angiographic study). (Table 5)

In the present study, any case of absence of celiac trunk was not found. Yamaki et al¹⁹ suggested that there are scanty reports of the absence of celiac trunk in the literature. Various types of studies including cadaveric, angiographic and intraoperative observations reported a prevalence of absence of celiac trunk ranging between 0.1 %²⁰ and 2%.²¹ Garima Sehgal et al¹⁰ reported a higher prevalence (4%) of absence of celiac trunk (Table 5).

The arterial supply of the GI tract develops in 4th week of embryonic life. The future blood vessels of the GI tract are formed from the vitelline system which is composed of bilateral arterial plexuses which coalesce to form arteries from the dorsal aorta to the GI tract. The anatomical variation in the celiac trunk is assumed to be caused by different patterns of vitelline reduction.

Vascular anomalies are usually asymptomatic but may become important in patients undergoing diagnostic angiography for GI bleeding, interventional surgical procedures, or prior to an operative procedure or transcatheter chemo-embolisation therapy.²² Arterial variations should be taken care of during the abdominal operative procedures on the stomach, duodenum, and pancreas.²³ Variations of the celiac trunk must be carefully understood in anastomosing the proper arteries in the liver. Pre-surgical planning of vascular anastomosis and variations is a key component for a variety of liver surgeries, including transplantation, tumor resection, and laparoscopic hepatobiliary surgery.²⁴

The knowledge of anatomic variants also helps in successful accomplishment of surgical interventions such as lymphadenectomy around the hepato-spleno-mesenteric trunk, aortic replacement with re-

implantation of the trunk, or chemoembolization of liver malignancies, all of which can potentially create significant morbidity because of the large visceral territory supplied by a single vessel.²⁵

Conclusion

Therefore, the precise knowledge of variations of celiac trunk is indispensable to avoid intra-operative complications and for successful completion of surgical, oncological and interventional procedures. Without a thorough understanding of the arterial architecture and knowledge of the variations present, surgery may carry a considerable risk leading to lethal complications.

Conflicts of Interest: The authors declare that they have no conflicts of interest.

Source of Support: Nil

References:

- Vandamme JP, Bonte J. The branches of the celiac trunk. *Acta Anat (Basel)* 1985; 122:110-4.
- Kahraman G, Marur T, Tanyeli E, et al. Hepatomesenteric trunk. *Surg Radiol Anat* 2001; 23:433-5.
- Sahani D, Mehta A, Blake M, et al. Preoperative hepatic vascular evaluation with CT and MR angiography: implications for surgery. *Radiographics* 2004; 24:1367-80.
- Michels NA. Observations on the blood supply of the liver and gallbladder (200 dissections), In: *Blood Supply and Anatomy of the Upper Abdominal Organs, with a Descriptive Atlas* Philadelphia: Lippincott, 1955:139-40.
- Warter J, Storck D, Kieny R, et al. La maladie phreno-coeliaque. *Ann Radiol (Paris)* 1976; 19:361-70.
- Reuter SR. Accentuation of celiac compression by the median arcuate ligament of the diaphragm during deep expiration. *Radiology* 1971; 98:561-4.
- Rio Branco P. *Anatomia et medicine operatoire du tronco coeliaque en particulier de l'artere hepatiche* Paris: G Steinheil, 1912:818.
- Tandler J. *Tratado de anatomia sistematica* vol 3, Barcelona: Salvat Editores, SA, 1929.
- Latarjet M, Ruiz-Liard A. *Anatomia Humana* 2nd edn, vol 2, Sao Paulo: Medicina Panamericana Editora do Brasil Ltda, 1989.
- Garima S, A. K Shrivastava, Morphometry of celiac trunk: a multidetector computed tomographic angiographic study, *JASI* 2013;62:23-27.
- Lee SS, Kim TK, Byun JH, et al. Hepatic arteries in potential donors for living related liver transplantation: evaluation with multi-detector row CT angiography. *Radiology* 2003; 227:391-9.
- Rawat KS. CT angiography in evaluation of vascular anatomy and prevalence of vascular variants in upper abdomen in cancer patients. *Indf Radiol Imag* 2006; 16:457-61.
- Charbon GA, Anderson MF. Hepatic haemodynamics as related to blood flow through gut, spleen, and pancreas. *Gut* 1989; 30:265-78.
- Oran I, Yesildag A, Memis A. Aortic origin of right hepatic artery and superior mesenteric origin of splenic artery: two rare variations demonstrated angiographically. *Surg Radiol Anat* 2001; 23:349-52.
- Wadhwa S, Soni S. A composite study of coeliac trunk in 30 adult human cadavers—its clinical implications. *Global f Med Res* 2011; 11:35-8.
- Moncada R, Reynes C, Churchill R, et al. Normal vascular anatomy of the abdomen on computed tomography. *Radiol Clin North Am* 1979; 17:25-37.
- Iezzi R, Cotroneo AR, Giancristofaro D, et al. Multidetector-row CT angiographic imaging of the celiac trunk: anatomy and normal variants. *Surg Radiol Anat* 2008; 30:303-10.
- Winston CB, Lee NA, Jarnagin WR, et al. CT angiography for delineation of celiac and superior mesenteric artery variants in patients undergoing hepatobiliary and pancreatic surgery. *AJR Am J Roentgenol* 2007; 189:13-9.
- Yamaki K, Tanaka N, Matsushima T, et al. A rare case of absence of the celiac trunk: the left gastric, the splenic, the common hepatic and the superior mesenteric arteries arising independently from the abdominal aorta. *Ann Anat* 1995; 177:97-100.
- Song SY, Chung JW, Yin YH, et al. Celiac axis and common hepatic artery variations in 5002 patients: systematic analysis with spiral CT and DSA. *Radiology* 2010; 255:278-88.
- Rossi G, Cova E. Studio morfologico delle arterie dello stomaco. *Arch Ital Anat Embryol* 1904; 3:485-526.
- Yalcin B, Kocabiyik N, Yazar F, et al. Variations of the branches of the celiac trunk. *Gulhane Tip Dergisi* 2004; 46:163-5.
- Chitra R. Clinically relevant variations of the coeliac trunk. *Singapore Medf* 2010; 51:216-9.
- Van Thiel DH, Wright HI, Fagiuoli S, et al. Preoperative evaluation of a patient for hepatic surgery. *J Surg Oncol Suppl* 1993; 3:49-51.
- Losanoff JE, Millis JM, Harland RC, et al. Hepato-spleno-mesenteric trunk. *J Am Coll Surg* 2007; 204:511.