

Anatomy museums of southern India and medical education: An original research

Venkatesh Kamath^{1,*}, Shivarama Bhat², Muhammed Asif³, Ramakrishna Avadhani⁴

¹Assistant Professor, ²Professor, ³Lecturer, ⁴Professor and Head, Department of Anatomy, Yenepoya Medical College, Yenepoya University, India.

*Corresponding author

E-mail: drvenkateshkamath@gmail.com

Abstract:

Introduction: It is now mandatory for every medical college to have an anatomy museum and the purpose of this study was to analyse the role of anatomy museums in medical education in southern India.

Methods: To achieve this objective sixteen anatomy museums across southern India were selected from reputed medical colleges and all aspects of the museum were studied from specimen preparation and preservation techniques to labelling, mounting, and display of specimens using a proforma.

Results: It was observed that all the anatomy museums were well maintained and had a huge collection of anatomical specimens arranged in diverse sections such as gross anatomy, evolutionary anatomy, comparative anatomy, cross sectional anatomy, embryology, teratology and plastination. Two museums also had a section for learning within the museum.

Conclusion: The study shows that the anatomy museums in medical colleges across south India are well established and play a significant role in medical education. It also provides an insight into the current status of anatomy museums in the country and scope for their improvisation. The modern pedagogic practises are becoming more virtual and digitalized and several modern international museums are now digitalised and this was lacking in all the museums. The author believes that the anatomists should utilise the advances in computer and audio-visual aids to upgrade the museums to international standards.

Key words: Anatomy museums; Digitalisation; Medical education; Museum techniques.

Access this article online	
Quick Response Code:	Website: www.innovativepublication.com
	DOI: 10.5958/2394-2126.2016.00013.X

Introduction

A museum by definition is “An institution that houses and cares for a collection of artefacts and other objects of scientific, artistic or historical importance and makes them available for public viewing through exhibits that may be permanent or temporary”¹. The anatomy museums belong to the category of science museums as they display various anatomical structures of scientific interest to medical students and public. It is essential to know the history of anatomy, a science with a prestigious history, a foundation stone upon which the medical knowledge has evolved over the past several decades. The development of anatomy as a science began as early as 1600BC, in Egypt. The treatise on heart “Ebers Papyrus” (1500BC) notes heart as the centre of blood supply². The origin of the concept of anatomy museums can be traced back to the year 1699 to 1763 when Surgeons of Edinburgh determined to create a collection of anatomical specimens, pictures and books. It was called the “collection of curiosities”³.

The Museum of Human Anatomy of the University of Bologna is believed to be one of the most ancient museums⁴. The early museums predominantly comprised of paintings and models. This was because

the preservative formalin was not discovered until 1859. In 1859 Alexander Mikhailovich Butlerov discovered formaldehyde, which was then isolated in 1868 by August Wilhelm Von Hoffmann⁵. The La Specola Collection in Florence is renowned for its huge collection of anatomical wax models⁶. Hunterian museum is the most famous eighteenth century museum established initially by John Hunter from 1783 to 1793 was later purchased by the government in 1799⁷. The Museum of the Royal College of Surgeons of Edinburgh is renowned for its collection of pathological anatomy in the United Kingdom⁸. The Turin’s Anatomy Museum of University of Turin, Italy⁹, Anatomy Museum of Queen’s University of Belfast¹⁰, Oxford University Museum¹¹ and the Pedro Ara Anatomy Museum are some of the renowned international anatomy museums of the nineteenth and twentieth century¹².

The Anatomy Museum of Leiden Medical University in Netherlands and the Museum of Kawasaki Medical School, in Japan are some examples of modern twenty first century museums that use electronic screens and audio-visual aids to teach anatomy to medical students¹³. It is evident from the history that anatomy museums have undergone a series of transitions, from an institute housing artistic sketches and models in the seventeenth and eighteenth century to those displaying dissected formalin preserved specimens in the nineteenth century to the modern day museums which use computer software and audio-visual aids and display plastinated specimens¹⁴. This study on anatomy museums across south India aims to

Fig. 5: shows plastination section.

Courtesy Kasturba Medical College, Mangalore.

Fig. 6: Shows section with embryology models.

Courtesy Yenepoya Medical College, Mangalore.

Discussion

The anatomy museums in medical colleges across south India are well established and play a significant role in medical education. All the museums had a vast collection of anatomical specimens which was adequate for teaching the undergraduate students. Moreover the specimens were well maintained and displayed. The specimen preparation techniques were studied in all the museums and summarised.

Specimen Preparation

The first step in preparation was specimen selection and a fresh well preserved body was preferred. However, best results are always obtained

with fresh post-mortem specimens and when specimens are obtained directly from the operation theatre. While preparing a specimen of a section of body sectioning the body was done using a long, sharp butcher's knife so that the cut surface is smooth, straight and continuous. The specimen obtained was immediately transferred to a primary fixative like 10% formalin. Dissection of the formalin fixed specimen was done gently with great patience. In some places dissection was done keeping the specimen in water as water prevents adhesion of structures, loosens the connective tissue and makes the process easier. Skin and fat was removed very gently. Once the process of dissection was complete the specimen was cleaned with water very gently without damaging the minute nerves and vessels. The specimens were allowed to dry for one complete day and a tissue paper was used very gently to dry the specimens. The dried specimen was tied with a nylon thread to acrylic sheet. Amyl acetate and quick fix were mixed properly with a number '3' brush and the mixture was applied to the specimen. Oil colours were used to paint the arteries red, veins blue and the nerves yellow. After painting the specimens were allowed to dry. Once dry, the specimens were preserved in a jar containing 10% formalin.

Bone Preparation

Two methods of bone preparation were observed during the study. The first method was the putrefaction method. This method was time consuming and created a nauseating smell. The advantage was that all the features of the bones were preserved in this technique. In this method the bones were procured from cadavers, which were put in maceration tanks with water for a period of six months. After six months the bones were separated, washed well using brush and water and put in 5% hydrogen peroxide. Bones were again washed using brush and water. They were then dried under the sun for two days.

The alternative method of preparing bone specimens was quick but the minute features of the bones were lost. The process involved the following steps. The bone with the soft tissues was boiled in tap water or N/10 sodium hydroxide. The body was taken out at intervals to remove the soft tissues. The body was then autoclaved in N/10 sodium hydroxide for 5 minutes. Since the process involved boiling and autoclaving, the fine features of bones like the fine spicules of an osteosarcoma etc were lost. Several museums also used alizarin stained specimens to demonstrate the foetal skeleton.

Specimen Preservation, Mounting, Labelling and Jars

All the museums used 10-15% formalin as a preservative. Only one museum had preserved a few specimens in Kaiserling's solution. The Kaiserling's technique of fixation and preservation of specimens

(1897) has been modified by Pulvertaft and is now known widely as Pulvertaft-Kaiserling's technique and is believed to be the best technique for preservation¹⁵. It was observed that specimens preserved by Pulvertaft-Kaiserling's technique do not show any significant colour fading even after thirty years.

The specimens were usually mounted to a centre plate made of acrylic. The specimen was stitched to the centre plate using linen thread and glass beads. Points for stitches were marked on the centre plate & holes of 1/16 inch diameter were drilled using a drill.

In some cases labelling was done inside the jar. A coat of amyl acetate and quick fix was applied to the labels. Labelling was also done using acrylic sheets 1/16 inch in thickness. The labelling was written on these sheets. The sheets were then cemented to the bottom of the centre plate or to the bottom of outer aspect of the jar.

While observing the types of jars used for preservation in various museums a changing trend towards the use of acrylic jars was noted as jars of any size could be easily prepared and they were much cheaper. Although perspex jars are clearer, light weight, tough, durable and have excellent optical properties there were no perspex jars in any of the museums as they are very expensive. Preservation of specimens in Kaiserling's solution and in perspex jars will certainly enhance the display.

Sectional Arrangement

The specimens were arranged in diverse sections such as comparative anatomy section, evolutionary anatomy section, section on history of anatomy, mummies, plastinated specimens, embryology section, cross-sectional anatomy section, osteology section, section on odontology, teratology and some museums also had a section on clinical anatomy.

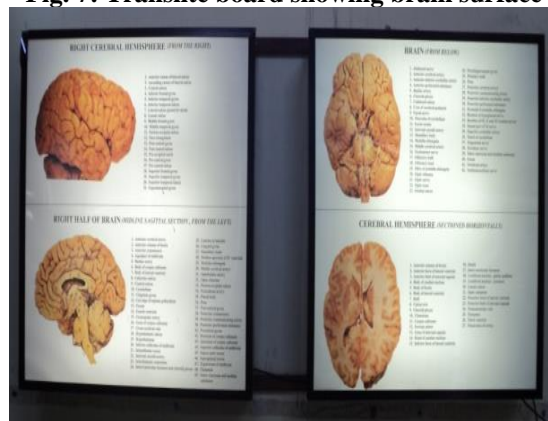
Catalogues & Informative Boards

Informative catalogues containing photographs of specimens and their description were present in thirteen out of the sixteen museums. In several museums informative boards containing artistic sketches of various parts of the body along with descriptive information were used. Translite boards were used in some museums as shown in figure 7.

Museum Care and Display


Museum cleanliness, regular checking of jars and preservatives, replacement of damaged labels and specimens are equally essential for long term preservation of specimens. A well maintained museum is shown in figure 8.

Fig. 7: Translite board showing brain surface



Courtesy St. John's Medical College, Bangalore.

Fig. 8: A well maintained museum



Courtesy KSHEMA Anatomy museum, Mangalore.

Concept of Digitalisation

However none of the museums were digitalised. Digitalization of a museum, involves development of anatomy related computer software and audio-visual aids, preferably both in English and in the regional languages, so that both the medical students and the public are benefited. Marreez et al. have described two modern day museums, which include the Anatomy Museum of Leiden Medical University in Netherlands and the Museum of Kawasaki Medical School, in Japan. The museums have applied the advances in information technologies and audio-visual aids for educational purpose.

The museum also displays related pathology specimens with electronic screens that display educational information regarding each specimen¹³. As part of the Leiden Medical School curriculum, medical students are required to visit the medical museum several times during their undergraduate training. Audio recordings have been prepared by faculty from the different medical specialties at Leiden, and students have the option of downloading these into MP3 players, including iPods to guide them through their museum

visits. Narrations, in the familiar voices of their regular faculty, commenting on each specimen are also present¹³. Shimizu and Tanaka have demonstrated a new innovative technique of teaching neuroanatomy. The major vessels were irrigated with coloured silicone and the neuroanatomical specimens were prepared by careful dissection. Three dimensional (3-D) stereoscopic pictures of the specimens were then obtained which were viewed using a 3-D viewer. The technique can also be applied to museums¹⁶.

Conclusion

The anatomy museums of southern India are well established and play a major role in contemporary medical education. However there is a lot of scope for improvisation especially in the form of digitalisation of the museum as described. The anatomists must now focus more on digitalising the museum by incorporating anatomical software and audiovisual aids thus converting the museum into a school of learning. Moreover, a well equipped academic museum must have arrangement for medical students to sit and study, with tables, chairs, blackboards and computer, while observing the specimens.

Conflict of Interest

The authors do not have any conflict of interest to disclose.

Source of Support: Nil

References:

- Alexander EP, Alexander M. Museums in motion: An introduction to the history and functions of museums, Second Edition, Rowman & Littlefield, North America, 2008.
- Porter R. The Greatest benefit to mankind: A Medical history of humanity from antiquity to the present, First Edition, W. W. Norton, New York, 1997: 47-50.
- Kemp D & Barner S. Surgeons' Hall: A Museum Anthology, Royal College of Surgeons, Edinburgh, 2009.
- Maraldi NM, Mazzotti G, Cocco L, Manzoli FA. Anatomical wax work modelling: The history of the Bologna Anatomy Museum, *Anat Rec*, 2000, 261:5-10.
- Walker JF. Formaldehyde, 1st Edition. Reinhold Publishing Corporation, New York, 1944: 2-3.
- Lotti S, Altobelli A, Bambi S, Poggese M. Illustrations of the anatomical wax model collection in the La Specola Zoology Museum, Florence, *Arch Nat Hist*, 2006, 33: 232-240.
- Chaplin S. John Hunter and the anatomy of a museum, *Hist Today*, 2005, 55: 19-25.
- Tansey V, Mekie DEC. The museum of the Royal College of Surgeons of Edinburgh, Royal College of Surgeons of Edinburgh, 1982.
- Abbott A. Hidden treasures: Turin's anatomy museum, *Nature*, 2008, 455:736.
- Heylings DJA. The Anatomy Museum at the Queen's University of Belfast, *Ulster Med J*, 1990, 59:194-199.
- Kemp MN, Galenakis Y. Ancient Greek skulls in the Oxford University Museum. Part 1, *J Hist collections*, 2012, 24:89-104.
- Montenegro VA, Trefilio DE, Borghino VN, Páez RE, Aranega CI. Pedro Ara anatomic museum, *Neurol Res*, 2006, 28: 115-125.
- Marreez YM, Willems LN, Wells MR. The Role of medical museums in contemporary medical education, *Anat Sci Educ*, 2010, 3: 249-253.
- Kamath VG, Ray B, Pai SR, Avadhani R. The origin of anatomy museums, *Eur. J. Anat*, 2014, 18: 63-67.
- Kaiserling. Kaiserling's method for the preservation of Specimens with their natural colours, *J Boston Soc Med*, 1897, 1: 14.
- Shimizu S, Tanaka R. Anatomic Dissection and classic three dimensional documentation: A unit of Education for neurosurgical anatomy revisited, *Neurosurgery*, 2006, 58(5): E-1000.