



## Case Report

# An unusual variation in the termination of facial artery in south Indian population: A human cadaveric case report

Aniketh Prabhu<sup>1</sup>, David Varghese Samuel<sup>1</sup>, Vimal Balakrishnan<sup>2</sup>, Priyanka Daniel<sup>3,\*</sup>

<sup>1</sup>Christian Medical College, Vellore, Tamil Nadu, India

<sup>2</sup>Dept. of Medicine, Christian Medical College, Vellore, Tamil Nadu, India

<sup>3</sup>Dept. of Anatomy, Christian Medical College, Vellore, Tamil Nadu, India



## ARTICLE INFO

### Article history:

Received 26-04-2021

Accepted 12-05-2021

Available online 06-07-2021

### Keywords:

Facial artery variation

Pre-masseteric artery

Superior labial artery

Facial surgeries

Facial flaps

## ABSTRACT

The facial artery is an important artery of the face, prone to many variations. Identification of these variations is of utmost importance in clinical practice, especially rhinoplastic and orofacial surgeries and also super selective chemotherapy procedures. In this case report, we report a bilateral facial artery variation encountered in a male cadaver during routine dissection. Instead of terminating as the angular artery, the facial artery terminated as the superior labial artery, giving the lateral nasal artery as a smaller branch, much closer to the midline than normal. A prominent pre-masseteric branch was noticed along with smaller branches from the infraorbital artery which offered possible compensation for the short facial artery. The case reported is a type II variation according to Bayram classification, and a type C variation as per Loukas classification. This variation is very rare and should be kept in mind while performing any surgical procedures of the face.

© This is an open access article distributed under the terms of the Creative Commons Attribution License (<https://creativecommons.org/licenses/by/4.0/>) which permits unrestricted use, distribution, and reproduction in any medium, provided the original author and source are credited.

## 1. Introduction

The facial, transverse facial, and infraorbital arteries provide for the main arterial supply of the face, the facial artery being the most dominant amongst them. Facial artery arises from the external carotid artery, runs upwards to reach the inferior border of the mandible, follows a tortuous course up to the angle of the mouth, giving the inferior labial and superior labial arteries and further continuing to the medial canthus of the eye, terminating as the lateral nasal artery.<sup>1</sup> A pre-masseteric artery given off before the inferior labial artery, running along the superior border of the masseter and supplies the surrounding tissues has been described by Adachi et al.<sup>2</sup>

There are variations in the pattern of termination of facial artery which are important clinically. These variations are important clinically as facial surgeries require the mobilization of the branches of the facial artery and

also, the masseter muscle if exploited by craniofacial surgeons without the knowledge of the occurrence of its pre-masseteric branch can lead to its damage.<sup>3</sup> Here we report a case of bilateral facial artery variation which was encountered during the routine anatomy dissections for undergraduate learning.

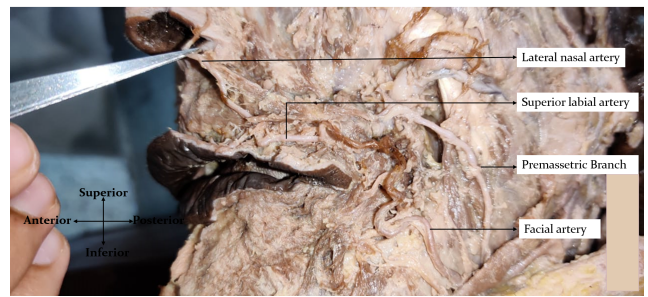
## 2. Case Report

Here we report a case of bilateral facial artery variation, encountered during routine anatomy dissection of a formalin-fixed male cadaver, for undergraduate learning. We found an unusual variation in the termination of the facial artery. The facial artery arose from the external carotid artery, followed a tortuous path, moving beneath the digastric and stylohyoid muscles, after which it passed through the submandibular gland. It then curved over the body of the mandible and ascended forwards and upwards to the angle of the mouth. Then, instead of running from the angle of the mouth towards the side of the nose, the

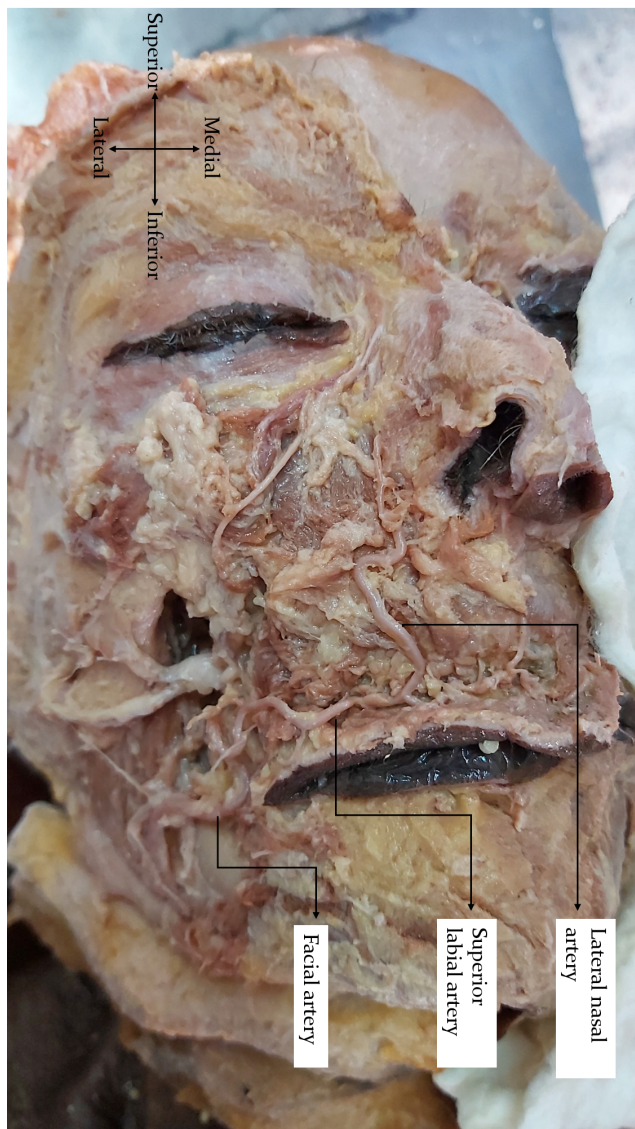\* Corresponding author.

E-mail address: [priyanka.daniel@gmail.com](mailto:priyanka.daniel@gmail.com) (P. Daniel).

facial artery took a sharp turn at the angle of lip, continuing as the superior labial artery which anastomosed with the opposite side superior labial artery in the midline above the margin of the upper lip. The lateral nasal artery was given off closer to the midline than usual, as a branch from the superior labial artery, did not give rise to the angular artery and terminated by supplying the lateral part of the nose as inferior alar artery. There was also a single pre-masseteric branch noted on the left side, given off before inferior labial artery. On the right side the pre-masseteric branch could not be preserved during dissection. Few smaller branches from the infraorbital artery were also noted bilaterally supplying the upper part of the side of the nose. (Figures 1 and 2)



**Fig. 2:** Facial artery and its terminal branches on the left side with a pre-masseteric branch. **A:** Facial artery; **B:** Pre-masseteric branch, **C:** Superior Labial artery, **D:** Lateral Nasal artery)



**Fig. 1:** Facial artery and its terminal branches on the right side. (A- Facial artery, B- Superior Labial artery, C- Lateral Nasal artery).

### 3. Discussion

Facial artery, an important artery of the face, is known to have variations in its course and branches. Identification of such variations is essential in clinical practice, especially during surgeries such as orofacial, maxillary, rhinoplastic and cosmetic surgeries. Surgically, facial artery is used as a pedicle in a number of flaps such as nasolabial skin flaps, oral mucosal flaps, buccal mucosal flaps, and facial artery musculomucosal flaps.<sup>1</sup> Also, cancers of the head and neck sometimes require super-selective intra-arterial chemotherapy where facial artery is used for the procedure<sup>4</sup>

Lohn et al reported six types of termination of facial artery. Facial artery terminated as angular artery (25%), lateral nasal artery (49%), alar artery (17%), superior labial artery (4%), inferior labial artery (2%), and was undetectable in 2%. (1) Loukas M et al. classified the facial artery into 5 types. Type A (47.5%) where the facial artery bifurcated into superior labial and lateral nasal arteries, the latter giving off inferior and superior alar and ending as angular artery. Type B (38.7%) was where it had similar course as Type A but didn't end as the angular artery, type C (8.4%) where it terminated as the superior labial artery, type D (3.8%) where it ended as the superior alar artery and not as the lateral nasal artery as the angular artery arose directly from the main trunk of the facial artery and type E (1.4%) was when the facial artery ended as a rudimentary twig with no significance.<sup>5</sup> Bayram et al. (2010) classified the variations of facial artery into 3 types, type I (76%) where the facial artery terminated as angular artery, type II (12%) where it terminated as superior labial artery, and type III (12%) where it terminated as inferior labial artery.<sup>6</sup> Our present report is a Type C Loukas variation or a Type II Bayram variation, where the facial artery terminated as the superior labial artery. The lateral nasal branch, given off from the superior labial artery, was much closer to the midline than usual, which is a relatively rare mode of termination.

In a cadaveric study done in a south Indian population, facial arteries classified using the Bayram classification

were found to be type I (100% right, 78% left) and type III (22% left) in males and type I (80% bilaterally), type II (18% left), and Type III (20% right and 2% left) in females. A pre-masseteric branch was noted in 4 out of 50 hemi-faces studied.<sup>7</sup> On comparison with this study, our study being from a similar population, notes the presence of a type II variation in a male cadaver with a pre-masseteric branch on the left side, which was reported as being not present in the above mentioned study population.

We have noted that a pre-masseteric branch along with smaller branches from the infraorbital artery were probably the route of compensation for the unusually small facial artery. Usually, the face is supplied by facial, transverse facial and infraorbital arteries. It has been reported in literature that when the facial artery is hypoplastic, it is compensated by the transverse facial artery.<sup>8</sup> In our case report, the compensation of a shorter facial artery is obtained by a pre-masseteric branch which is also reported in literature to be of significant value.<sup>2</sup>

Therefore, it is important that clinicians be aware of the possibility of variations of the facial artery while performing various procedures of head and neck to avert avoidable damage.

#### 4. Source of Funding

None.

#### 5. Conflict of Interest

The authors declare that there is no conflict of interest.

#### References


1. Lohn JWG, Penn JW, Norton J, Butler PEM. The course and variation of the facial artery and vein: implications for facial transplantation and facial surgery. *Ann Plast Surg.* 2011;67(2):184–8.
2. Mozafar M, Zarrintan S, Tubbs RS. Simultaneous resection of abdominal aortic aneurysm and left renal cell carcinoma: A rare case and review of the literature. *J Cardiovasc Thoracic Res.* 2020;12:152–5. doi:10.34172/jcvtr.2020.26.
3. Lee HJ, Won SY, Jehoon O, Hu K, Mun SY, Yang HM. The facial artery. *Clin Anat.* 2018;31(1):99–108.
4. Shimizu T, Sakakura Y, Hattori T, Yamaguchi N, Kubo M, Sakakura K. Superselective intraarterial chemotherapy in combination with irradiation: Preliminary report. *Am J Otolaryngol.* 1990;11(2):131–6. doi:10.1016/0196-0709(90)90009-k.
5. Loukas M, Hullett J, Louis RG, Kapos T, Knight J, Nagy R, et al. A detailed observation of variations of the facial artery, with emphasis on the superior labial artery. *Surg Radiol Anat.* 2006;28(3):316–24. doi:10.1007/s00276-006-0093-0.
6. Bayram S, Kalaycioglu A. Branching patterns of facial artery in fetuses. *N J Med.* 2010;27:227–30.
7. Quadros LS, Babu A, D'souza AS. Facial artery on face - A study on south Indian cadavers and specimens. *J Health Allied Sci NU.* 2013;03(03):072–6. doi:10.1055/s-0040-1703682.
8. Tubbs RS, Salter EG, Oakes WJ. Unilateral agenesis of the facial artery with compensation by a giant transverse facial artery. *Folia Morphol.* 2005;64(3):226–8.

#### Author biography

**Aniketh Prabhu**, MBBS Student

**David Varghese Samuel**, MBBS Student

**Vimal Balakrishnan**, Non-PG Registrar

**Priyanka Daniel**, Associate Professor  <https://orcid.org/0000-0003-2106-4452>

**Cite this article:** Prabhu A, Samuel DV, Balakrishnan V, Daniel P. An unusual variation in the termination of facial artery in south Indian population: A human cadaveric case report. *Indian J Clin Anat Physiol* 2021;8(2):156-158.