



## Case Report

# Situs inversus totalis: Anatomic study and radioanatomic aspects about one case

Philippe Manyacka Ma Nyemb<sup>1,2,\*</sup>, Régine Emma Nsia<sup>3</sup>, Aïnina Ndiaye<sup>4</sup>,  
Magaye Gaye<sup>4</sup>, Abdoulaye Ndiaye<sup>4</sup>

<sup>1</sup>Dept. of Anatomy and Organogenesis, Faculty of Medicine, Gaston Berger University, Saint-Louis, Senegal

<sup>2</sup>Dept. of General Surgery, Regional Hospital, Saint-Louis, Senegal

<sup>3</sup>Dept. of Radiology, Regional Hospital of Louga, Senegal

<sup>4</sup>Dept. of Anatomy and Organogenesis, Faculty of Medicine, Cheikh Anta Diop University, Dakar, Senegal



## ARTICLE INFO

### Article history:

Received 24-11-2020

Accepted 29-11-2020

Available online 11-01-2021

### Keywords:

Situs inversus totalis

Developmental anomaly

Organ transposition

Fortuitous discovery

## ABSTRACT

The term "Situs inversus" is a diminutive for "Situs inversus viscerum" which means in Latin: inverted position of the internal organs. It was first described in 1643 and has an incidence of approximately 1 / 10,000 births. A mirror image of the original anatomical configuration represents the situs inversus totalis. Several authors described anomalies in the rotation and fixation of viscera during their development. These developmental anomalies are not necessarily the cause of functional problems. The clinical and surgical implications can be significant, as several authors reported a situs inversus totalis over the most conventional surgical procedures. The technical difficulties represent the main challenge. Because even though many patients are known to have situs inversus totalis, surgeons need an adaptation time to get used to the mirror image of viscera. Iatrogenic injuries and an increase in operative time are not uncommon.

We report a case of situs inversus totalis in a 68-years-old patient, accidentally discovered during investigations for an adenocarcinoma of the prostate. We remind in detail the anatomical presentation and morphological aspects found in our patient. Several hypotheses have been mentioned to explain the pathogenesis of situs inversus. Even if the anatomical inversion of many organs has been genetically studied, it appears a predominance for the viscera whose positional abnormalities are the most obvious (heart, liver, stomach). For other naturally "symmetrical" organs the inverted position is much less obvious, if not controversial, as is the case with the brain.

The term "situs inversus totalis" is used to describe the transposition of all organs of the body to the opposite side, its incidence is relatively low. Situs inversus totalis is a rare pathological condition, but with important clinical and surgical implications. Even if its discovery is most often fortuitous, hospital practitioners (especially surgeons and radiologists) must take this possibility into account, especially for patients awaiting surgery.

© This is an open access article distributed under the terms of the Creative Commons Attribution License (<https://creativecommons.org/licenses/by/4.0/>) which permits unrestricted use, distribution, and reproduction in any medium, provided the original author and source are credited.

## 1. Introduction

Situs inversus totalis represents a condition in which the thoraco-abdominal organs are arranged in a mirror image, perfectly inverted from the normal position. Situs inversus totalis affects about one over 10,000 people.<sup>1,2</sup> This anomaly is sometimes diagnosed late during adult

life. It may be associated with malformations such as ciliary dyskinesia, cardiac and splenic anomalies.<sup>3,4</sup> The clinical and surgical implications can be significant, as several authors report a situs inversus totalis over the most conventional surgical procedures. The technical difficulties represent the main challenge. Because even though many patients are known to have situs inversus totalis, the surgeon needs some adaptation time to get used to the mirror image of the viscera. Iatrogenic injuries and an increase in

\* Corresponding author.

E-mail address: [phil\\_manyacka@yahoo.fr](mailto:phil_manyacka@yahoo.fr) (P.

Manyacka Ma Nyemb).

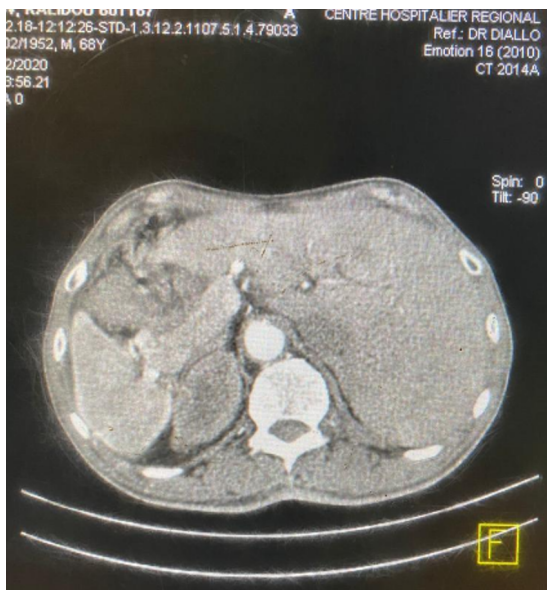
operative time are not uncommon.

We report a case of situs inversus totalis in a 62-years-old patient, discovered during investigations for an adenocarcinoma of the prostate. We remind in detail the anatomical presentation and the morphological aspects found in our patient.

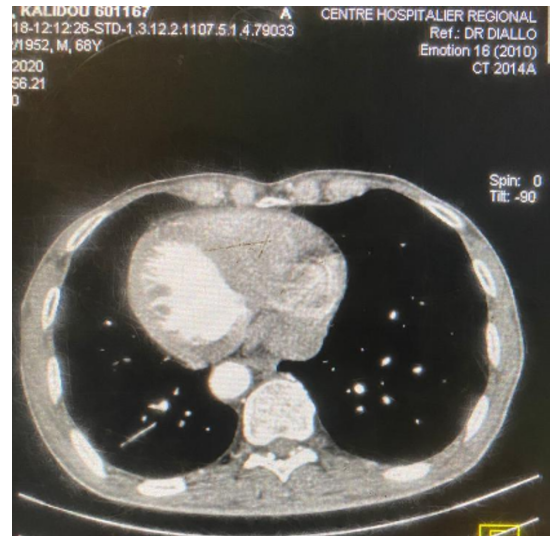
## 2. Clinical Case

We report the case of a 68-years-old patient, with no particular pathological history, who consulted for several symptoms of the lower urinary tract including obstructive disorders (dysuria) and irritative disorders (pollakiuria at a rate of 3 to 5 nocturnal awakenings). The physical examination revealed good general condition and the absence of a distended bladder. The rectal examination reported an enlarged prostate at the expense of the 2 lobes, hard and nodular, classified CT2C.

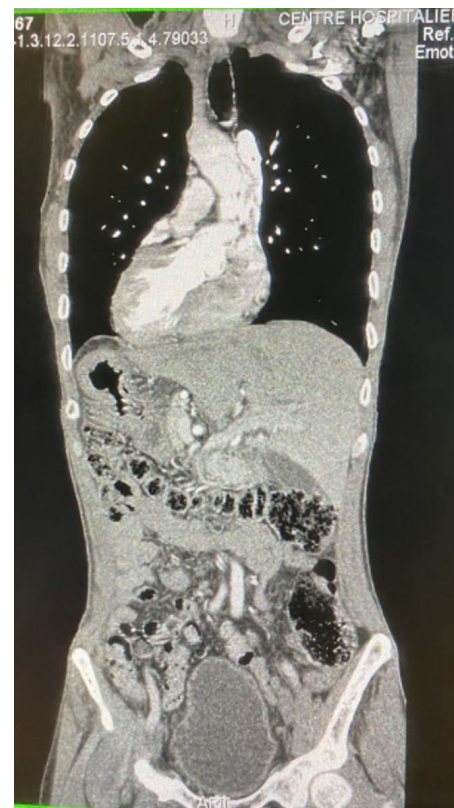
Paraclinical investigations reported a creatinine level of 19 mg / dl, a PSA level of 37.20 ng / ml, however the urinalysis showed no infection. Thoraco-abdominal-pelvic CT found a situs inversus totalis (Figures 1, 2, 3 and 4); a prostatic hypertrophy without focal mass visualized with ureterohydronephrosis; a muscular and diverticular bladder, with an infiltration of the periprostatic fat (interest of a prostate MRI), and bilateral pulmonary nodules suspected to be secondary localizations. Anatomopathological and cytopathological examinations of the prostate biopsy samples revealed a Gleason 5 (3 + 2) prostatic adenocarcinoma.



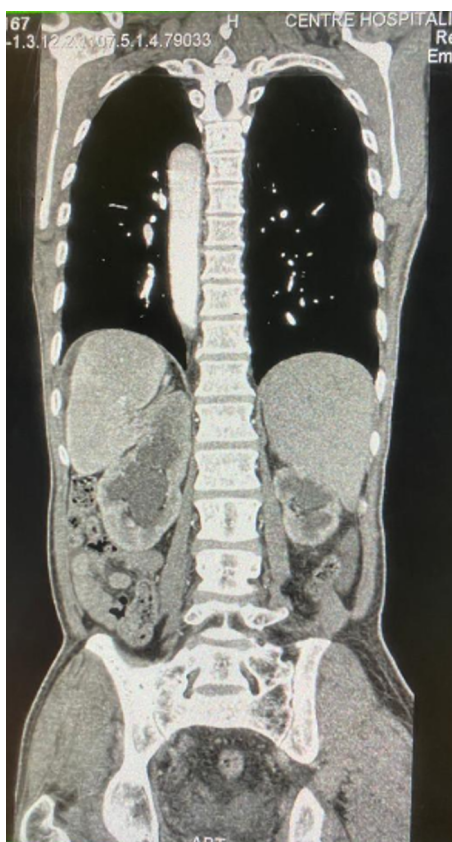**Fig. 1:** TDM\_A. Abdominal CT scan with arterial injection. Axial reconstruction showing the liver, stomach, spleen and left kidney in reversed positions from normal



**Fig. 2:** TDM\_B. Thoracic CT with arterial injection. Axial reconstruction showing the tip of the heart on the right side. The left ventricle is directed towards the lower right side of the thorax. The right atrium receiving the venae cavae (projecting to the left of the spine) assumed a more medial position than usual



**Fig. 3:** TDM\_C. Thoraco-abdominal-pelvic CT scan with arterial injection. Coronal reconstruction showing the heart's tip on the right, the cecum in the left iliac fossa and a dextrogastria



**Fig. 4:** TDM\_D. Thoraco-abdominal-pelvic CT scan injected in the arterial phase. Coronal reconstruction showing a deported spleen on the right. The right kidney higher located than the left one with bilateral calyceal dilatation

### 3. Discussion

The term "Situs inversus" is a diminutive for "Situs inversus viscerum" which means in Latin: inverted position of the internal organs. It was first described in 1643 by Marco Severino.<sup>5</sup> The incidence of situs inversus is approximately 1 / 10,000 births. Normal development of the trunk results from an asymmetric organization of organs in abdominal and thoracic cavities. In the typical description, the heart is essentially arranged on the left (levocardia), as is the spleen. A mirror image of this original configuration represents the situs inversus totalis. Several authors described anomalies in the rotation and fixation of viscera during their development.<sup>6-10</sup> These developmental anomalies are not necessarily the cause of functional problems. Situs inversus is an anomaly that has been described several times in the literature. However, detailed descriptions of the vessels and internal structures of the thoracoabdominal viscera are scarce. Among the authors who worked on this anatomical curiosity, we can cite Tanaka,<sup>6</sup> Iwamoto,<sup>7</sup> Tohno<sup>8</sup> and Taniya.<sup>9</sup> These researchers described abnormalities such as the presence of a single azygos trunk without a hemi-azygos vein, a long and thick transverse or inferior pancreatic artery,

a well-developed accessory middle colonic artery, or an hepatic artery arising from the superior mesenteric artery. Situs inversus totalis represents a condition in which the thoraco-abdominal organs are arranged in a mirror image, perfectly inverted from the normal position. Although the situs inversus totalis affects about one in 10,000 people, this abnormality is sometimes diagnosed late in adulthood. It may be associated with malformations such as ciliary dyskinesia, cardiac and splenic anomalies.<sup>3,4</sup>

The clinical and surgical implications can be significant, as several authors report a situs inversus totalis over the most conventional surgical procedures. The technical difficulties represent the main challenge. Because even though many patients are known to have situs inversus totalis, the surgeon needs some adaptation time to get used to the mirror image of viscera. Iatrogenic injuries and an increase in operative time are not uncommon. Several hypotheses have been mentioned to explain the pathogenesis of situs inversus. Layton,<sup>11</sup> Seo<sup>12</sup> and Hecksher-Sorensen<sup>13</sup> proposed the existence of genes responsible for the laterality (or not) of organs. Even if the anatomical inversion of many organs has been genetically studied, it appears a predominance for the viscera whose positional abnormalities are the most obvious (heart, liver, stomach). For other naturally "symmetrical" organs the inverted position is much less obvious, if not controversial, as is the case with the brain.

The human brain is anatomically and functionally asymmetric. But we still do not know the mechanisms that lead to this functional and anatomical asymmetry. Most people are right-handed and their command of speech is in the left hemisphere. Authors reported several hypothesis regarding the origin of brain asymmetry.<sup>14-16</sup> In particular, a relationship appears between the existence of a situs inversus and the dominance of the left hemisphere of the brain. If topographic inversion were limited to internal organs, there would be no point in studying cerebral asymmetry in patients with situs inversus totalis. Wehrmaker<sup>17</sup> and Tanaka<sup>6</sup> suggest the possibility of an inversion in the laterality of the cerebral hemispheres, the same as other internal organs in the situs inversus totalis. One of the most well-known functional asymmetry in the human brain is the dominance of one limb over the other. However, this asymmetry does not appear to be involved in situs inversus according to Torgersen.<sup>18</sup> Since the proportion of right-handed and left-handed people in the normal population is the same as in subjects with situs inversus, the functional asymmetry of the brain in individuals with situs inversus is probably the same as that observed in normal subjects.

In the case we present, the tip of the heart was found in dextrocardia. The "right ventricle" was offset to the left and connected to the pulmonary arterial trunk. The "left ventricle" was directed towards the lower right side of the thorax. The base of the heart was facing up and to the left.

**Table 1:** Anatomical abnormalities associated with situs inversus

Region	Name of the Organ	Observations
Thorax	Heart	Apex-on Rights Side Chambers- positioned reversely
	Superior venacava (SVC)	Formation is normal but seen on the left side.
	Inferior vena cava (IVC)	Formation is normal but directed seen on the left side.
	Ductus Arteriosus	Connects right branch of the pulmonary truck to arch aorta.
	Lungs	One rights side two lobes with normal hilar structures, lingula and cardiac notch
		One left side three lobes with normal hilar structures,
Diaphragm	Crus, Central tendon Domes, Oesophagus	No herniation, Structures, passing through diaphragm are on normal basis
Abdomen	Stomach	Oesophageal hiatus in diaphragm is towards right side
	Spleen	Infantile, with normal gross features
	Liver	Present at right hypochondria
		Large left lobe with gallbladder fassa on its inferior surface, microscopic structure has no cysts presents
	Small Intestine	Loops of intestines Placed at the centre without getting fixed Duodenum oriented on left side
		Positioned centrally without mesocolon
	Vermifrom appendix	Caecum is not sacculated, no ascending colon, transverse colon and rectum placed at the centre of the cavity.
	Large intestine	Enormously grown occupying most of the abdomen
Pelvis	Kidneys	According to the shapes they are present reversely
	Supra Renals	Normal, well developed external and internal genital organs
	Genital organs	

The heart was located largely on the right side of the thorax. However, the right atrium receiving venae cavae (projecting to the left of the spine) assumed a more medial position than usual. It was ventrally attached to the diaphragm muscle. The aortic arch and its 3 main collateral branches, the lungs with their lobar bronchi (2 on the right and 3 on the left), the liver and the gallbladder, the stomach, the colon, the duodeno-pancreas and the spleen were in reversed positions from normal. The pulmonary artery trunk crossed the ventral part of the ascending aorta. The aortic arch crossed the ventral surface of the pulmonary artery, itself on the left side. The descending aorta occupied the right side of the lumbar spine. The inferior vena cava was located on the left side of the lumbar spine, in front of the abdominal aorta. We also found a large left hepatic lobe and a smaller one on the right. The cecum followed on from the jejunum-ileum and descended into the left iliac fossa. Opposite the underside of the liver, the portal vein was located on the left, as were hepatic arteries and extrahepatic bile ducts. The external configuration of the gallbladder was also reversed. The celiac, superior mesenteric and inferior mesenteric arteries originate from the aorta at their usual level. The spleen was deported to the right. The kidney on the left was lower than the one on the right, so the renal artery to the left kidney was lower than the opposite one. Abdur-Rahman et al<sup>19</sup> reported dextrogastric, reverse rotation of the midgut and intestinal atresia. Sharma<sup>5</sup> reported a multitude of anomalies associated with situs inversus totalis (Table 1).

The occurrence of situs inversus is essentially due to embryological factors.<sup>20,21</sup> In the trunk, organ development requires a 270° counterclockwise rotation in order to obtain the normal anatomy of visceral structures. In a situs inversus, the rotation of 270° occurs in a clockwise direction.<sup>22</sup> Depending on the degree of malrotation, situs inversus can be total, including the thoracic and abdominal organs (situs inversus totalis), or more rarely partial (situs inversus partialis).<sup>23</sup> Situs inversus may be associated with other birth defects such as renal dysplasia, biliary atresia, congenital heart disease or pancreatic fibrosis.<sup>23</sup>

#### 4. Conclusion

The term "situs inversus totalis" is used to describe the transposition of all organs of the body to the opposite side, its incidence is relatively low. Situs inversus totalis is a rare pathological condition, but with important clinical and surgical implications. Even if its discovery is most often fortuitous, hospital practitioners (especially surgeons and radiologists) must take this possibility into account, especially for patients awaiting surgery.

#### 5. Source of Funding

None

#### 6. Conflict of Interest

The authors declare no conflict of interest through this work.



## References

1. Janchar T, Milzman D, Clement M. Situs inversus: Emergency evaluations of atypical presentations. *Am J Emerg Med.* 2000;18(3):349–50. doi:10.1016/s0735-6757(00)90142-6.
2. McKay D, Blake G. Laparoscopic cholecystectomy in situs inversus totalis: a case report. *BMC Surg.* 2005;5(1):5. doi:10.1186/1471-2482-5-5.
3. Shapiro AJ, Davis SD, Ferkol T. Laterality defects other than situs inversus totalis in primary ciliary dyskinesia: insights into situs ambiguus and heterotaxy. *Chest.* 2014;146(5):1176–86.
4. Hynes KM, Gau GT, Titus JL. Coronary heart disease in situs inversus totalis. *Am J Cardiol.* 1973;31(5):666–9. doi:10.1016/0002-9149(73)90341-x.
5. Sharma S, Chaitanya KK, Suseelamma D. Situs inversus totalis (dextroversion)-an anatomical study. *Anat Physiol.* 2012;2(5):112.
6. Tanaka S, Kanzaki R, Yoshiyoshi M. Dichotic listening in patients with situs inversus: brain asymmetry and situs asymmetry. *Neuropsychol.* 1999;37:869–74.
7. Iwamoto S. Complete situs inversus with multiple anomalies 1. Variations in abdominal arteries. *J Kinki Univ School Med.* 1976;1:149–63.
8. Tohno Y. Complete situs inversus found in 95 female donated cadavers. *Acta Anat Nippon.* 1983;58:606–13.
9. Taniya S. Complete situs inversus with multiple anomalies. *Acta Anat Nippon.* 1984;59:94–103.
10. Mano Y, Adachi N, Murakami G, Yokoyama T, Dodo Y. Human situs inversus of the thoracoabdominal structures. *Anat Sci Int.* 2006;81(1):7–20. doi:10.1111/j.1447-073x.2006.00122.x.
11. Layton WM. Heart malformations in mice homozygous for a gene causing situs inversus. *Birth Defects.* 1978;14:277–93.
12. Seo JW, Brown NA, Ho SY, Anderson RH. Abnormal laterality and congenital cardiac anomalies. Relations of visceral and cardiac morphologies in the iv/iv mouse. *Circ.* 1992;86(2):642–50. doi:10.1161/01.cir.86.2.642.
13. Hecksher-Sorensen J. The splanchnic mesodermal plate directs spleen and pancreatic laterality, and is regulated by Bapx1/Nkx3.2. *Dev.* 2004;131:4665–75. doi:10.1242/dev.01364.
14. Corballis MC, Morgan MJ. On the biological basis of human laterality: I. Evidence for a maturational left–right gradient. *Behav Brain Sci.* 1978;1(2):261–9. doi:10.1017/s0140525x00074471.
15. McManus IC, Bryden MP. Geschwind's theory of cerebral lateralization: Developing a formal, causal model. *Psychol Bull.* 1991;110(2):237–53. doi:10.1037/0033-2909.110.2.237.
16. Layton WM. Random determination of a developmental process: Reversal of normal visceral asymmetry in the mouse. *J Heredity.* 1976;67(6):336–8. doi:10.1093/oxfordjournals.jhered.a108749.
17. Wehrmaker A. Right-left asymmetry and situs inversus in Triturus alpestris. *W Roux' Archiv f Entwicklungsmechanik.* 1969;163:1–32. doi:10.1007/bf00576984.
18. Torgersen J. Situs inversus, asymmetry, and twinning. *Am J Hum Genet.* 1950;2(4):361.
19. Abdur-Rahman LO, Adeniran JO, Taiwo JO. Concurrent dextrogastric, reverse midgut rotation and intestinal atresia in a neonate. *J Indian Assoc Pediatr Surg.* 2007;12(4):228. doi:10.4103/0971-9261.40843.
20. Patle NM, Tantia O, Sasmal PK, Khanna S, Sen B. Laparoscopic Cholecystectomy In Situs Inversus—Our Experience of 6 Cases. *Indian J Surg.* 2010;72(5):391–4. doi:10.1007/s12262-010-0159-4.
21. Alsabek B, Arafat S, Aldirani A. A case report of laparoscopic cholecystectomy in situs inversus totalis: Technique and anatomical variation. *Int J Surg Case Rep.* 2016;28:124–6. doi:10.1016/j.ijscr.2016.09.004.
22. Song JY, Rana N, Rotman CA. Laparoscopic appendectomy in a female patient with situs inversus: case report and literature review. *J Soc Laparoendosc Surg.* 2004;8(2):175.
23. Pitiakoudis M, Tsaroucha AK, Katotomichelakis M, Polychronidis A, Simopoulos C. Laparoscopic Cholecystectomy in a Patient with Situs Inversus Using Ultrasonically Activated Coagulating Scissors. Report of a Case and Review of the Literature. *Acta Chir Belg.* 2005;105(1):114–7. doi:10.1080/00015458.2005.11679682.

**Cite this article:** Manyacka Ma Nyemb P, Emma Nsia R, Ndiaye A, Gaye M, Ndiaye A. Situs inversus totalis: Anatomic study and radioanatomic aspects about one case. *Indian J Clin Anat Physiol* 2020;7(4):407–411.