



## Original Research Article

## Variations in the origin of dorsalis pedis artery

Anju George<sup>1,\*</sup>, Lizamma Alex<sup>2</sup>, Anne George<sup>1</sup><sup>1</sup>Dept. of Anatomy, Government Medical College, Kottayam, Kerala, India<sup>2</sup>Dept. of Anatomy, Pushpagiri Institute of Medical Sciences, Tiruvalla, Kerala, India

## ARTICLE INFO

## Article history:

Received 10-10-2020

Accepted 27-10-2020

Available online 11-01-2021

## Keywords:

Dorsalis pedis

Dissection

Embryology

Variations

## ABSTRACT

**Background:** The dorsalis pedis artery poses a wide range of anatomical variations. Their embryological dimensions along with clinical importance cater the interest of anatomists on the artery. The available literature lacks in giving a proper insight into their development.

**Aims:** The present study aimed at studying the variations in the origin of dorsalis pedis artery by cadaveric dissection and to provide an embryological basis for them.

**Materials and Methods:** Dissection was conducted on fifty free lower limbs of formalin fixed cadavers. Variations in the origin of the artery were noted. The variations were embryologically correlated and their clinical relevance were reviewed.

**Results:** Of the 50 limbs dissected, normal origin of dorsalis pedis artery was found in 46 limbs (ie:92%). In three cases (6%) the artery originated from one among the other leg arteries. In one specimen the dorsalis pedis artery (DPA) was absent.

The variations were correlated with the embryological development of axis and femoral artery branches.

The variations were also classified under the standardized popliteal artery variants.

**Conclusions:** The arterial variations are embryological imprints. Knowing them provides great help for vascular surgeries, flap procedures, managing ischemic or diabetic foot, club foot correction etc. Imaging the vessels before surgery is always advocated.

© This is an open access article distributed under the terms of the Creative Commons Attribution License (<https://creativecommons.org/licenses/by/4.0/>) which permits unrestricted use, distribution, and reproduction in any medium, provided the original author and source are credited.

## 1. Introduction

The lower limb in man is specially designed for locomotion and weight bearing. The foot being the extreme end of lower limb is vulnerable to injuries especially in diabetic patients. The healing process of wounds depends on an effective arterial supply. Foot may also succumb to ischaemic changes if arterial supply is compromised due to atherosclerosis, diabetes mellitus or Buerger's disease.

The three below-knee arteries, namely the anterior tibial artery, the posterior tibial artery and the peroneal artery, provide rich nourishment to the foot through their branches and ample anastomosing channels.

The dorsum of foot is mainly supplied by dorsalis pedis artery. It is the continuation of anterior tibial artery distal to the ankle. It courses straight on the medial side of the dorsum giving branches and then dips into the sole to complete the plantar arterial arch.

Many significant variations from the classically described pattern have aroused profound interest. In certain cases, the dorsalis pedis artery has been found to be absent. Sometimes the posterior tibial or peroneal artery may become the major source of supply to the dorsum. In some cases the artery may be so thin or so short that distal part of dorsum is nourished by the plantar arteries.

Clinically, palpation of the dorsalis pedis arterial pulsation is important, particularly in suspected cases of arterial disorders like thromboangitis obliterans, thrombosis, acute embolism etc. Knowledge of the

\* Corresponding author.

E-mail address: [dranjugeorgetp@gmail.com](mailto:dranjugeorgetp@gmail.com) (A. George).

variations will be useful in deciding whether the absence of pulse in dorsalis pedis artery is due to thrombosis of the vessel, or due to an abnormal course, or its absence.

In cases of below-the-knee arterial occlusion, salvaging the ischaemic limb with the help of dorsalis pedis artery bypass graft is of great value. Cutaneous,<sup>1</sup> myocutaneous<sup>2</sup> or osseocutaneous<sup>3</sup> flaps based on dorsalis pedis have been in use in reconstructive surgeries. It can be a local transposition flap for the foot, or a free flap to reconstruct defects in head and neck, upper or lower extremities.<sup>4</sup> In rare cases where peroneal artery supplies the distal part of foot, peroneal artery-based fibular transfer (useful in maxillofacial surgery) could put the distal part of the limb at risk.<sup>5</sup>

A precise knowledge of the vascular anatomy of lower limb and its variations around the ankle is also indispensable for surgical techniques like transluminal angioplasty, embolectomy, bypass graft procedures, ankle arthroscopy and surgical release of club foot. It is also important for radiologists while interpreting the angiographic or doppler images of leg arteries.

Variations in the origin of blood vessels and their anomalous course can be attributed to their development. Depending on the functional dominance, some vessels regress, and some others deviate from their origin and course, from the principal vessel.<sup>6</sup> Limbs are characterized by numerous vascular interconnections so that one vessel can compensate for the other and thus maintain the pressure within the system.<sup>7</sup>

The developing lower limb bud is initially supplied by the axis artery to the limb. The femoral artery which is the major supply of lower limb is formed and canalized only later in intra-uterine life, and replaces the primitive axial artery. This change in arterial channels may also provide a chance for variations to occur.

Clinical relevance and embryological correlations makes the dorsalis pedis artery and its variations worth studying.

## 2. Materials and Methods

Dissection was done on fifty free lower limbs of cadavers. Dorsum of foot of these limbs were carefully dissected for the dorsalis pedis artery and its branches. An H shaped incision was made on the anterior part of leg and foot extending from the middle of leg to the proximal end of interdigital clefts. After reflecting the skin and superficial fascia, the superior and inferior extensor retinacula were identified. Both retinacula were divided to explore the artery beneath.

The artery was first searched for in the middle of the ankle and then followed distally. The proximal part of the artery was dissected carefully to confirm its origin. In case of variant origin search was continued proximally towards the rest of the leg to find the status of anterior tibial artery. The posterior crural region was also explored, to identify

any vessel contributing to the formation of dorsalis pedis. In such cases any change in the normal appearance of the other leg arteries were also looked into. The presence of any embryological remnant like persistent sciatic artery was looked for in the thigh.

The dorsalis pedis artery and its branches were painted for clearer view. The limbs were numbered and then photographs were taken. All the relevant observations were noted down and analyzed in depth. An effort was also made to provide an embryological basis to account for the observed variations. So also the clinical relevance of the different variations was looked into.

### 2.1. Study design

This was a descriptive study done by cadaveric dissection, conducted on fifty free lower limbs.

### 2.2. Inclusion criteria

The lower limbs of embalmed adult male and female cadavers, available in the Department of Anatomy of Pushpagiri Institute of Medical Sciences and Research Centre

### 2.3. Exclusion criteria

1. Presence of ischemic features like ulcers, gangrene on the limb.
2. Bony deformities of the lower limb, especially in the region of ankle and foot.
3. Limbs with thick walled arteries having an undulating appearance and presence of collaterals (signs of atherosclerotic occlusion).

### 2.4. Statistical analysis

The incidences of variations were calculated as percentages and plotted as tables and graphs.

## 3. Observations

The dorsalis pedis artery is classically described as the continuation of anterior tibial artery on the dorsum of foot. In the present study, in the majority of feet (46 cases), the arterial supply to the dorsum of foot was provided by the anterior tibial artery i.e., the origin of dorsalis pedis artery was considered normal in 92% of cases (Table 1).

**Table 1:** Variations in origin

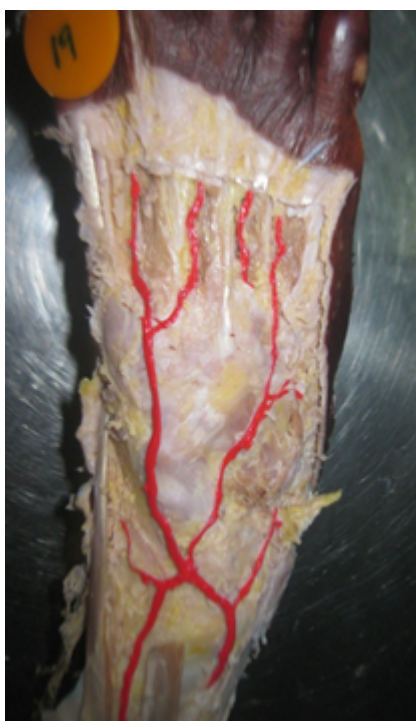Origin	Number	Percentage
Normal	46	92%
Variation	3	6%
Absence	1	2%

In three cases (6%) which we call variant origin, the artery originated from one among the other leg arteries.

**Table 2:** Details of dorsalis pedis arteries with variant origin

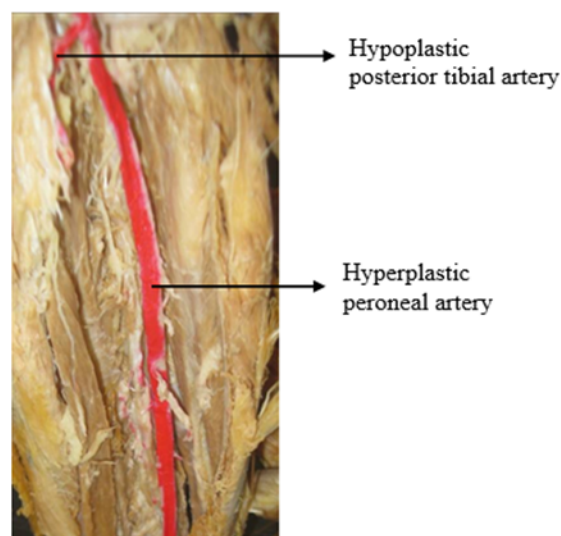
Specimen	Features	Other leg arteries	Persistent sciatic art.	Femoral artery
<b>Limb 19</b>	Perforating branch of peroneal joins ant. tibial to form dorsalis pedis	Peroneal hyperplastic; compensates for hypoplastic post. tibial	Nil	Normal
<b>Limb 28</b>	Ant. tibial hypoplastic; perforating branch of peroneal→dorsalis pedis	Peroneal hyperplastic; Normal post. tibial	Nil	Normal
<b>Limb 30</b>	Ant. tibial aplastic; perforating branch of post. tibial→dorsalis pedis	Normal peroneal & post. tibial arteries	Nil	Normal

The details regarding each of the observed variations in the origin of dorsalis pedis have been compiled in Table 2.

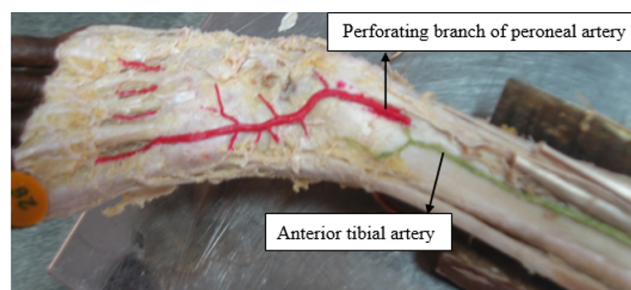
**Fig. 1:** Limb 19

In the limb numbered 19, a perforating branch of peroneal artery which entered the anterior crural region about five centimetres proximal to the ankle has been found to join the anterior tibial artery (ATA) to become the dorsalis pedis artery (Figure 1). The peroneal artery (PR) in the posterior crural region appeared hyperplastic. The posterior tibial artery (PTA) was also small in caliber, ending in the upper part of the posterior crural region (Figure 2). Arteries of the sole were also given off from peroneal artery. No significant change in size was noted in other lower limb arteries. There was no embryological remnant like persistent sciatic artery.

In the limb numbered 28, the perforating branch of peroneal artery seemed to give rise to the dorsalis pedis

**Fig. 2:** Limb 19

artery about five centimetres above the lateral malleolus (Figure 3). The anterior tibial artery with a thin end was also found to join it just proximal to the ankle. The peroneal artery in the posterior crural region appeared hyperplastic. However the posterior tibial artery appeared to be normal in calibre. No significant change in size was noted in the other lower limb arteries. There was no embryological remnant like persistent sciatic artery.

**Fig. 3:** Limb 28

In the limb numbered 30, the anterior tibial artery was found to be aplastic (Figure 4), and the posterior tibial artery was found to give rise to the dorsalis pedis artery. The posterior tibial and peroneal arteries were normal (Figures 5 and 6). No significant change in size was noted in the other lower limb arteries. No embryological remnants could be noted.

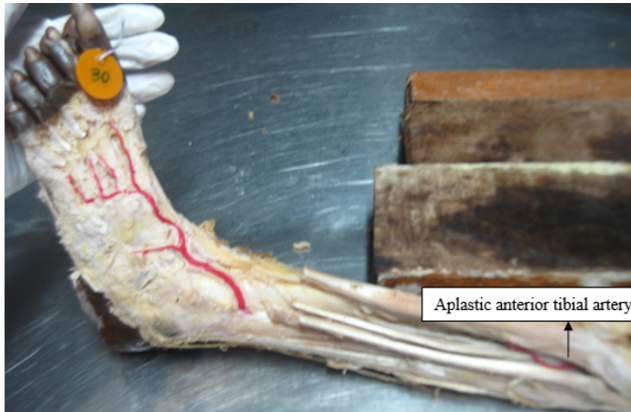


Fig. 4: Limb 30

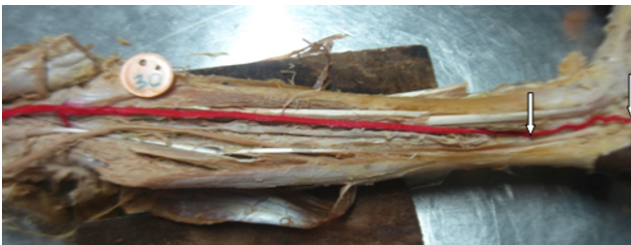

Fig. 5: Limb 30

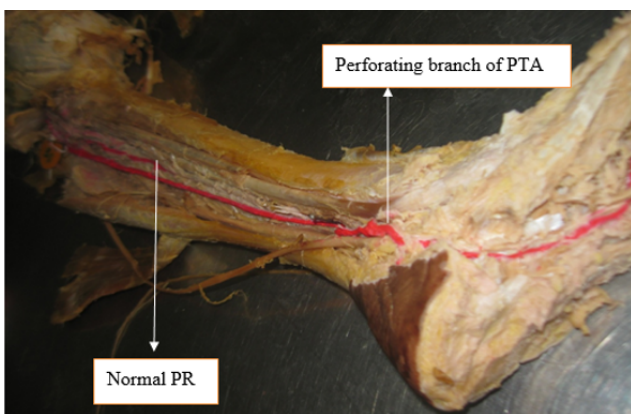


Fig. 6: Limb 30

In limb numbered 41, the anterior tibial artery failed to continue into the dorsum of foot as dorsalis pedis (Table 3). It was seen to divide into medial and lateral branches

about eight centimetres above the ankle (Figure 7). The medial branch was seen ending in the ankle region, and the lateral branch gave off one medial tarsal branch and one lateral tarsal branch. The arcuate artery was totally absent. The first dorsal metatarsal artery was seen to arise from the plantar arterial network. Posterior tibial appeared hyperplastic while peroneal artery was normal. No significant change in size was noted in other lower limb arteries. No embryological remnant could be detected in the specimen.

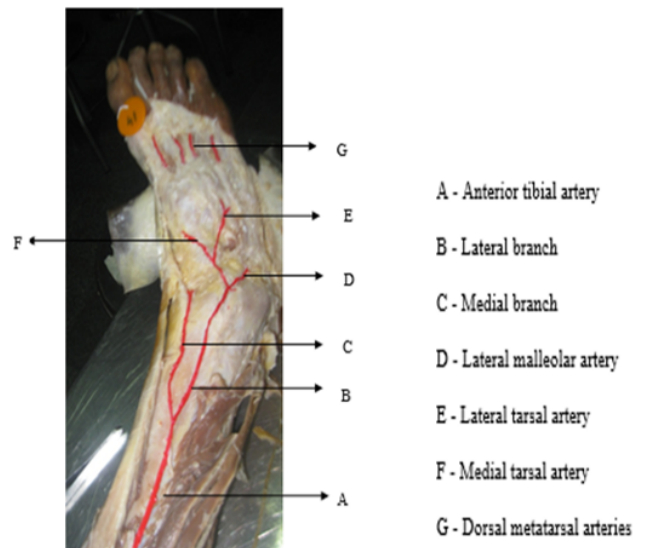


Fig. 7: Limb 41

#### 4. Discussion

##### 4.1. Development of lower limb arteries

The lower limb buds of the embryo develop by the end of fourth post fertilization week.<sup>8</sup> The early supply to developing limb bud, the axis artery, arises from the dorsal root of umbilical artery. It is also called as the sciatic artery [arteria nervi ischiadica]. It traverses the entire developing limb and terminates in the region of foot by dividing into a small network of branches.

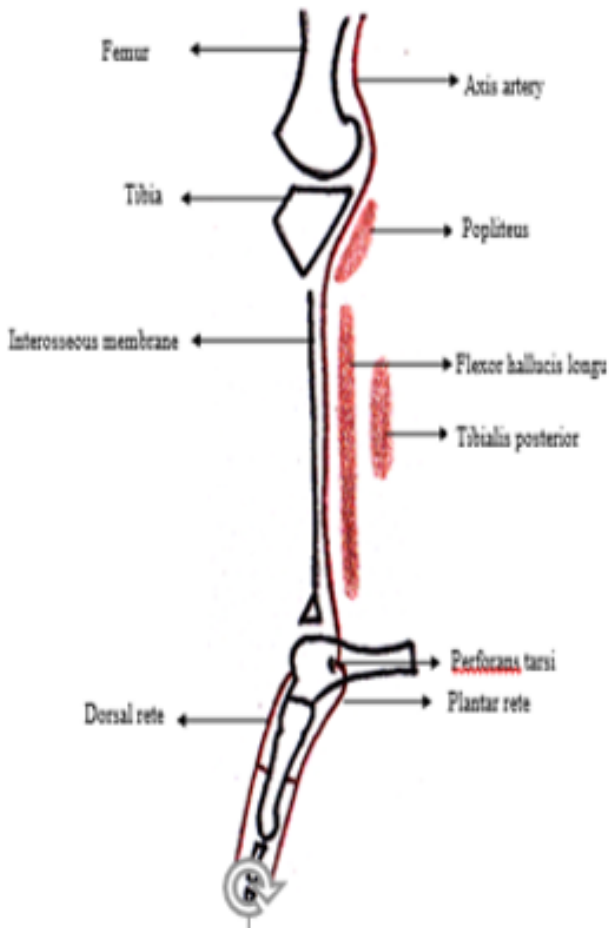
At 12 mm stage (about 38 days post fertilization) the axial artery is seen passing along the dorsal aspect of thigh, and then coursing down between the tibia and the popliteus behind the knee. It then descends down between the tibialis posterior and the interosseous membrane of the leg. In the foot it gives a perforator which traverses the sinus tarsi dorsally, to enter into the formation of an arterial network which supplies the dorsum of foot, the dorsal rete. It also provides branches which are seen to enter into the plantar rete as well [Figure 8].

At 14 mm stage, femoral arterial channels sprout from the external iliac artery through the ventral aspect of the thigh, and join the axis artery above the knee.

**Table 3:** Absence of dorsalis pedis artery

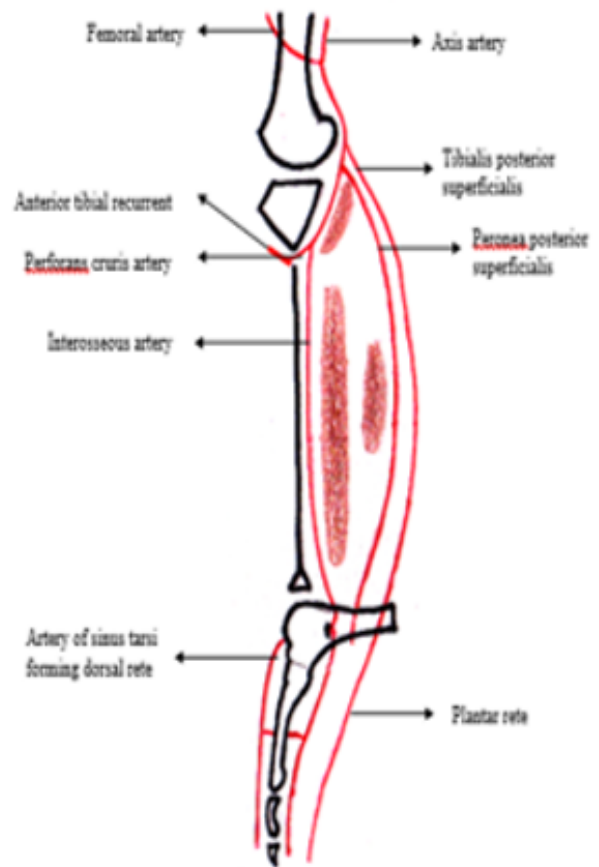
Specimen	Features	Other leg arteries	Femoral artery	Persistent sciatic art.
Limb 41	Anterior tibial divided into medial & lateral branches above the ankle	PTA appeared hyperplastic, PR normal	Normal	Nil

The axis artery at this stage gives off two branches in the leg at the proximal end of popliteus, i.e., tibialis posterior superficialis artery (TPSA) and peronea posterior superficialis (primitive fibular artery). Both of them traverse down and gain entry into the sole. At the distal end of popliteus, the axis artery gives off a sprout called perforans cruris artery which pierces the interosseous membrane and later becomes the artery of the anterior compartment of leg.[Figure 9]



**Fig. 8:** Arterial development at 12 mm

By 16 mm stage a tibialis anterior pars distalis artery continues to grow from the perforans cruris artery and courses down through the anterior crural region, identical to the path taken by the adult anterior tibial artery.<sup>9,10</sup>



**Fig. 9:** Arterial development at 14 mm

By the 18 mm stage a new channel seems to descend down from primitive fibular artery, lying between the tibialis posterior and flexor hallucis longus. This artery, named inferior communicating artery communicates with the axis artery above the lateral malleolus, and later forms the adult peroneal or fibular artery.<sup>9,11</sup>[Figure 10].

At 22 mm stage, three arteries disappear, namely the part of axis artery deep to popliteus, the primitive fibular artery and the interosseous artery. At the same time in the region superficial to the popliteus muscle, the popliteal artery is formed by the fusion of proximal parts of tibialis posterior superficialis and peronea posterior superficialis arteries [Figure 11].

Between 22-25 mm stages (around 49-52 days post fertilization), the femoral artery becomes the major source of supply to the lower limb, incorporating some remnants

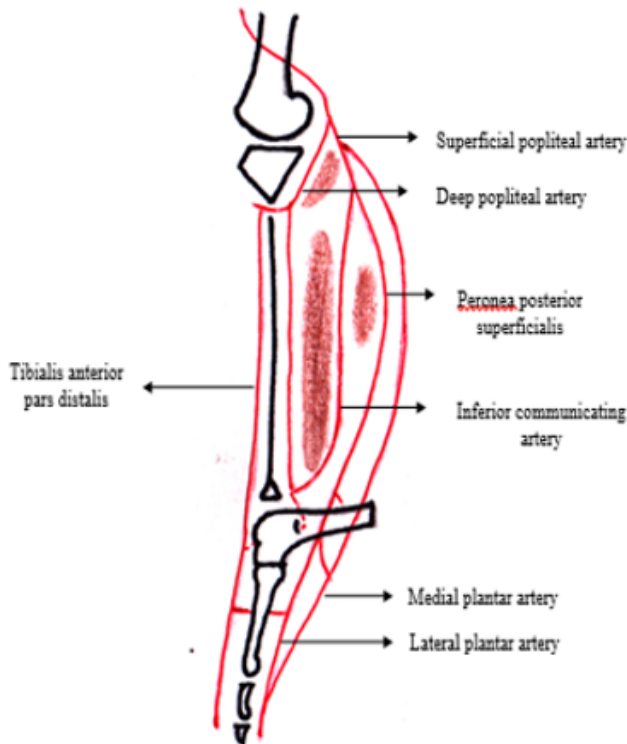


Fig. 10: Arterial development at 18 mm

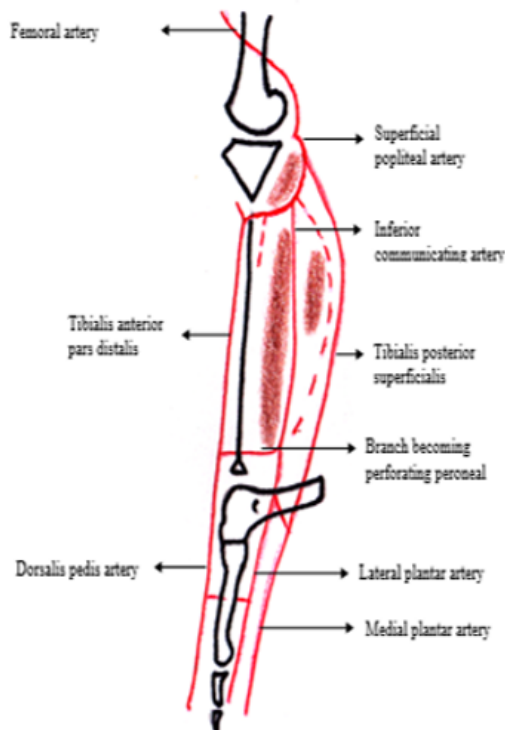


Fig. 11: Arterial development at 22 mm

of sciatic artery in it. The popliteal and peroneal arteries are remnants of axial artery, whereas the anterior tibial and posterior tibial are derived from the femoral system.<sup>9,12</sup> Being a derivative of the axial artery, the peroneal artery is constant and its true absence has never been reported.<sup>13,14</sup>

#### 4.2. Adult pattern of arteries

Fibular/ peroneal artery arises from the posterior tibial artery 2.5 cm distal to popliteus. It descends in a fibrous canal between tibialis posterior and flexor hallucis longus. Reaching the inferior tibio-fibular syndesmosis, it ends by dividing into a network of calcaneal branches. The fibular artery has branches like the muscular arteries, the nutrient artery of fibula, the perforating branches, the communicating branch to posterior tibial artery etc. The perforating branches of fibular artery are two in number. The branch given off five centimeters proximal to lateral malleolus pierces the interosseous membrane to anastomose with the anterior lateral malleolar branch of anterior tibial artery. The second perforator is a branch descending in front of the tibio-fibular syndesmosis and anastomosing with lateral tarsal artery. Both these branches can sometimes enlarge to replace the dorsalis pedis artery.

The size of the fibular artery tends to be inversely related to the size of the other arteries of the leg. It may be reduced in size, but more often it is enlarged when it may join, reinforce or even replace the anterior or posterior tibial artery in the distal part of the leg and the foot.<sup>15</sup>

Variability in the crural arteries depends on both the regression of the sciatic artery, and on the persistence of its junction with the primary femoral artery in the popliteal region.<sup>16</sup>

#### 4.3. Variations in the origin of dorsalis pedis

The dorsalis pedis artery was noted to have variations in origin in three cases (6%). Complete absence of the artery was noted in one case.

Vijayalakshmi et al., noted eight percent cases of variant origin in their study. Ali M W et al., in 1996 noted only one percent of variant origin after dissecting 100 limbs.<sup>17</sup> Rajeshwari et al., (2013) did not report any variation in origin after studying the dorsalis pedis artery in cadaveric limbs.<sup>18</sup> However many individual cases of variant origin have been reported in literature as case reports.

Kim D et al., in 1989 proposed a classification on the popliteal and tibial arterial variants from their arteriographic study on 1000 popliteal arteries and 495 tibial arteries of leg and foot.<sup>12</sup> Types I and II were concerned with patterns of popliteal artery branching while type III was regarding the hypoplasia or aplasia of tibial vessels (grouped as 'Hypoplastic or aplastic branching with altered distal supply'). According to them Type IIIA was hypoplastic posterior tibial artery and the distal posterior tibial artery

replaced by the (hyperplastic) peroneal artery. Type IIIB: hypoplastic anterior tibial artery and the dorsalis pedis artery replaced by the (hyperplastic) peroneal artery. Type IIIC: both the anterior tibial artery and the posterior tibial artery are hypoplastic and both dorsalis pedis and posterior tibial arteries were replaced by the peroneal artery. They had also suggested that the variant arterial supply to the foot can be suspected from the arteriographs of the popliteal region.

#### 4.3.1. Types of variant origin

4.3.1.1. Peroneal artery contributing to dorsalis pedis. A perforating branch of the peroneal artery was noted to join the anterior tibial artery at the level of navicular bone, to form the artery of the dorsum of foot [Figure 1] as seen in limb number 19.

Since a variation in origin was noted exploration of other lower limb arteries was also done to note their status. The peroneal artery appeared hyperplastic. The posterior tibial was small in caliber or appeared hypoplastic (Figure 2). Small arteries to the sole of foot were also seen to be given off from the peroneal artery. No significant change in size was noted in other lower limb arteries. There was no embryological remnant like persistent sciatic artery.

This variation was grouped type III C of popliteal arterial variant.

4.3.1.2. Embryological correlation. In this limb, dorsalis pedis artery was of lesser caliber compared to perforating branch of peroneal artery. So the caliber of peroneal artery could have been increased in order to compensate for the reduced functional capacity of the anterior tibial artery. The perforating branch in this case can be considered as the source of major arterial supply to the dorsum. The pars distalis part of the anterior tibial artery in the anterior aspect of leg has developed but failed to reach its usual goal, namely the arterial network on the dorsum of foot. And therefore it has to be compensated by the enlargement of the perforating branch which is a connection normally present between anterior tibial and peroneal arteries.

The dorsalis pedis formed from peroneal and the anterior tibial arteries accepting rather equal shares has been reported by Lappas et al., (2% of cases).<sup>19</sup> Such a case was also reported by Huber in his study.<sup>20</sup> Both the arteries jointly forming the dorsalis pedis artery, with apparently almost equal contributions is not a commonly reported occurrence in the available literature.

Suhani et al., in 2014 reported a case of simultaneous occurrence of hypoplastic anterior and posterior tibial arteries, both being replaced by a hyperplastic peroneal artery.<sup>21</sup> In that case both the dorsal and plantar aspects of foot were supplied by the peroneal artery. Kim D et al, and Kil SW et al., reported 0.2% and 0.8% incidence of hypoplasia in the anterior and posterior tibial arteries respectively from their arteriographic study on infra-popliteal vessels.<sup>12,22</sup> Lappas et al., reported 1.5% of

occurrence of similar hypoplasia in their dissection study.<sup>23</sup> No further information could be obtained from other authors who studied the same region.

Limb number 28 showed anterior tibial artery though present was too hypoplastic to supply the area destined for it and the perforating branch of peroneal artery was continuing as dorsalis pedis artery [Figure 3]. The anterior tibial artery terminated as a fibrotic band seemingly attached to the perforating artery, as the latter pierced the tibio-fibular interosseous membrane.

The other major arteries in this lower limb specimen were also explored. The peroneal artery appeared hyperplastic while the posterior tibial artery was normal. No significant change in size was noted in other lower limb arteries. There was no persistent sciatic artery notable.

This variation has been grouped under type III B of popliteal arterial variant.

4.3.1.3. Embryological correlation. Here the anterior tibial artery was very much hypoplastic and was seen just as a fibrous connection with the perforating branch of peroneal artery, about three centimetres above the ankle. The perforating branch of peroneal artery was well developed to compensate for the deficiency of anterior tibial artery. Even then it could not supply the entire dorsum, and the metatarsal arteries were being supplied by posterior tibial artery via, the plantar network. Here, the pars distalis part of tibialis anterior artery failed to reach its usual goal i.e., the dorsal arterial network. And so the peroneal artery had to compensate for the supply of proximal dorsum through its normal communication. Owing to the same reason, the posterior tibial artery also has to supply the distal dorsum.

This anomaly with a normal posterior tibial artery, but with aplastic or hypoplastic anterior tibial artery, getting replaced by the peroneal artery, had been classified as type IIIB among the popliteal artery variants.

Such anomaly had been reported in many studies. Huber had observed six such cases (3%), Vijayalakshmi et al., had such four cases (8%) and Lappas et al., had three such cases (1.5%) in their dissection studies. Proportions of 7.1% (Adachi 1928),<sup>24</sup> 5% (Keen 1961),<sup>25</sup> 6% (Lippert 1985)<sup>26</sup> have also been reported in literature. Shetty et al, and Vaishnavi et al, also have reported one case each.<sup>27,28</sup> Arteriographic studies also revealed the occurrence of 1.6%<sup>12</sup> 1.7%<sup>22</sup> and 2.3%<sup>29</sup> of similar variations. Our single case (2%) of hypoplastic anterior tibial also comes within the range of 1.5% to 8% of such reported variations.

#### 4.3.2. Posterior tibial artery contributing to dorsalis pedis [Distal part of anterior tibial absent]

One among the fifty specimens i.e., limb number 30 (Figures 4, 5 and 6) showed aplasia of anterior tibial artery. ATA terminated in the upper part of the anterior compartment. A perforating branch of posterior tibial artery was noted to continue as the dorsalis pedis artery. The

posterior tibial artery in the region just above the ankle joint gave a perforating branch which pierced the interosseous membrane and continued as dorsalis pedis artery. The size of the continuing dorsalis pedis artery was similar to that of the perforating branch of posterior tibial artery. So it can be considered as the main source of nourishment to the dorsum of foot.

After giving off the perforator, the posterior tibial artery entered the sole and divided into medial and lateral plantar arteries (Figure 5). The femoral, popliteal and peroneal arteries were of normal origin, course and termination (Figure 6).

This type has not been classified specifically as any popliteal variant.

**4.3.2.1. Embryological correlation.** The portion of anterior tibial artery situated in the anterior compartment is the developmental derivative of two embryonic vessels, namely the perforating cruris artery and pars distalis of anterior tibial artery. In the case of limb number 30, the perforating cruris and anterior tibial recurrent branch formed from it have retained a normal relationship as found in the embryo of 14 mm length. The pars distalis which should develop later (in 18 mm stage) had either failed to appear, or having appeared had undergone degeneration, and the branch from posterior tibial artery took up its function. The presence of a large recurrent branch is more in favour of degeneration after appearing, rather than a failure to appear.

Atanasova et al., reported a single case of posterior tibial replacing hypoplastic or aplastic anterior tibial artery.<sup>30</sup> This was a rarer anomaly compared to the compensation commonly given off from the peroneal artery. Peroneal artery has communicating branches with anterior and posterior tibial arteries and so in most cases the peroneal artery was found to compensate for either of their deficiencies. At the same time, posterior tibial artery normally does not have a communicating branch to the anterior tibial artery.

#### 4.3.3. Dorsalis pedis artery absent

In the limb number 41, the anterior tibial artery was seen dividing into a medial and a lateral branch (Figure 5) about eight centimetres above the ankle. Both branches were noted to be of reduced calibre. The medial branch ended in the ankle region, and the lateral branch reached just antero-medial to the lateral malleolus. It gave off a lateral malleolar branch at this site, and then passing forwards it divided into one medial and two lateral tarsal arteries over the talus. The branches could not meet the needs of the rest of the dorsum of foot and so all the dorsal metatarsal arteries were noted to be arising from the arteries of the sole. This type of absence of dorsalis pedis was not seen in the available literature. Present study attributes a two percent chance for absent dorsalis pedis artery.

There were other types of anatomical absence of dorsalis pedis, as reported by Vijayalakshmi et al. But in their description, there was the perforating peroneal artery which failed to continue as dorsalis pedis artery distal to the ankle. Other investigators reported percentages 12%,<sup>20</sup> 6.7%,<sup>31</sup> 3%<sup>24</sup> and 2.2%<sup>32</sup> of chances of absent dorsalis pedis artery in their dissection studies. Robertson et al., quoted Hamilton Bailey saying, in 10% of persons the dorsalis pedis artery was congenitally absent in its usual position, and therefore lack of its pulsation is valueless unless corroborated by other signs of peripheral vascular disease.

**4.3.3.1. Embryological correlation.** The course of the lateral branch over the lateral malleolus could be satisfactorily related to the temporary ascendancy maintained by the perforating branch of peroneal artery over the distal part of the tibialis anterior artery during a sufficiently long period of development. This might have resulted in an artery (corresponding to lateral branch) ascending to join the pars distalis part of tibialis anterior artery. This might have happened as anterior tibial artery had smaller caliber to reach its usual region of supply.

## 5. Source of Funding

None.

## 6. Conflict of Interest

The authors declare no conflict of interest.

## References

- Governa M, Barisoni D. Distally based dorsalis pedis island flap for a distal lateral electric burn of the big toe. *Burns*. 1996;22(8):641–3. doi:10.1016/s0305-4179(96)00044-7.
- Pinal FD, Herrero F. Extensor digitorum brevis free flap: anatomic study and further clinical applications. *Plast Reconstr Surg*. 2000;105:1347.
- Zuker RM, Manktelow RT. The dorsalis pedis flap: technique of elevation, foot closure and flap application. *Plast Reconstr Surg*. 1986;77(1):93–102.
- Samson MC, Morris SF, Tweed AEJ. Dorsalis Pedis Flap Donor Site: Acceptable or Not? *Plast Reconstr Surg*. 1998;102(5):1549–54. doi:10.1097/00006534-199810000-00031.
- Fernandes R. Fibula Free Flap in Mandibular Reconstruction. *Atlas Oral Maxillofac Surg Clin*. 2006;14:143–50. doi:10.1016/j.cxom.2006.05.003.
- Vijayalakshmi S, Raghunath G, Shenoy V. Anatomical study of dorsalis pedis artery and its clinical correlations. *J Clin Diagn Res*. 2011;5(2):287–90.
- Woollard HH, Weddell G. Arterial vascular patterns. *J Anat*. 1934;69(1):25–37.
- Moore KL, Persaud TVN. The limbs. The developing Human, Clinically oriented embryology. 8th ed. Philadelphia: Saunders Elsevier; 2008.
- Senior HD. The development of the arteries of the human lower extremity. *Am J Anat*. 1919;25(1):54–95. doi:10.1002/aja.1000250105.
- Funke C, Kuhn HJ. The morphogenesis of the arteries of the pelvic extremity. A comparative study of mammals with special reference to the tree shrew *Tupaia belangeri* (Tupaiaidae, Scandentia, Mammalia). *Adv Anat Embryol Cell Biol*. 1998;144:1–97.



11. Standring S, Mahadevan V, Collins P. Development of pelvic girdle and lower limb. Gray's Anatomy. 40th ed. Elsevier; 2008.
12. Kim DS, Orron DE, Skillman JJ. Surgical significance of popliteal arterial variants. A unified angiographic classification. *Ann Surg.* 1989;210:776–81.
13. Hollinshead WH. Anatomy for surgeons. New York: Harper & Row; 1969.
14. Jiji PJ, D'Costa S, Nayak SR. Hypoplastic posterior tibial artery and the enlarged peroneal artery supplying the posterior crural region: a rare variation. *J Vasc Bras.* 2008;7(3):272–4.
15. Standring S, Mahadevan V. Gray's Anatomy. 40th ed. Elsevier; 2008.
16. Szpinda M. An angiographic study of the anterior tibial artery in patients with aortoiliac occlusive disease. *Folia Morphol(Warsz).* 2006;65(2):126–31.
17. Ali MW, Mohajir AM. Dorsalis pedis artery: Variations and Clinical Significance. *J Indian Med Assoc.* 1996;94(11):417.
18. Rajeshwari MS, Roshankumar BN, Kumar V. An anatomical study on dorsalis pedis artery. *Int J Anat Res.* 2013;1(2):88–92.
19. Lappas D, Stavropoulos NA, Noussios G. Anatomic study of infrapopliteal vessels. *Folia Morphol.* 2012;71(3):167.
20. Huber JF. The Arterial Network Supplying the Dorsum of the Foot. *Anatomical Record.* 1941;80:373–91.
21. Sumalatha S, Periyasamy V, Bhatt R. Anomalous Branching Pattern of the Popliteal Artery: A Case Report. *J Clin Diagn Res.* 2014;8(6):AD01–2.
22. Kil SW, Jung GS. Anatomical Variations of the Popliteal Artery and its Tibial Branches: Analysis in 1242 Extremities. *Cardio Vasc Int Radiol.* 2009;32:233–40. doi:10.1007/s00270-008-9460-z.
23. Adachi B. Das Arteriensystem der Japaner. Verlag der Kaiserlich-Japanischen Universität zu Kyoto; 1928.
24. Keen JA. A study of the arterial variations in the limbs, with special reference to symmetry of vascular patterns. *Am J Anat.* 1961;108(3):245–61. doi:10.1002/aja.1001080303.
25. Lippert H, Pabst R. Arterial variations in man: classification and frequency. J.F. Bergmann-Verlag München; 1985.
26. Shetty SD, Nayak S, Kumar N, Abhinitha P. Hypoplastic Anterior Tibial Artery Associated with Continuation of Fibular (Peroneal) Artery as Dorsalis Pedis Artery: A Case Report. *Int J Morphol.* 2013;31(1):136–9. doi:10.4067/s0717-95022013000100022.
27. Vaishnani H, Gujar S, Gadekar S. An abnormal unilateral origin of dorsalis pedis artery- a case report; 2014. Available from: [www.themedicalacademy.in](http://www.themedicalacademy.in).
28. Mauro MA, Jaques PF, Moore M. The popliteal artery and its branches: embryologic basis of normal and variant anatomy. *Am J Roentgenol.* 1988;150(2):435–7. doi:10.2214/ajr.150.2.435.
29. Atanasova M, Georgiev GP, Jeleu L. Intriguing variations of the tibial arteries and their clinical implications. *Int J Anat Var.* 2011;4:45–7.
30. Yamada T, Gloviczki P, Bower TC. Variations of the arterial anatomy of the foot. *Am J Surg.* 1993;166(2):130–5.
31. Chavatzas D. Revision of the incidence of congenital absence of dorsalis pedis artery by an ultrasonic technique. *Anat Rec.* 1974;178(2):289–90. doi:10.1002/ar.1091780211.
32. Robertson GSM, Ristic C, Bullen BR. The incidence of congenitally absent foot pulses. *Ann Rl Coll Surg Engl.* 1990;72:99–100.

### Author biography

**Anju George**, Assistant Professor

**Lizamma Alex**, Professor

**Anne George**, Associate Professor

**Cite this article:** George A, Alex L, George A. Variations in the origin of dorsalis pedis artery. *Indian J Clin Anat Physiol* 2020;7(4):354-362.