



Original Research Article

Effect of metformin on Bax expression in pancreas and testis of normoglycemic albino rat: An immunohistochemical study

Hagar A Hashish^{1,*}¹Dept. of Anatomy, Faculty of Medicine, Mansoura University, Mansoura, Egypt

ARTICLE INFO

Article history:

Received 17-04-2020

Accepted 29-04-2020

Available online 27-06-2020

Keywords:

Bax
Metformin
Pancreas
Testis

ABSTRACT

Background: Metformin is a famous drug used to reduce blood glucose level. It could be used in treatment of polycystic ovarian syndrome. Metformin also demonstrated an anticancer activity. Bax, is one of the cellular apoptotic markers. Metformin was documented to increase the level of Bax protein.

Aim of the Study: Based on the known facts about metformin and its new role as a potential inducer of cellular apoptosis, the current study has been designed to investigate the probable effects of the in-vivo metformin administration on the pancreatic and testicular tissues in normoglycemic rats, and its probable effect on Bax expression as one of the markers of cellular apoptosis

Materials and Methods: Twenty rats divided in two groups; control and treated. Metformin treated rats were given 400mg/kg /day through oro-gastric tube for one month. After one month, rats in all groups were sacrificed, the pancreas and testis were dissected out to prepare paraffin sections, stained by hematoxylin&eosin, Masson's trichrome stains and Bax immunohistochemical stain.

Results: Metformin treated group showed reduced pancreatic islets' size with degenerated cells in both endocrine and exocrine parts, more fibers surrounding pancreatic acini, islets and blood vessels. Bax immunostaining showed intense reaction especially in the islets of Langerhans. The seminiferous tubules (STs) of the testis were irregular with disturbed degenerated spermatogenic cells. Extensive fibers surrounding seminiferous tubules and in the wall of the blood vessels were detected. Bax immunostaining showed intense reaction in the testis germinal cells of the treated group.

Conclusion: Our study revealed that metformin induced expression of Bax in pancreatic and testicular tissues of normal rats when used for one month, which will affect their viability and function. Its effect on Bax expression might be promising as a possible treatment in case of cancer, however, it should be used with caution.

© 2020 Published by Innovative Publication. This is an open access article under the CC BY-NC license (<https://creativecommons.org/licenses/by-nc/4.0/>)

1. Introduction

Metformin is a famous drug which is used safely to reduce blood glucose level. It could be used in treatment of polycystic ovarian syndrome.¹ Metformin also demonstrated an anticancer activity in human. It affected the cell viability with induction of cellular apoptosis in hepatocellular carcinoma² and in cancer breast.³ It induced cellular apoptosis in colorectal cancer,⁴ cervical cancer,⁵ ovarian carcinoma⁶ and leukemia.⁷

Metformin as a drug has its side effects; lactic acidosis and pancreatitis has been reported with its use.⁸ Metformin induced pancreatitis was reported as a result of drug overdose and acute renal failure.⁹ However, it was reported in a healthy person without any pre-existing factor.⁸ Metformin was found to induce seminiferous tubules degeneration and atrophy when used with glibenclamide, oral anti-diabetic medication, in non diabetic rats for 21 days.^{10,11}

The exact mechanism of metformin toxicity in pancreas is not clear. It might be a result of acinar cell degeneration in patients with renal failure leading to leakage of digestive enzymes from pancreatic ducts to the intercellular space.¹²

* Corresponding author.

E-mail address: dr.hagar1979@gmail.com (H. A. Hashish).

BCL2-associated X protein (Bax), is one of the essential proteins that regulates the mitochondrial permeability apoptotic signaling. It enhances release of mitochondrial cytochrome c to the cytosol to react with the apoptotic peptidase activating factor, forming the apoptosome which induces caspase 9 and finally results in cell death. It was documented that in-vitro incubation of cells with metformin increased the level of Bax protein and reduced the anti apoptotic proteins Bcl2, hence, it was confirmed that metformin induced mitochondrial mediated apoptosis.¹³

Based on the known facts about metformin and its new role as a potential inducer of cellular apoptosis, the current study has been designed to investigate the probable effects of the in-vivo metformin administration on the pancreatic and testicular tissues in normoglycemic rats, and its probable effect on Bax expression as one of the markers of cellular apoptosis.

2. Material and Methods

2.1. Experimental animals

Twenty adult male Sprague dawley rats (200-250 gm) were used in this study. The animals were housed in clean separate cages, in adequate temperature (18°C) and humidity (45%). Food and water were available with free access according to the rules. This experiment was carried out according to the instructions of the Ethical Committee, Mansoura Faculty of Medicine, Egypt.

2.2. Experimental protocol

The animals were divided into 2 groups on random base, 10 rats each.

Group 1 (CN): Rats received oral vehicle for one month.

Group 2 (ME): Metformin treated rats; the drug was given through oro-gastric tube in a dose of 400 mg/kg/day for one month. This dose is approximately equivalent to ≈2000 mg/day in human (the maximum allowed daily dose), based on Reagan-Shaw equation ; human dose = animal dose × animal (km)/human (km).¹⁴

2.3. Biochemical study

2.3.1. Fasting blood glucose level

It was measured by obtaining a drop of blood from the tail vein in control and treated rats at the beginning and the end of the experiment. Glucose level was checked by using ACCU-CHEK glucose test strip (Roche Diagnostic Co., Germany).

2.3.2. Serum level of pancreatic lipase enzyme

It was measured by collecting blood samples from control and treated rats at the beginning and the end of the experiment.

2.3.3. Sacrifice of rats and specimens collection

After one month, rats in all groups were sacrificed after anaesthesia using Ketamine intraperitoneal injection (60 mg/kg). The pancreas and testis were dissected out to prepare paraffin sections. Sections were stained by hematoxylin and eosin (H&E), Masson's trichrome stains and Bax immunohistochemistry.

For Bax immunohistochemistry, sections (5μ) were prepared. Antigen retrieval was performed in citrate buffer solution in microwave oven at 700 W. The sections were allowed to cool, and washed in distilled water. The primary antibody was applied overnight. Secondary antibody was applied for 20 min. Then exposed to streptavidin-peroxidase for about 20 min. Counterstaining was done with Hematoxylin and washed in tap water for 3 min then in distilled water for 3 min. Finally, the slides were mounted.¹⁵ All chemicals were obtained from Sigma Aldrich, USA.

2.4. Morphometric study

The area % of excess fibers formation in the pancreas and testis was measured in Masson's trichrome stained sections in 10 non overlapped fields randomly. The area % of Bax immunostaining was measured in 10 random non overlapped fields selected randomly. Diameter of pancreatic islets and seminiferous tubules was measured in 10 random non overlapped fields per unit area.

Morphometric study was carried out through NIH Image J program (USA).

2.5. Statistical analysis

Data were expressed as means ± SEM. The analysis of variance between different groups was done by (ANOVA). P < 0.05 was considered as significant. The statistical analysis was done by SPSS program, version 22.

3. Results

3.1. Histological results

Histological examination revealed that metformin induced changes in pancreatic and testicular tissues of treated rats. The H&E sections of control group pancreas showed well defined exocrine and endocrine parts. The islets of Langerhans appeared spherical in shape, cells were arranged in trabecular pattern with acidophilic cytoplasm, and rounded nuclei. The Beta cells were in the center and Alpha cells were in the periphery (Figure 1 A). Masson trichrome sections showed thin connective tissue septa surrounding pancreatic acini and islets (Figure 1 C). Bax immunostaining showed negative reaction especially in the Islets of Langerhans (Figure 1 E).

On the other hand, the metformin treated group showed in H&E sections reduced islets' size with deeply

stained degenerated cells in both endocrine and exocrine parts (Figure 1 B). Masson trichrome sections revealed excess fibers surrounding pancreatic acini, islets and blood vessels with thickened wall (Figure 1 D). Bax immunostaining showed intense reaction especially in the islets of Langerhans and also exocrine pancreas (Figure 1F).

Histological examination of testicular tissue in both groups revealed that in the treated rats the seminiferous tubules (STs) were irregular in outline, disturbed organization of germinal epithelium, spermatogenic cells were separated from basement membrane with signs of degeneration (Figure 2 B). The diameter of STs showed significant reduction in the treated group in comparison with the control group. While, in the testicular tissue of the control group, the seminiferous tubules had well organized germinal cells arranged in layers. (Figure 2 A). Masson trichrome section in treated group showed extensive fibrosis between STs and surrounding them. Fibrosis was detected also in blood vessels (Figure 2 D). Bax immunostaining showed intense reaction in the germinal cells of the treated group (Figure 2 F,H), in contrast to the negative reaction in control testicular tissue (Figure 2 E,G.).

3.2. Biochemical results

3.2.1. Fasting blood glucose level

The fasting blood glucose level showed insignificant change between the control and treated group (Chart 1).

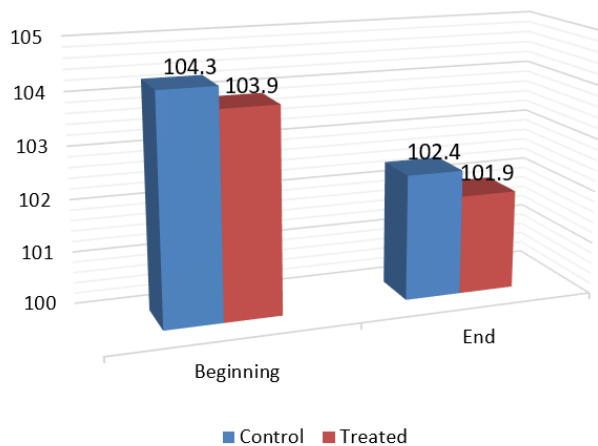


Chart 1: The fasting blood glucose level showed insignificant change between the control and treated group (P value >.05)

3.2.2. Pancreatic enzymes

Serum level of pancreatic lipase enzyme showed significant elevation in the treated group at the end of the experiment (Chart 2).

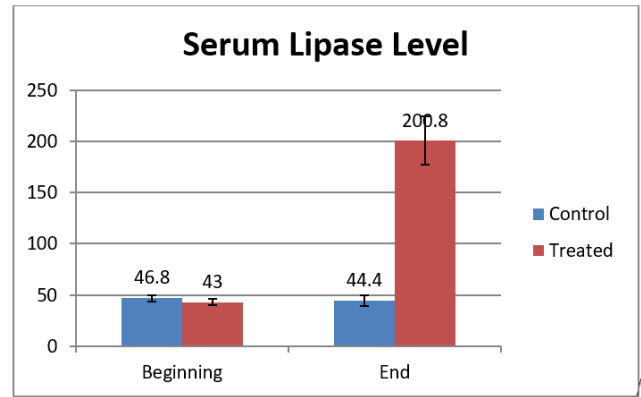


Chart 2: Serum level of pancreatic lipase enzyme showed significant elevation in the treated group at the end of the experiment (P value <.05)

3.3. Morphometrical results

3.3.1. Mean area % of collagen fibers in pancreas and Testis:

The mean area % of collagen fibers accumulation in treated pancreas and testis showing significant increase in comparison to control group (Chart 3).

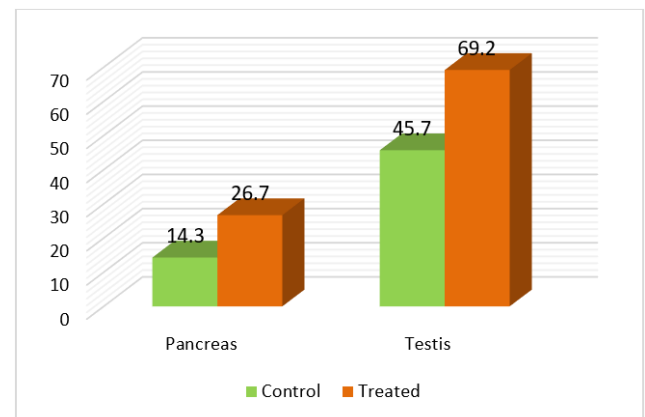


Chart 3: The mean area % of collagen fibers accumulation in treated pancreas and testis showing significant increase in comparison to control group (P value <.05).

3.3.2. Mean area % of Bax immunostaining in pancreas and Testis:

The mean area % of Bax immunostaining in treated pancreas and testis showing significant increase in comparison to control group (Chart 4).

3.3.3. Diameter of pancreatic islets and STs

Significant reduction in pancreatic islets and seminiferous tubules diameters in treated group when compared to control group (Chart 5).

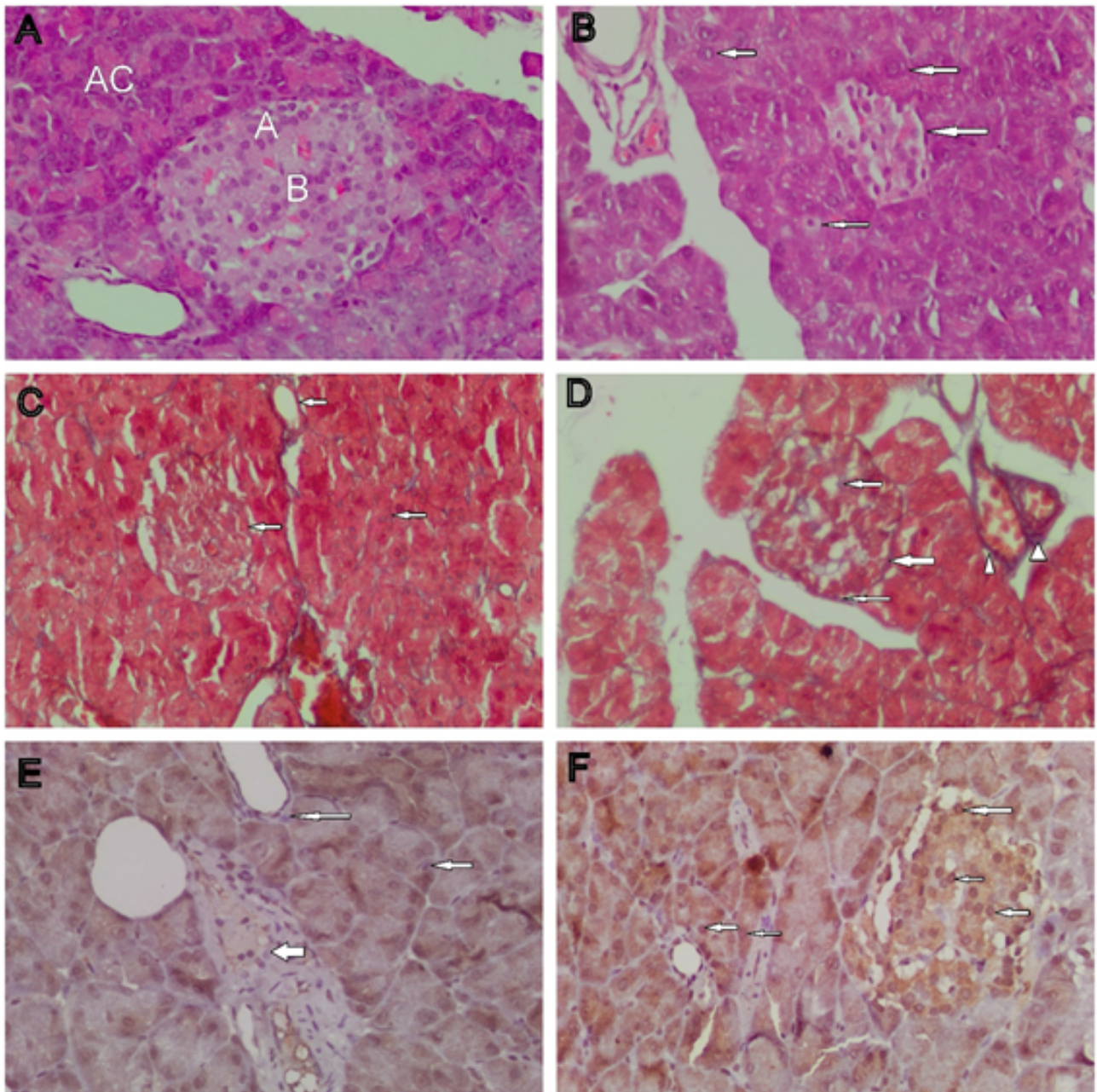


Fig. 1: **A):** Photomicrograph of a control pancreas showing acinar cells in the exocrine part (AC), well defined islets of Langerhans with Alpha cells (A), Beta cells; **B):** Metformin treated pancreas, showing atrophied islets with degenerated vacuolated cells in endocrine and exocrine pancreas (arrows). (H&E X 400); **C):** Control pancreas showing delicate fibers of collagen surrounding the Langerhans islets, pancreatic acini and blood vessels (arrows); **D):** Metformin treated pancreas with dense collagen fibers around the islets and acinar cells (arrows), thickened blood vessels media (arrow heads). (Masson trichrome X 400); **E):** Control pancreatic section showing negative reaction for Bax in endocrine and exocrine parts (arrows); **F):** Metformin treated pancreas showing positive reaction for Bax in endocrine and exocrine parts (arrows). (Bax immunoreactivityX400).

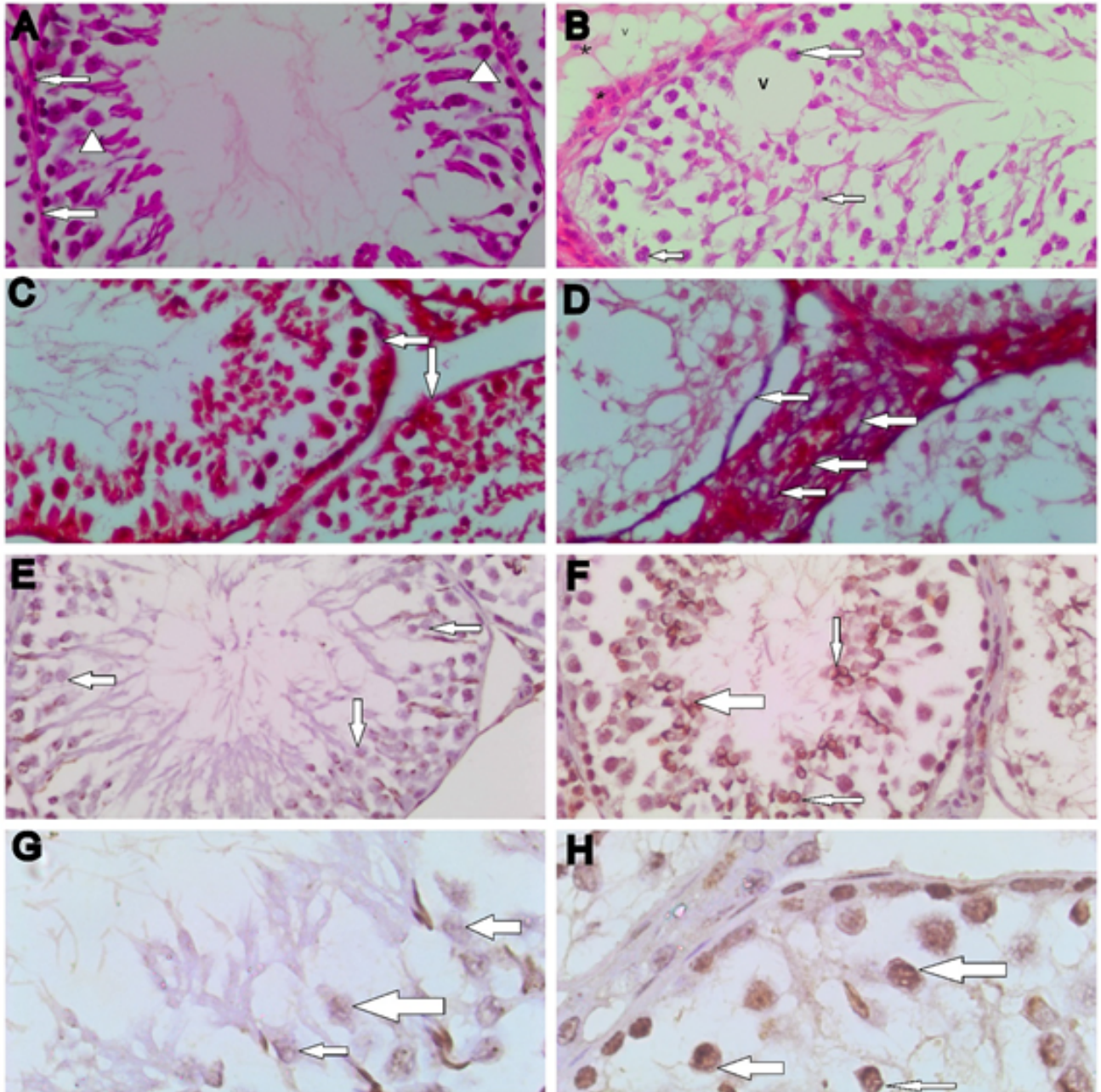


Fig. 2: **A):** Photomicrograph of control testicular tissue showing normal seminiferous tubule with regular basement membrane (arrows) and well organized spermatogenic cells (arrow heads); **B):** Metformin treated testicular tissue, showing disturbed organization of germinal epithelium, spermatogenic cells are separated from basement membrane with sign of degeneration (arrows), vacuoles (V), inter-tubular acidophilic exudate (**). (H&E X 100); **C):** Control testicular tissue showing delicate fibers of collagen surrounding the seminiferous tubules (arrows); **D):** Metformin treated testis with dense collagen fibers between STs and surrounding them (arrows). (Masson trichrome X 400); **E, G):** Control testis showing negative reaction for Bax in spermatogenic cells (arrows); **F, H):** Metformin treated testis showing positive reaction for Bax in spermatogenic cells (arrows); **E, F):** Bax immunoreactivity X400; **G,H):** Bax immunoreactivity X1000)

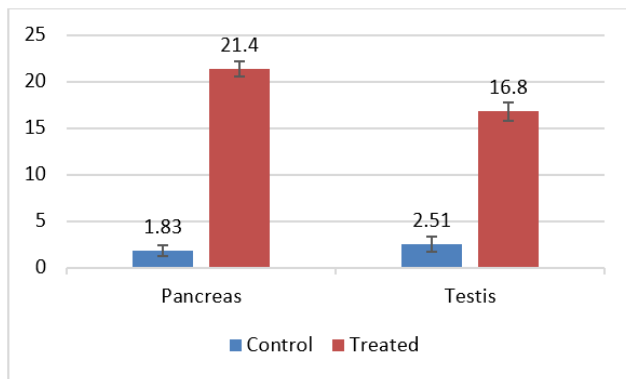


Chart 4: The mean area % of Bax immunostaining in treated pancreas and testis showing significant increase in comparison to control group (P value <.05)

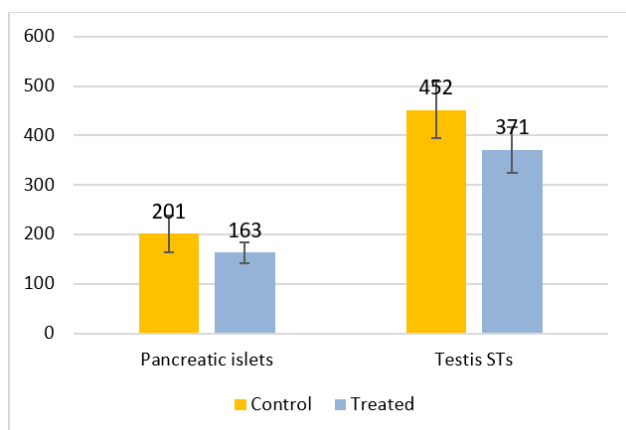


Chart 5: Significant reduction in pancreatic islets and seminiferous tubules diameters in treated group when compared to control group (P value <.05).

4. Discussion

This study aimed to clarify the effect of Metformin drug administration in a normo-glycemic condition on the pancreatic and testicular tissues. Metformin is a common drug used in treatment of type 2 diabetes.¹⁶ It can be also used in case of polycystic ovary as it affects the ovarian size.¹ Metformin demonstrated an anticancer activity in different types of malignancies.²⁻⁴

This study revealed that metformin caused no significant change in fasting blood sugar level between control and treated rats. However, it induced changes in pancreatic tissue of treated rats. The treated pancreatic tissue showed reduced islets' size with deeply stained degenerated cells. In contrast to this finding, it was reported that the fetal pancreatic tissue for metformin treated mother rats showed preserved structure of pancreatic islets with no signs of degeneration or inflammation.¹¹ However, this finding might be explained by different doses of metformin, they

used the drug in a dose of (36.43 mg/kg) which is much less than the dose used in this study.

In our study, there was significant increase in the serum lipase level in the treated group at the end of the experiment (200.8 ± 23.6 U/L in contrast to 43.7 ± 4.9 U/L at the beginning of the experiment). In parallel to our finding, it was reported that metformin induced pancreatitis in a patient with high serum lipase level was due to overdose administration of metformin.¹⁷ So, our finding could be due to high dose of metformin used in this study (400 mg/kg which is equivalent to 2000 mg human (the maximum allowed daily dose)).¹⁴ Another case of metformin induced pancreatitis was reported in a patient with acute renal failure.⁹ The changes in the treated pancreatic tissue and elevated lipase enzyme didn't cause significant change in the fasting blood glucose. This could be explained by the short duration of treatment that induced early stage of pancreatitis. In addition, metformin is known to induce cellular glucose uptake of and glycogen storage. This action is insulin independent, however it can't replace the hormone.¹⁸

Our finding after histological examination of testicular tissue in both groups revealed that in the treated rats the seminiferous tubules (STs) were irregular in outline, disturbed organization of germinal epithelium, spermatogenic cells were separated from basement membrane with sign of degeneration.

It is well known that androgen hormone is important in maintenance and maturation of spermatogenesis in testis.¹⁹ The target cells for the androgen hormone are the nuclei of Leydig, Sertoli and myoid cells in the testis.²⁰ It was also demonstrated that metformin reduced adrenal androgen production in treated mice,^{21,22} this might explain the effect of metformin on the spermatogenic cells in testis.

It is well known that metformin attenuates fibrosis by different mechanisms. One mechanism is through inhibition of connective tissue growth factor.²³ In contrast to this finding, our study revealed fibrosis surrounding pancreatic acini, islets and extensive fibrosis between STs and surrounding them with thickened blood vessels in the treated group. This finding could be explained by inflammation and degeneration in the pancreatic and testicular tissues that led to fibrosis. Similar result was reported in pancreatic fibrosis induced by inflammation of acinar cells in experimental rats received high fatty diet for a long duration.²⁴ One of the possible mechanisms for degeneration in metformin treated pancreatic and testicular tissues is the thickened blood which alter blood supply to tissues and cause degenerative changes.²⁵

According to our findings, Bax immunostaining showed intense reaction especially in the islets of Langerhans, exocrine pancreas and in the germinal cells in testis of the metformin treated group. In agreement with our result, it was reported that the pro-apoptotic proteins, Bax,

expression was induced in the ovarian cancer cells treated with metformin.²⁶ In addition, Bax and caspase-3 were significantly induced in the pituitary adenoma in mice treated with metformin in a dose of 5mM.²⁷ In contrast to those reports, it was documented that metformin reduced Bax expression in mononuclear cells only when used with irradiation, but when tested by its own, it showed no difference in Bax expression.²⁸ Another interesting report, that metformin reduced Bax expression in neuronal cells in case of Quinolinic Acid-Induced toxicity.²⁹ These finding were in parallel to the previous studies which reported that metformin reduced the ethanol-induced elevation of Bax expression in prenatal cortical neurons of rats.³⁰ So, the effect of metformin on the expression of Bax may be variable according to the associated pathology.

5. Conclusion

Our study revealed that metformin induced expression of Bax in pancreatic and testicular tissues of normal rats when used for one month, which will affect their viability and function. Its effect on Bax expression might be promising as a possible treatment in case of cancer, however, it should be used with caution.

6. Acknowledgments

Researcher wish to acknowledge the Department of Human Anatomy and Embryology, Faculty of Medicine, Mansoura University, for help and support to carry out this study.

7. Source of Funding

None.

8. Conflict of Interest

None.

References

- Bird ST, Hartzema AG, Etminan M, Brophy JM, Delaney JAC. Polycystic ovary syndrome and combined oral contraceptive use: a comparison of clinical practice in the United States to treatment guidelines. *Gynecol Endocrinol*. 2013;29(4):365–9.
- Xiong Y, Lu QJ, Zhao J. Metformin inhibits growth of hepatocellular carcinoma cells by inducing apoptosis via mitochondria-mediated pathway. *Asian Pac J Cancer Prev*. 2012;13:3275–9.
- Gao Z, Liu Z, Bi MH, Zhang JJ, Han ZQ, Han X, et al. Metformin induces apoptosis via a mitochondria-mediated pathway in human breast cancer cells in vitro. *Exp Ther Med*. 2016;11(5):1700–6.
- Park S, Lee D, Kim J. Metformin enhances TRAIL-induced apoptosis by Mcl-1 degradation via Mule in colorectal cancer cells. *Oncotarget*. 2016;7(37):59503–18.
- Kwan HT, Chan DW, Cai PC. AMPK activators suppress cervical cancer cell growth through inhibition of DVL3 mediated Wnt/beta-catenin signaling activity. *Public Library Sci*. 2013;8(1):53597.
- Kim NY, Lee HY, Lee C. Metformin targets Axl and Tyro3 receptor tyrosine kinases to inhibit cell proliferation and overcome chemoresistance in ovarian cancer cells. *Int J Oncol*. 2015;47(1):353–60.
- Scotland S, Saland E, Skuli N, de Toni F, Boutzen H, Micklow E, et al. Mitochondrial energetic and AKT status mediate metabolic effects and apoptosis of metformin in human leukemic cells. *Leukemia*. 2013;27(11):2129–38.
- Alsabaie S, Almalki MH. Metformin induced acute pancreatitis. *Dermato-Endocrinol*. 2013;5(2):317–8.
- Fimognari FL, Corsonello A, Pastorell R, Antonelli-Incalzi R. Metformin-Induced Pancreatitis: A possible adverse drug effect during acute renal failure. *Diabetes Care*. 2006;29(5):1183.
- Adaramoye O, Akanni O, Adesanoye O. Evaluation of toxic effects of metformin hydrochloride and glibenclamide on some organs of male rats. *Niger J Physiol Sci*. 2012;27:137–44.
- Lawal SK, Adeniji AA, Sulaiman S. Comparative effects of glibenclamide, metformin and insulin on fetal pancreatic histology and maternal blood glucose in pregnant streptozotocin-induced diabetic rats. *Afr Health Sci*. 2019;19(3):2491–2504.
- Mallik S. Metformin induced acute pancreatitis precipitated by renal failure. *Postgrad Med J*. 2004;80:239–40.
- Circu ML, Aw TY. Glutathione and modulation of cell apoptosis. *Biochim Biophys Acta*. 2012;1823(10):1767–77.
- Reagan-Shaw S, Nihal M, Ahmad N. Dose translation from animal to human studies revisited. *FASEB J*. 2008;22(3):659–61.
- Gokalp-Ozkorkmaz E, Asir F, Basaran SO, Agacayak E, Sahin F, Kaya S, et al. Examination of Bcl-2 and Bax Protein Levels for Determining the Apoptotic Changes in Placentas with Gestational Diabetes and Preeclampsia. *Proc*. 2018;2(25):1548.
- Wu MS, Johnston P, Sheu WH, Hollenbeck C, Jeng CY, Goldfine I, et al. Effect of Metformin on Carbohydrate and Lipoprotein Metabolism in NIDDM Patients. *Diabetes Care*. 1990;13(1):1–8.
- Ben MH, Thabet H, Zaghdoudi I. Metformin associated acute pancreatitis. *Vet Hum Toxicol*. 2002;44:47–8.
- Wiernsperger NF, Bailey CJ. The Antihyperglycaemic Effect of Metformin. *Drugs*. 1999;58(Supplement 1):31–9.
- Tartarin P, Moison D, Guibert E, Dupont J, Habert R, Rouiller-fabre V, et al. Metformin exposure affects human and mouse fetal testicular cells. *Human Reprod*. 2012;27(11):3304–14.
- Wang RS, Yeh S, Tzeng CR, Chang C. Androgen Receptor Roles in Spermatogenesis and Fertility: Lessons from Testicular Cell-Specific Androgen Receptor Knockout Mice. *Endocr Rev*. 2009;30(2):119–32.
- Timurkaan N, Yilmaz F, Timurkaan S. Effects of Cottonseed Flour on Immunohistochemical Localization of Androgen Receptors (AR) in Rat Testes. *Revue de Med Veterinaire*. 2011;162:13–17.
- Hirsch A, Hahn D, Kempná P, Hofer G, Nuoffer JM, Mullis PE, et al. Metformin Inhibits Human Androgen Production by Regulating Steroidogenic Enzymes HSD3B2 and CYP17A1 and Complex I Activity of the Respiratory Chain. *Endocrinol*. 2012;153:4354–66.
- Attia GM, Elmansy RA, Elsayed MH. Metformin Decreases the Expression of VEGF-A and CTGF-1 and Improves Histological, Ultrastructural and Hormonal Changes in Adult Rat Polycystic Ovary. *Folia Biologica (Kraków)*. 2019;67:1.
- Ye T, Chen YH, Gao JH. Effect of octreotide on pancreatic fibrosis in rats with high-fat diet-induced obesity. *Int J Clin Exp Pathol*. 2018;11(10):4784–94.
- Pushparaj P, Tan CH, Tan BKH. Effects of Averrhoa bilimbi leaf extract on blood glucose and lipids in streptozotocin-diabetic rats. *J Ethnopharmacol*. 2000;72(1-2):69–76.
- Patel S, Singh N, Kumar L. Evaluation of Effects of Metformin in Primary Ovarian Cancer Cells. *Asian Pac J Cancer Prev*. 2015;16:6973–9.
- An J, Pei X, Zang Z. Metformin inhibits proliferation and growth hormone secretion of GH3 pituitary adenoma cells. *Oncotarget*. 2017;8(23):37538–49.
- Kolivand S, Motevaseli E, Cheki M, Mahmoudzadeh A, Shirazi A, Fait V. The Anti-apoptotic Mechanism of Metformin Against Apoptosis Induced by Ionizing Radiation in Human Peripheral Blood Mononuclear Cells. *Klin Onkol*. 2017;30(5):372–9.

29. Park S, Jang S. Antidiabetic Drug Metformin Protects Neuronal Cells against Quinolinic Acid-Induced Excitotoxicity by Decreasing Intracellular Calcium. *Chonnam Med J.* 2018;54:24–30.
30. Ullah I, Ullah N, Naseer MI, Lee HY, Kim MO. Neuroprotection with metformin and thymoquinone against ethanol-induced apoptotic neurodegeneration in prenatal rat cortical neurons. *BMC Neurosci.* 2012;13(1):11.

Author biography

Hagar A Hashish Associate Professor

Cite this article: Hashish HA. Effect of metformin on Bax expression in pancreas and testis of normoglycemic albino rat: An immunohistochemical study. *Indian J Clin Anat Physiol* 2020;7(2):134-141.