



Original Research Article

Radio anatomical analysis of positional relation between anterior ethmoid artery canal and ethmoid skull base in correlation with olfactory fossa

N Vinay Kumar¹, T S Gugapriya^{2,*}¹Dept. of Anatomy, Government Medical College, Palakkad, Kerala, India²Dept. of Anatomy, All India Institute of Medical Sciences, Nagpur, Maharashtra, India

ARTICLE INFO

Article history:

Received 06-02-2020

Accepted 17-02-2020

Available online 14-03-2020

Keywords:

Anterior ethmoid artery

Skull base

Lateral lamella

Olfactory fossa

Keros

ABSTRACT

Introduction: Skull base (SB) injuries happens mostly either in the thinnest or the least resistant part of skull base. The lateral lamella of cribriform plate is one of the common sites of injury during endoscopic anterior skull base surgeries. The anterior ethmoid artery (AEA) visualization is considered as a significant anatomical landmark in such surgeries. Studies correlating their positional relation with morphology of olfactory fossa remains limited. This study aims to look into the relation of AEA to that of SB in different types of olfactory fossa morphology.

Materials and Methods: A retrospective radiological study was done on 100 coronal CT images from patients who were subjected to paranasal CT imaging. In bone window of coronal CT scans, the position of AEA in relation to SB was noted and the vertical distance between them was measured. Based on the distance of AEA from SB, 3 groups were subdivided as follows: Group A - < 2.5 mm, Group B - 2.5 to 5 mm and Group C - > 5 mm. The depth of the olfactory fossa was measured and categorized according to Keros classification.

Results: Out of 200 sides, AEA was found below SB in 167 out of 200 (83.5%) with majority belonging to Group A (101 out of 167). Keros type II was commonly observed among all the groups. The position of AEA below SB was seen at a greater frequency as the height of SB increased with the Keros classification and was statistically significant ($P = .006$)

Conclusion: The knowledge of presence of anterior ethmoid artery outside the skull base with long lateral lamella preoperatively would help the surgeon to avoid intraoperative complications during endoscopic skull base or sinus surgeries.

© 2020 Published by Innovative Publication. This is an open access article under the CC BY-NC-ND license (<https://creativecommons.org/licenses/by/4.0/>)

1. Introduction

Skull base (SB) injuries happens mostly either in the thinnest or the least resistant part of SB.¹ The region of thin and less resistant lateral lamella of cribriform plate had been proposed as the common site of injury during endoscopic anterior skull base surgeries.²⁻⁴ During functional endoscopic sinus surgery involving the anterior skull base, the anterior ethmoid artery (AEA) visualization is considered as a significant anatomical landmark.⁵⁻⁸

AEA originates in the anterior third of orbital cavity from ophthalmic artery and courses through the medial orbital

wall by entering the anterior ethmoid foramen. It further passes through ethmoid sinus either freely or within a bony canal and exits commonly by penetrating the lateral lamella of cribriform plate.^{9,10} Inconsistent course of AEA coupled with thin lateral lamella of cribriform plate was noted to result in complications like leakage of CSF, intra orbital retraction of artery and orbital hematoma with bleeding during endoscopic surgeries due to unwarranted injury.¹¹⁻²⁰

A study had shown that visualizing AEA during endoscopic surgeries specifically prevents iatrogenic complications associated with such endoscopic procedures.²¹ AEA remains as the critical structure of identification in upper skull base procedures and also in accessing frontal

* Corresponding author.

E-mail address: guga.tarun@gmail.com (T. S. Gugapriya).

sinus.¹³

Positional relation of AEA to SB particularly in low ethmoid roof had been reported.^{1,18,22} Studies have found a directly proportional relation between AEA and SB distance.^{23,24} However, studies correlating this positional relation with morphology of olfactory fossa remains limited. This study aims to look into the relation of AEA to that of ethmoid skull base in different types of olfactory fossa morphology.

2. Materials and Methods

A retrospective radiological study was done on 100 coronal CT images from patients who were subjected to paranasal CT imaging during a period April-July 2018 in a tertiary health care setup. All CT images, even with evidence of sinusitis were included in the study. The exclusion being altered skull base anatomy due to previous surgical intervention, trauma or tumour and age less than 18 years. The images were analysed using RadiAnt Dicom viewer. In bone window of coronal CT scans, the position of AEA in relation to SB was noted. It was classified as at SB or below SB on each side. The vertical distance from AEA to SB was measured individually if the AEA was found to be below SB. Based on the distance of AEA from SB, 3 groups were subdivided as follows: Group A - < 2.5 mm, Group B - 2.5 to 5 mm and Group C - > 5 mm (Figure 1).

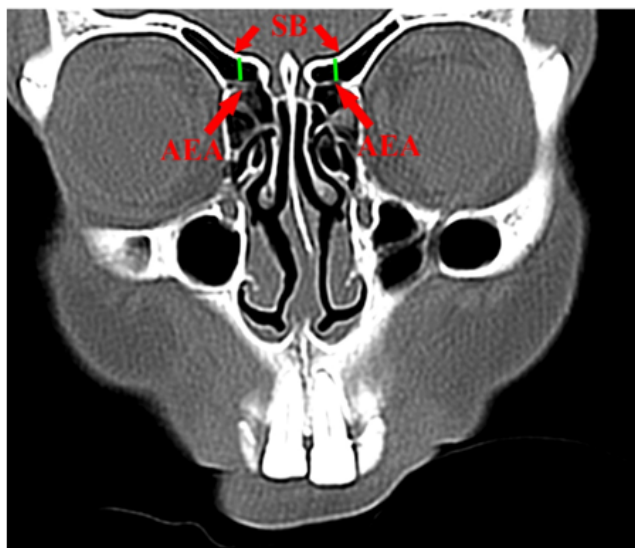


Fig. 1: Showing AEA, SB. Greenline- indicates the vertical distance between AEA and SB

The depth of the olfactory fossa was measured with reference to length of the lateral lamella of cribriform plate and categorized according to Keros classification as Keros type I – 1 to 3 mm, type II – 4 to 7 mm and type – III – 8 to 16 mm (Figure 2).²⁵

The data were statistically analysed using SPSS software. The chi-square test was applied to relate the distance between AEA and SB and the depth of olfactory fossa. P value of < 0.05 was defined as statistically significant. The study was undertaken after approval from institutional ethical committee.

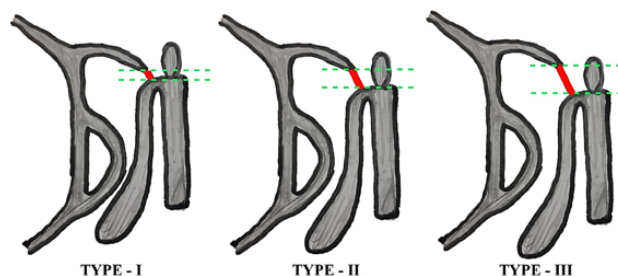


Fig. 2: Showing Keros classification of olfactory fossa. Red line is the lateral lamella

3. Results

Among the coronal CT images analyzed, the male and female were noted to be 67 and 33 respectively.

Out of 200 sides, AEA was identified in all the images studied (100%). The AEA was found below SB in 167 out of 200 (83.5%). On measuring the distance between the AEA and SB majority belonged to Group A (101 out of 167) (Figure 3) in comparison to Group B (56 out of 167) (Figure 4) and Group C (10 out of 167) (Figure 5). The mean distance was found to be 1.43 mm, 3.8 mm, 5.72 mm in Group A, Group B and Group C respectively. The overall mean distance between the AEA and the SB was 3.65 mm.

CT images showing AEA below the SB was observed commonly to have type II Keros classification. The unobserved type was Keros type III in this study (Table 1). AEA was observed at the SB (Figure 6) in 33 out of 200 sides (16.5%). In this group also kero's type III was noted to be absent (Table 1).

On applying Chi-square test for comparing the position of AEA and Keros classification, the P value was significant ($P = .006$) (Table 1). The position of AEA below SB was seen at a greater frequency as the height of SB increased with the Keros classification (Table 1).

On comparing the relational distance between AEA and SB and the depth of olfactory fossa (Table 2), data revealed that Keros type II was the most frequent type present among all the groups. Chi-square test was applied to see the correlation between the groups and the P value calculated was > 0.05. This indicated a statistically insignificant relation between the groups.

Table 1: Distribution of Keros classification with AEA below and at SB

	AEA below SB	AEA at SB (Figure 6)
Keros Type I	63 (70.14) [0.73]	21 (13.86) [3.68]
Keros Type II	104 (96.86) [0.53]	12 (19.14) [2.66]
Keros Type III	0	0

The chi-square statistic is 7.5948. The p-value is .005854. The result is significant at $p < .05$

Table 2: Relation between AEA to SB distance and Keros classification (olfactory fossa depth)

	Keros type I	Keros Type II	Keros Type III	Total
Group A	38 (38.10) [0.00]	63 (62.90) [0.00]	0	101
Group B	23 (21.13) [0.17]	33 (34.87) [0.10]	0	56
Group C	2 (3.77) [0.83]	8 (6.23) [0.50]	0	10
Total	63	104	0	167

The chi-square statistic is 1.6047. The p-value is .448277. The result is not significant at $p < .05$.

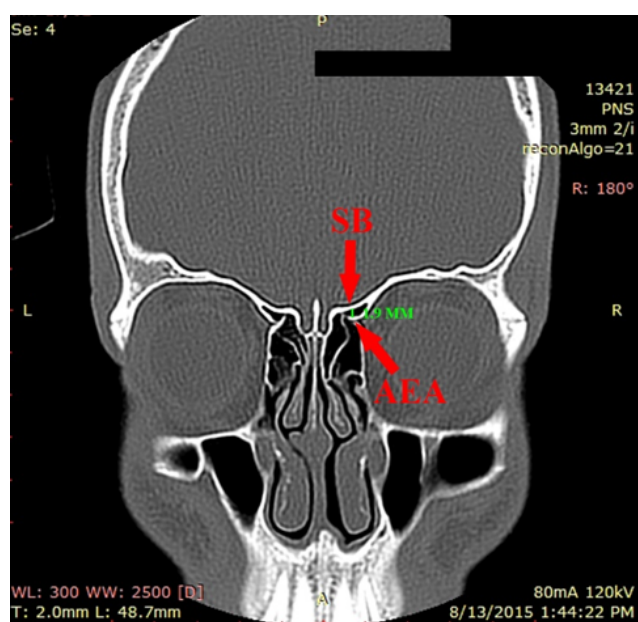


Fig. 3: Showing AEA belonging to Group A

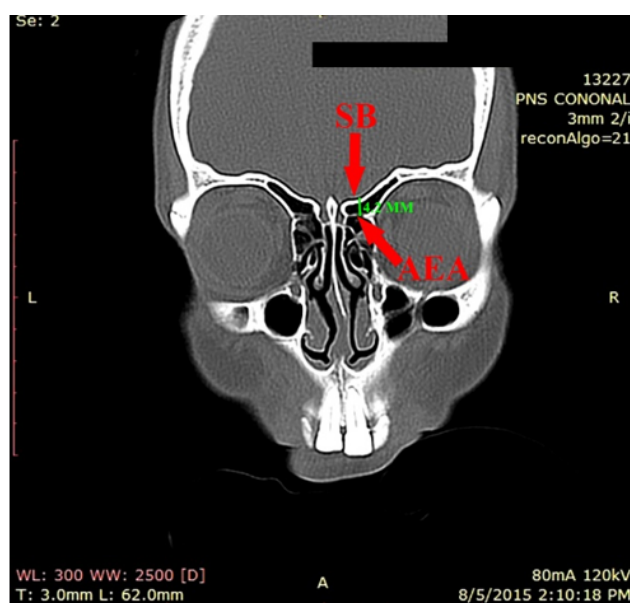


Fig. 4: Showing AEA belonging to Group B

4. Discussion

The AEA is an anato-radiologic keystone for endoscopic surgeries on paranasal sinuses and anterior skull base surgeries. Observation of AEA in all the images analysed in the present study stands out in agreement to reported range between 92-100%.^{9,10,13,17}

AEA was known to exhibit a variable course in the ethmoidal air sinus. It was noted at SB in 16.5% and below SB in 83.5% which correlates with earlier studies showing 20% and 80%, 32.7% and 67.3% respectively.^{14,15} The comparison of distance between AEA and SB among different authors shows that group A is seen commonly except in one study where group C was observed to be predominant (Chart 1).^{5,14,15,20} The overall mean distance between the AEA and SB was 3.65 mm which is comparable

to the mean value of 3.18 mm and 4.86 mm reported in previous studies.^{14,23}

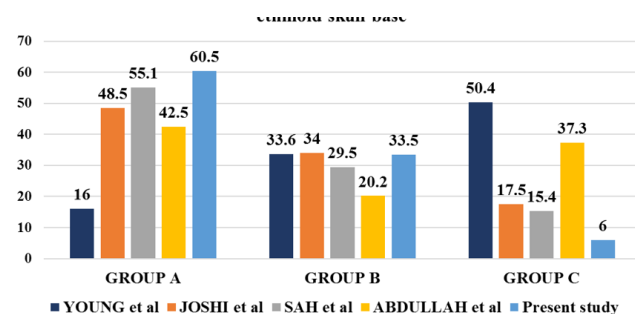


Chart 1: Showing comparison of distance between AEA and ethmoid skull base

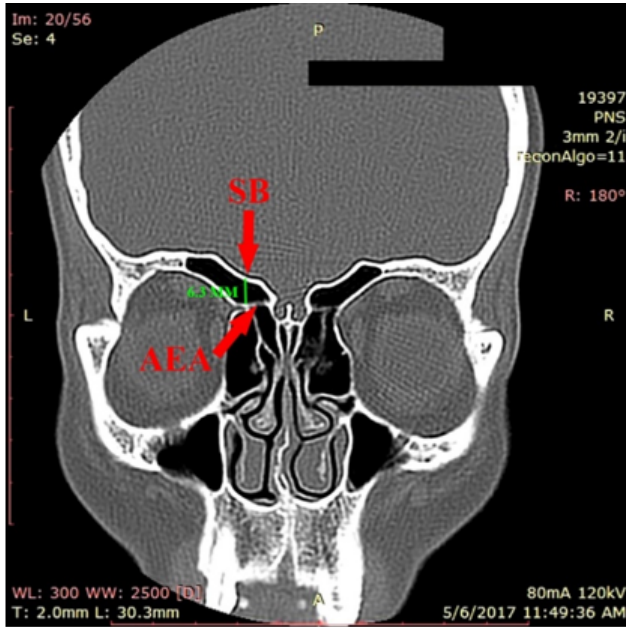


Fig. 5: Showing AEA belonging to Group C

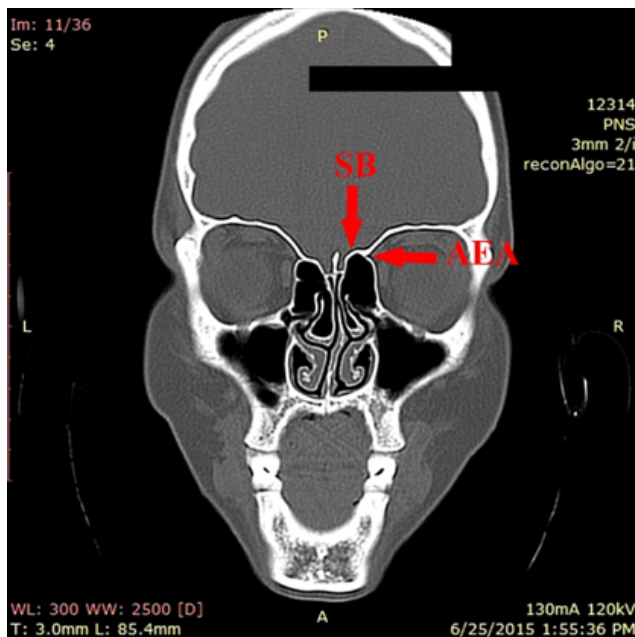
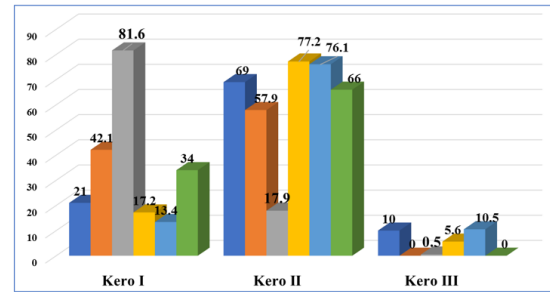


Fig. 6: Showing AEA at SB

The depth of olfactory fossa is an important guiding landmark for endoscopic surgeons. Except a study that showed kero's type I as the predominant type, rest all previous reports including the present study observed Kero's type II in predominance (Chart 2).^{20,23,26–28}

Increased depth of olfactory fossa increases the probability of AEA coursing freely within ethmoid sinus.^{9,10} AEA canal distance from SB increases in a definitive manner with an increase in the depth of olfactory fossa. The probability



■ Poteet et al ■ Abdullah et al ■ Justin elfred et al ■ Nair et al ■ Kaplanoglu et al ■ present study

Chart 2: Showing comparison of percentage incidence of olfactory fossa depth (Keros classification)

of iatrogenic injury to AEA increases in such cases. In the contrary, present finding of majority of the AEA coursing very close to the skull base < 2.5 mm indicates a safer course and less chance of injury during interventions.

Apart from the relation to lateral lamellar height that could change the position of AEA, the pneumatization of ethmoid air cells and presence of large supraorbital cell has been attributed as reason for variability in the position of AEA with relation to SB. Kero's type along with ethmoid pneumatization was proposed as predictive factor in determining the relational distance between AEA and SB.^{10,13,14,29} Study of this causative relation was beyond the scope of the present study.

5. Limitation

1. Limited sample size might be the reason for less statistical power seen in the analysis.
2. The incidence of supraorbital pneumatization, supra-orbital cell and their relation to positional variation of AEA.

6. Conclusion

The distance between AEA and SB differs due to difference in length of lateral lamella of cribriform fossa. Variation in olfactory fossa morphology does exist. The positional relationship between AEA and depth of olfactory fossa stands significant in spite of statistical limitation observed. The knowledge of presence of anterior ethmoid artery outside the skull base with long lateral lamella preoperatively would help the surgeon to avoid intraoperative complications during endoscopic skull base or sinus surgeries.

7. Conflict of Interest

None.

8. Source of Funding

None.

References

- Kainz J, Stammberger H. The Roof of the Anterior Ethmoid: A Place of Least Resistance in the Skull Base. *Laryngol Rhinol Otol (Stuttg)*. 1988;67:142–149.
- Kainz J, Stammberger H. The Roof of the Anterior Ethmoid: A Place of Least Resistance in the Skull Base. *Am J Rhinol*. 1989;3(4):191–199.
- Stammberger H. Complications of Inflammatory Sinus Diseases Including Iatrogenic Complications. *Eur Arch Otorhinolaryngol-Rhino-Laryngol*. 1993;p. 62–102.
- Ohnishi T, Yanagisawa E. Lateral Lamella of the Cribriform Plate—An Important High-Risk Area in Endoscopic Sinus Surgery. *Ear Nose Throat J*. 1995;74(10):688–690.
- Ko YB, Kim MG, Jung YG. The anatomical relationship between the anterior ethmoid artery, frontal sinus, and intervening air cells; can the artery be useful landmark. *Korean J Otorhinolaryngol-Head Neck Surg*. 2014;57(10):687–691.
- Lee WC, Ku PKM, van Hasselt CA. New Guidelines for Endoscopic Localization of the Anterior Ethmoidal Artery: A Cadaveric Study. *The Laryngoscope*. 2000;110(7):1173–1178.
- Akdemir G, Tekdemir I, Altın L. Transethmoidal approach to the optic canal: Surgical and radiological microanatomy. *Surg Neurol*. 2004;62(3):268–274.
- Bayram M, Sirikci A, Bayazit YA. Important anatomic variations of the sinonasal anatomy in light of endoscopic surgery: a pictorial review. *European Radiol*. 2001;11(10):1991–1997.
- Kirchner JA, Yanagisawa E, Crelin ES. Surgical Anatomy of the Ethmoidal Arteries: A Laboratory Study of 150 Orbits. *Arch Otolaryngol*. 1961;74(4):382–386.
- Chung SK, Dhong HJ, Kim HY. Computed tomography anatomy of the anterior ethmoid canal. *Am J Rhinol*. 2001;15(2):77–81.
- Stammberger H. Endoscopic anatomy of lateral wall and ethmoidal sinuses. In: H S, M H, editors. Essentials of functional endoscopic sinus surgery. Mosby-Year Book ; 1993., p. 13–42.
- Ohnishi T, Yanagisawa E. Lateral Lamella of the Cribriform Plate—An Important High-Risk Area in Endoscopic Sinus Surgery. *Ear Nose Throat J*. 1995;74(10):688–690.
- Souza SA, de Souza MMA, Gregório LC, Ajzen S. Anterior Ethmoidal Artery Evaluation on Coronal CT Scans. *Braz J Otorhinolaryngol*. 2009;75(1):101–106.
- Joshi AA, Shah KD, Bradoo RA. Radiological correlation between the anterior ethmoidal artery and the supraorbital ethmoid cell. *Indian J Otolaryngol*. 2010;62(3):299–303.
- Sah BP. Radiological correlation between the anterior ethmoidal artery and the supraorbital ethmoid cell in relation to skull base. *A Ad Med Sc*. 2018;2:11–15.
- Seker A, Martins C, Rhoton AL. Meningeal anatomy. In: Meningiomas. vol. 1 ; 2010., p. 11–51.
- Amarnath SB, Kumar PS. Study of variants of anterior ethmoidal artery on computed tomography of paranasal sinuses. *Int J Otorhinolaryngol Head Neck Surg*. 2018;5(1):19–23.
- Moon HJ, Kim HU, Lee JG. Surgical anatomy of the anterior ethmoidal canal in ethmoid roof. *Laryngoscope*. 2001;111(5):900–904.
- Cankal F, Apaydin N, Acar HI, Elhan A, Tekdemir I, et al. Evaluation of the anterior and posterior ethmoidal canal by computed tomography. *Clin Radiol*. 2004;59(11):1034–1040.
- Abdullah B. Anatomical variations of anterior ethmoidal artery at the ethmoidal roof and anterior skull base in Asians. *Surg Radiol Anat*. 2018;1:1–8.
- Ohnishi T, Tachibana T, Kaneko Y, Esaki S. High-Risk Areas in Endoscopic Sinus Surgery and Prevention of Complications. *Laryngoscope*. 1993;103(10):1181–1185.
- Becker SP. Applied Anatomy of the Paranasal Sinuses with Emphasis on Endoscopic Surgery. *Ann Otol Rhinol Laryngol Suppl*. 1994;103(4_suppl):3–32.
- Poteet PS, Cox MD, Wang RA, Fitzgerald RT, Kanaan A. Analysis of the Relationship between the Location of the Anterior Ethmoid Artery and Keros Classification. *Otolaryngol Head Neck Surg*. 2017;157:320–324.
- Yenigun A. A study of the anterior ethmoidal artery and a new classification of the ethmoid roof (Yenigun classification). *Eur Arch Otorhinolaryngol*. 2016;273(11):3759–3764.
- Keros P. On the practical value of differences in the level of the lamina cribrosa of the ethmoid. *Z Laryngol Rhinol Otol*. 1962;41:809–813.
- Paber JELB, Cabato MSD, Villarta RL, Hernandez JG. Radiographic Analysis of the Ethmoid Roof based on KEROS Classification among Filipinos. *Phil J Otolaryngol Head Neck Surg*. 2008;23(1):15–19.
- Nair S. Importance of ethmoidal roof in endoscopic sinus surgery. *Sci Rep*. 2012;1(4):1–3.
- Kaplanoglu H, Kaplanoglu V, Dilli A, Toprak U, Hekimoglu B. An Analysis of the Anatomic Variations of the Paranasal Sinuses and Ethmoid Roof Using Computed Tomography. *Eurasian J Med*. 2013;45(2):115–125.
- Simmen D. The surgeons view of the anterior ethmoid artery. *Clin Otolaryngol*. 2006;31(3):187–191.

Author biography

N Vinay Kumar Associate Professor

T S Gugapriya Professor

Cite this article: Kumar NV, Gugapriya TS. Radio anatomical analysis of positional relation between anterior ethmoid artery canal and ethmoid skull base in correlation with olfactory fossa. *Indian J Clin Anat Physiol* 2020;7(1):51-55.