



Original Research Article

The study of lateral circumflex femoral artery and its applied aspects

Sowmya S¹, Kavya^{1*}, Sharmada K L¹, Meenakshi Parthasarathy¹Dept. of Anatomy, Bowring and Lady Curzon Medical College and Research Institute, Bangalore, Karnataka, India

ARTICLE INFO

Article history:

Received 30-11-2019

Accepted 10-12-2019

Available online 31-12-2019

Keywords:

Lateral circumflex femoral artery

Profunda femoris artery

Femoral artery

Femoral nerve

ABSTRACT

Introduction: The anatomy of arterial variational pattern of lower limb are utmost important for catheterization, reconstructive procedures and surgical intervention for embolism. LCFA is used as a long vascular pedicle in anterolateral perforator thigh flap and in breast reconstruction after mastectomy. Ignorance of variations can lead to fatal intraoperative haemorrhage and incapacitating sensory and motor deficit due to injury to femoral nerve branches which are closely related to these vessels¹.

Aims and Objective: The study aims at the origin of LCFA and its origin from main arterial origin; 1: Origin of LCFA is it from PFA or FA; 2: Distance of origin from PFA those which are branches of PFA & FA respectively.

Materials and Methods: The present study was conducted in 50 formalin-fixed lower limbs from the Department of Anatomy, Bangalore Medical College and Research Institute and Bowring & Lady Curzon Medical College & Research Institute, Bangalore. Dissection of PFA and its branches were carried out & the following parameters were observed and photographed. Percentage of origin of LCFA from PFA / FA. Distance of origin of LCFA from PFA/FA. Measurements were done using digital callipers.

Result: Origin of LCFA was from PFA in 46 cases (92%) & FA in 4 (8%). The mean distance of origin of LCFA was 2.3 cm (range 0.3-7 cm). 1: 38 (82.6%) were 0.3-2.8 cm from PF & 8 (17.4%) were 2.9-5.8 cm from PF; 2: (50%) were 0.3-3 cm from FA & 2 (50%) were 3.1-7 cm from FA.

© 2019 Published by Innovative Publication. This is an open access article under the CC BY-NC-ND license (<https://creativecommons.org/licenses/by/4.0/>)

1. Introduction

The lateral circumflex femoral artery (LCFA) is an important artery of the lower limb. The LCFA is a laterally running branch given off near the root of Profunda Femoris (PFA) which is the largest branch of Femoral artery (FA). The artery takes part in trochanteric anastomosis, cruciate anastomosis and the anastomosis around the knee joint respectively. It passes between branches of femoral nerve, posterior to sartorius and rectus femoris and divides into ascending, transverse and descending branches.¹ The study in branching pattern of these main vessels of lower limb can help the operating surgeons reduce the chances of intra operative injury to involving these vessels.²

2. Materials and Methods

The present study was conducted in 46 dissected specimens of lower limb of unknown age and sex for a period of 6 months. The branching pattern of the FA, PF and LCFA was observed in detail and noted.

3. Results

In present study the LCFA originated from PF in 46 specimens (92%) (Figure 1) and from FA in 4 cases (8%) (Figure 2). When LCFA branched from the deep FA, the mean distance was 1.5 cm from the origin of deep FA (Siddharth). In the present study, the mean distance of origin of LCFA was 2.3 cm (range 0.3-7 cm) (Table 1).

* Corresponding author.

E-mail address: kavs.084@yahoo.co.in (Kavya).

1. 38 (82.6%) were 0.3-2.8 cm from PF & 8 (17.4%) were 2.9-5.8 cm from PF.

2. 2 (50%) were 0.3-3 cm from FA & 2 (50%) were 3.1-7 cm from FA.

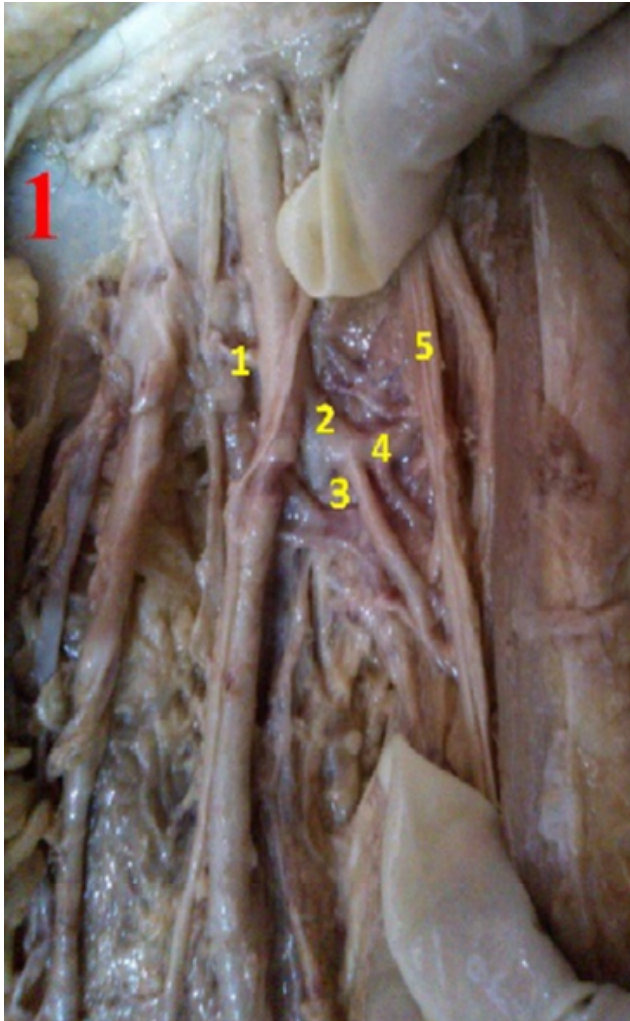


Fig. 1: Showing normal origin of LCFA (4) From PFA

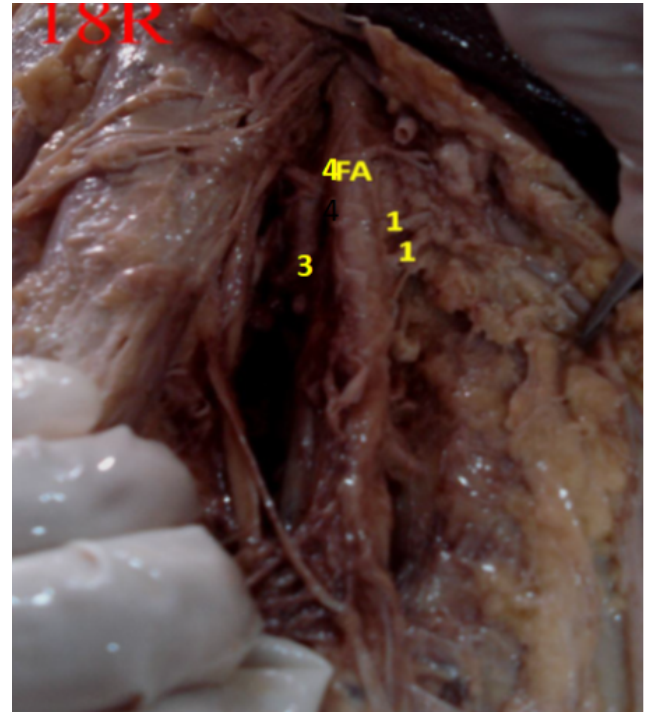


Fig. 2: Showing origin of LCFA (4) from FA

Table 1: Showing the comparison of distance of origin from FA and PFA

Authors	Origin of LCFA from PF (%)	Origin of LCFA from FA (%)
Uzel et al	77.3	22.7
Dixith et al	83.34	16.66
Choi et al	86.8	13.2
Sinkeet et al	65.5	34.5
Prakash et al	81.25	18.75
Present study	92	8

4. Discussion

Lateral Circumflex Femoral Artery may arise from FA,² Sometimes the LCFA fairly rises from FA above the PFA.³

According to a study among 200 limbs LCFA originated from PFA in 123 limbs and in 26 limbs LCFA from FA.⁴

A case of bilateral variation in the origin of LCFA, on the right side it arose from FA, proximal to the origin of PF. In addition, another lateral branch was seen arising from PF making it double LCFA on the right side. On the left side, LCFA was seen arising from FA at the level of PF.⁵ LCFA in 52 (81.25%) extremities originated from PF; whereas in 12 (18.75%) extremities it originated from FA.⁶

The origins of LCFA in 110 inguinal regions of 56 cadavers between 1997 and 2007. The LCFA was found to be branched from the deep FA in 85 (77.3%) cases and from FA in 21 (19.1%) cases. In two (1.8%) cases the ascending and the descending branches of LCFA branched separately from deep FA and FA. There was a common trunk of deep FA and LCFA in one (0.9%) case, and a common trunk of deep FA, LCFA and MCFA (trifurcation) in another (0.9%). They also measured the distance between MIP and origin of LCFA. For LCFAs branching from deep FA the mean distance between these points was 4.8 +/- 1.2 cm, while for LCFAs branching from FA the mean distance was 3.4 +/- 0.9 cm.⁷

The small branches of FA in the femoral triangle were not palpable and could increase the risk of intravascular injection during femoral nerve block. The author evaluated the position of LCFA system and the perforators nourishing the anterolateral thigh flap. They found regularly most musculocutaneous perforators mainly in the central third of thigh arising from the descending branch of LCFA.⁸

Variant origin of LCFA is important during harvesting of anterolateral thigh flaps, aorto-popliteal by-pass, coronary artery grafting, and vascularised iliac transplant. They studied the artery in 84 lower limbs and they observed that it was a branch of PF in only 65.5% of cases. Variant origins included from a common trunk with MCFA (14.3%), with PF (10.7%), as a trifurcation with PF and MCFA (7.1%), and from FA (2.4%). Variant origin of LCFA occurred in nearly 35% of the Kenyan population studied, much lower than in oriental populations. The most frequent variant origin is as a common trunk with MCFA and PF, with a very low prevalence of origin from FA.⁹

5. Conclusion

The anatomical knowledge of LCFA helps in catheterization, reconstructive procedures and surgical intervention of the thigh and hip region. Anatomical variation of distance of origin and from main arterial trunk may lead to severe haemorrhage and may misguide during surgical intervention. Anatomical knowledge of LCFA is used as a long vascular pedicle in anterolateral perforator thigh flap and in breast reconstruction after mastectomy.

6. Source of funding

None.

7. Conflict of interest

None.

References

1. Standring S. Pelvic Girdle, Gluteal region and Thigh. Grays Anatomy. 40th ed. New York: Elsevier Churchill Livingstone ; 2008,.

2. Shivi G. Unusual disposition of lateral circumflex femoral artery: Anatomical description and clinical implications. *World J Clin Cases*. 2015;3(1):85–88.
3. Hollinshead WH. Anatomy for surgeons. vol. 3. Philadelphia: Hoeber-Harper International ; 1966,.
4. Bergman RA, Afifi AK, Miyauchi R. Origin of deep group and circumflex group of arteries, cardiovascular system, Illustrated Encyclopedia of Human Anatomic Variation ;.
5. Balachandra N, Prakash BS, Padmalatha K, Ramesh BR. Variation in the origin of the Lateral circumflex femoral artery - A Case Report. *Anatomica Karnataka*. 2011;5(1):76–80.
6. Prakash, Jyothi K. Variations in the origins of the Profunda Femoris, medial and lateral circumflex arteries: a cadaver study in the Indian population. *Rom J Morphol Embryol*. 2010;51(1):206–209.
7. M U, Tanyeli E, Yildirim M. An anatomical study of the origins of the lateral circumflex femoral artery in the Turkish population. *Folia Morphol*. 2008;67(4):226–230.
8. Steven L, Orebaugh SL. The femoral nerve and its relationship to the lateral circumflex femoral artery. *Anesth Analg*. 2006;102(6):1859–1862.
9. Sinkeet SR, Ogen'o JA, Elbusaidy H, Olabu BO, Irungu MW. Variant origin of the lateral circumflex femoral artery in a black Kenyan population. *Folia Morphol*. 2012,.

Author biography

Sowmya S Associate Professor

Kavya Assistant Professor

Sharmada K L Tutor

Meenakshi Parthasarathy Professor and Head

Cite this article: Sowmya S , Kavya , Sharmada K L , Parthasarathy M. The study of lateral circumflex femoral artery and its applied aspects. *Indian J Clin Anat Physiol* 2019;6(4):468-470.