

Content available at: <https://www.ipinnovative.com/open-access-journals>

Indian Journal of Clinical Anatomy and Physiology

Journal homepage: <https://www.ijcap.org/>

Original Research Article

A study of variations in branching pattern of axillary artery in cadavers

Anjalee G Ovhal^{1,*}, K Ravikumar¹, Devender Sachdev²¹Dept. of Anatomy, Late Baliram Kashyap Memorial Government Medical College, Jagdalpur, Chhattisgarh, India²Dept. of Pharmacology, Tomo Riba Institute of Health and Medical Sciences, Arunachal Pradesh, India

ARTICLE INFO

Article history:

Received 16-11-2021

Accepted 27-11-2021

Available online 07-12-2021

Keywords:

Axillary artery

Branching pattern

Cadavers

Upper limbs

ABSTRACT

Background: The knowledge of variable branching pattern of Axillary artery is needed for vascular surgeons, onco surgeons, anaesthesiologists, orthopedic surgeons and radiologists due to increased use of invasive diagnostic, interventional procedures.**Aims and Objectives:** The aim was to study the variable branching pattern of Axillary artery in cadavers.**Materials and Methods:** 15 cadavers (30 upper limbs) - 12 male and 3 female embalmed with 10% formalin were dissected for this study.**Results:** Variable branching pattern was observed in 6.6% of the cases on right side and 6.6% of the cases on left side in first part of axillary artery, 40% of the cases on right side and 53.3% of the cases on left side in second part and 53.3% of the cases on right side and 26.6% of the cases on left side in third part.**Conclusions:** The anatomical knowledge of the normal and variant anatomy of the Axillary artery is of importance for anatomists, surgeons, radiologists and clinicians during various interventional, diagnostic, therapeutic and surgical procedures on pectoral and axillary regions.This is an Open Access (OA) journal, and articles are distributed under the terms of the [Creative Commons Attribution-NonCommercial-ShareAlike 4.0 License](#), which allows others to remix, tweak, and build upon the work non-commercially, as long as appropriate credit is given and the new creations are licensed under the identical terms.For reprints contact: reprint@ipinnovative.com

1. Introduction

The Axillary artery is a continuation of the subclavian artery from outer border of the first rib to lower border of teres major muscle. It is classically divided into three parts by the pectoralis minor muscle. It is conventionally described as giving of six branches. The branches vary considerably.¹

The number of branches that arose from the Axillary artery showed considerable variations: two or more of usual branches may arise by a common trunk or named artery viz. deltoid, acromial, clavicular or pectoral branch may arise directly from Axillary artery.²

Axillary artery has the second highest rate of puncture and damage in traumatic injuries, surgeries, clinical and imaging procedures after the popliteal artery. The knowledge of variable branching pattern of Axillary

artery is important for vascular surgeons, onco surgeons, anaesthesiologists, orthopedic surgeons and radiologists due to increased use of invasive diagnostic, interventional procedures. The aim of the present study was to contribute to the existing knowledge of the variations in the branching pattern of the Axillary artery, explaining its embryological basis and also its morphological and clinical significance. 15 cadavers (30 upper limbs) - 12 male and 3 female embalmed with 10% formalin were dissected for this study. Variable branching pattern was observed in 6.6% of the cases on right side and 6.6% of the cases on left side in first part of axillary artery, 40% of the cases on right side and 53.3% of the cases on left side in second part and 53.3% of the cases on right side and 26.6% of the cases on left side in third part.

* Corresponding author.

E-mail address: anjalee.ovhal@gmail.com (A. G. Ovhal).

2. Aims and Objectives

The aim of the present study was to contribute to the existing knowledge of the variations in the branching pattern of the Axillary artery, explaining its embryological basis and also its morphological and clinical significance.

3. Materials and Methods

15 cadavers (30 upper limbs) - 12 male and 3 female embalmed with 10% formalin were dissected for this study.

The study was conducted at Department of Anatomy, Seth G.S. Medical College, Parel, Mumbai. The cadavers allotted to the first year undergraduate students for dissection were used.

Variations in the origin and branching pattern of axillary artery were noted.

4. Results

Variable branching pattern was observed in 6.6% of the cases on right side and 6.6% of the cases on left side in first part of Axillary artery, 40% of the cases on right side and 53.3% of the cases on left side in second part and 53.3% of the cases on right side and 26.6% of the cases on left side in third part.

Table 1:

Parts	Variations in Axillary Artery	
	Right(%)	Left(%)
First part	6.6	6.6
Second part	40	53.3
Third part	53.3	26.6

Some of the important variations observed are as follows

1. A common trunk of lateral thoracic artery (LTA) and acromio - thoracic artery (ATA), suprascapular artery(SSA) and pectoral branches (PB) arising independently from 2nd part of left axillary artery.

2. A suprascapular artery arising from 1st part of right axillary artery.

3. 2 acromiothoracic arteries arising independently from 2nd part of left axillary artery.

4. A subscapular artery (SSA) and thoracodorsal artery arising independently from 2nd part of right axillary artery.

5. A superior thoracic artery, 2 lateral thoracic arteries, subscapular artery, 2 accessory muscular branches arising from 2nd part of left axillary artery and a common trunk of lateral thoracic artery (LTA) and acromio - thoracic artery (ATA).

6. A common trunk of lateral thoracic artery and subscapular artery arising from 2nd part of left axillary artery.

7. Accessory muscular branches arising from 2nd part of left axillary artery.

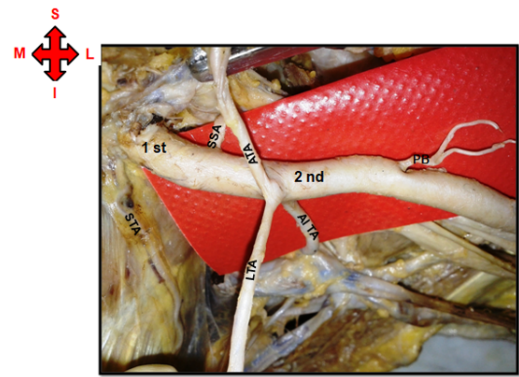


Fig. 1: Illustration showing common trunk of lateral thoracic artery and acromiothoracic artery, suprascapular artery and pectoral branches arising independently from 2nd part of left axillary artery (STA – Superior thoracic artery, Al TA- Alternative thoracicartery)

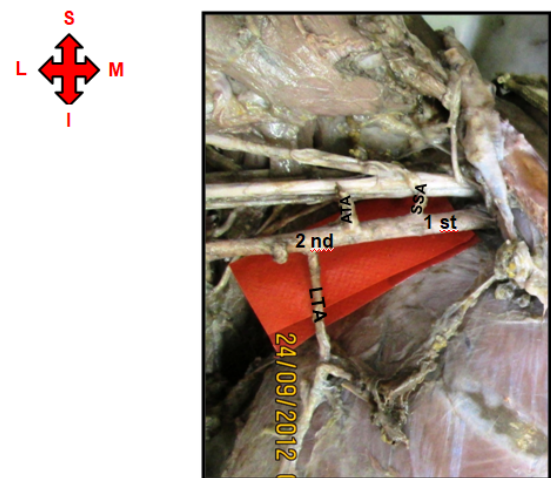


Fig. 2: Illustration showing suprascapular artery arising from 1st part of right axillary artery

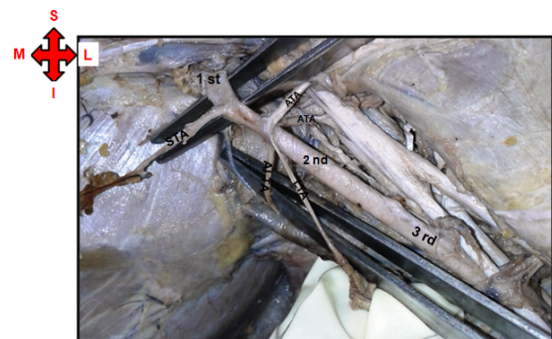


Fig. 3: Illustration showing 2 acromiothoracic arteries arising independently from 2nd part of left axillary artery

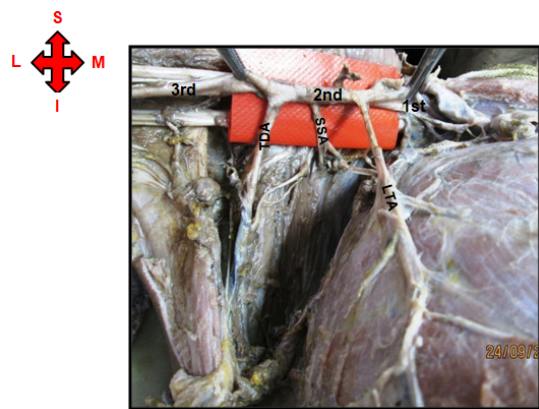


Fig. 4: Illustration showing subscapular artery and thoracodorsal artery arising independently from 2nd part of right axillary artery




Fig. 7: Illustration showing accessory muscular branches arising from 2nd part of left axillary artery




Fig. 5: Illustration showing superior thoracic artery, 2 lateral thoracic arteries, subscapular artery and 2 accessory muscular branches arising from 2nd part of left axillary artery ACHA- Anterior circumflex humeral artery, PCHA- Posterior circumflex humeral artery



Fig. 6: Illustration showing common trunk of lateral thoracic artery and subscapular artery arising from 2nd part of left axillary artery ACHA- Anterior circumflex humeral artery, PCHA- Posterior circumflex humeral artery

8. A thoracodorsal artery and pectoral branches arising independently from 2nd part of left axillary artery.




Fig. 8: Illustration showing thoracodorsal artery and pectoral branches arising independently from 2nd part of left axillary artery

9. A common trunk of anterior circumflex humeral artery (ACHA) and posterior circumflex humeral artery (PCHA) arising from 3rd part of right axillary artery.

10. 2 anterior circumflex humeral arteries and posterior circumflex humeral artery arising from 3rd part of left axillary artery.

11. A common trunk of posterior circumflex humeral artery and subscapular artery arising from 3rd part of left axillary artery.

12. A common trunk of anterior circumflex humeral artery, posterior circumflex humeral artery and subscapular artery and an accessory muscular branch arising from 3rd part of left axillary artery.

5. Discussion

A lot of variations in Axillary artery were documented in literature previously.

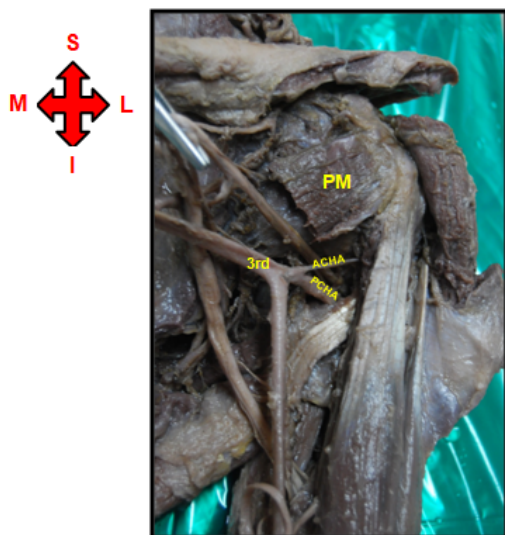


Fig. 9: Illustration showing common trunk of anterior circumflex humeral artery (ACHA) and posterior circumflex humeral artery (PCHA) arising from 3rd part of right axillary artery PM- Pectoralis minor

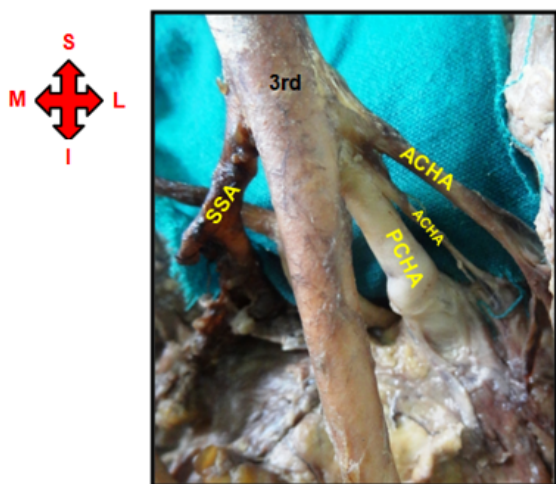


Fig. 10: Illustration showing 2 anterior circumflex humeral arteries and posterior circumflex humeral artery arising from 3rd part of left axillary artery

Rajesh Astik et al. (2012) found variant branching pattern of the axillary artery in 43 out of 68 limbs (63% limbs) in males and 7 limbs out of 12 limbs (58% limbs) in females. The variant branching pattern was found in 26 male cadavers (76.4%), unilaterally in 9 cases (five right, four left) and bilaterally in 17. It was found in four female cadavers (66.7%), with one unilateral case on the right side and three bilateral. In their study, the total incidence of variant branching pattern of the axillary artery was 30 out of 40 cadavers (75%) or 50 out of 80 upper limbs (62.5%).³



Fig. 11: Illustration showing a common trunk of posterior circumflex humeral artery and subscapular artery arising from 3rd part of left axillary artery

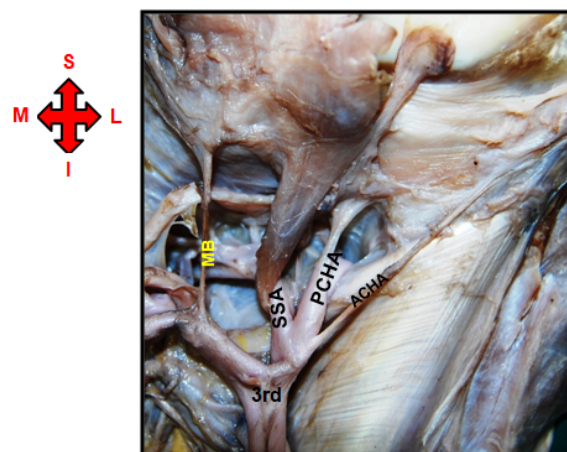


Fig. 12: Illustration showing common trunk of anterior circumflex humeral artery, posterior circumflex humeral artery and subscapular artery and an accessory muscular branch arising from 3rd part of left axillary artery

But in present study, a variable branching pattern was observed in 6.6% of the cases on right side and 6.6% of the cases on left side in first part of Axillary artery, 40% of the cases on right side and 53.3% of the cases on left side in second part and 53.3% of the cases on right side and 26.6% of the cases on left side in third part.

Samuel et al. (2006) documented a variation of an abnormal trunk of anterior and posterior circumflex humeral, subscapular, radial collateral, middle collateral and superior ulnar collateral arteries (third part) on left side in 50 yrs old male cadaver.⁴

Ramesh Rao et al. (2008) found a rare case of origin of subscapular, anterior and posterior circumflex humeral, profunda brachii artery and ulnar collateral arteries from a common trunk (third part-left side).⁵

Rohini R.Karambelkar et al (2012) in their study found a common trunk of subscapular and posterior humeral arteries in 8.33% of cases while in 20% cases, a common stem for the anterior and posterior circumflex humeral arteries.⁶

In present study a common trunk of anterior circumflex humeral artery, posterior circumflex humeral artery and subscapular artery and an accessory muscular branch were found to be arising from 3rd part of left axillary artery (Figure 12). Also 2 anterior circumflex humeral arteries and posterior circumflex humeral artery are seen to be arising from 3rd part of left axillary artery (Figure 10). A common trunk of lateral thoracic artery (LTA) and acromio - thoracic artery (ATA), suprascapular artery (SSA) and pectoral branches (PB) were seen to be arising independently from 2nd part of left axillary artery (Figure 1).

Baral et al (2009) recorded a variable pattern of a common trunk of lateral thoracic, thoracodorsal, subscapular, posterior circumflex scapular which continued as posterior circumflex humeral artery (second part).⁷

T. Srimathi et al (2011) found a common trunk of lateral thoracic artery, thoracoacromial artery, subscapular artery and posterior circumflex humeral artery (third part).⁸

Daimi et al. (2010) found two trunks of posterior circumflex humeral arteries arising from the third part of the axillary artery.⁹

In present study a common trunk of lateral thoracic artery and subscapular artery was found to be arising from 2nd part of left axillary artery.(Figure 6)

Amir Afshin et al. (2011) found an absent subscapular artery and circumflex scapular is a direct branch which gives a short, thin thoracodorsal artery (third part).¹⁰

In present study, thoracodorsal artery and pectoral branches were seen to be arising independently from 2nd part of left axillary artery (Figure 8). Many accessory muscular branches were arising from 2nd part of left axillary artery (Figure 7).

Rajesh Astik et al (2012) found many variations in branching pattern of axillary artery such as the origin of lateral thoracic artery from the subscapular artery, absent thoracoacromial trunk and all its branches from the second part of the axillary artery, division of thoracoacromial trunk into deltoacromial and clavipectoral trunks, which were divided into all branches of thoracoacromial trunk, origin of subscapular, anterior circumflex humeral, posterior circumflex humeral and profunda brachii arteries from a common trunk from the third part of the axillary artery and origin of posterior circumflex humeral artery from brachial artery in addition to third part of the axillary artery.³

Saeed et al (2002) documented a common subscapular-circumflex humeral trunk from the third part of axillary artery, which divided into subscapular, anterior circumflex humeral and posterior circumflex humeral arteries.¹¹

In present study, it was observed that a superior thoracic artery, 2 lateral thoracic arteries, subscapular artery, 2 accessory muscular branches were arising from 2nd part of

left axillary artery and a common trunk of lateral thoracic artery and acromio - thoracic artery (Figure 5).

In embryos of 11 mm length, the seventh cervical intersegmental artery enlarges and becomes the dominant vessel of axilla. C6, C7 and T1 segmental arteries and most of the longitudinal anastomoses that link up the intersegmental arteries degenerate slowly. The numerous alternatives that exist during the formation of upper limb vessels seem to be responsible for anomalous arterial branching patterns. Anomalous branching pattern may represent persisting branches of the capillary plexus of the developing limb buds.^{4,12,13}

6. Conclusion

Accurate and detailed knowledge of the normal and variant anatomy of the axillary artery is of importance for anatomists, surgeons, radiologists and clinicians during various interventional, diagnostic, therapeutic and surgical procedures on pectoral and axillary regions. e.g. Branches of the upper limb arteries have been used for coronary bypass and flaps in reconstructive surgery. It is also important for reparative, reconstructive surgery and angiography.

7. Source of Funding

None.

8. Conflicts of Interest

The authors declare no conflicts of interest.

9. Acknowledgement


I would like to express my special thanks of gratitude to Dr. Lakshmi Rajgopal, Ex Additional Professor, Seth G.S. Medical College, Parel, Mumbai for her valuable guidance and support.

References

1. Standring S. Pectoral girdle, shoulder region and axilla. In: Gray's Anatomy. London: Churchill Livingstone; 2005. p. 842–5.
2. Hollinshead WH. Anatomy for surgeons in general surgery of the upper limb. In: The back and limbs. vol. Volume 3. New York: Heber-Harper Book; 1958. p. 290–300.
3. Astik R, Dave U. Variations in branching pattern of the axillary artery: a study in 40 human cadavers. *J Vasc Bras.* 2012;11(1):12–7.
4. Paul SV, Ramana VV, Satheesha N. A rare variation in the branching pattern of the axillary artery. *Indian J Plast Surg.* 2006;39(2):222–3.
5. Rao TR, Shetty P, Suresh R. Abnormal branching pattern of the axillary artery and its clinical significance. *Int J Morphology.* 2008;26(2):389–92.
6. Karambelkar RR, Shewale AD, Umarji BN. Variations in Branching Pattern of Axillary Artery and its Clinical Significance. *Anatomica Karnataka.* 2011;5(2):47–51.
7. Baral P, Vijayabhaskar P, Roy S. Multiple arterial anomalies in upper limb. *Kathmandu Univ Med J.* 2009;7:293–7.
8. Srimathi T. Abnormal Branching Pattern of the Axillary Artery - A Case Report. *Int J Basic Med Sci.* 2011;2(4):73–6.

9. Daimi SR, Siddiqui AU, Wabale RN. Variations in the branching pattern of axillary artery with high origin of radial artery. *Int J Anat Var.* 2010;3:76–7.
10. Khaki AA, Shoja MAM, Khaki A. A rare case report of subscapular artery. *Ital J Anat Embryol.* 2011;116(1):56–9.
11. Saeed M, Rufai AA, Elsayed SE, Sadiq MS. Variations in the subclavian-axillary arterial system. *Saudi Med J.* 2002;22:206–12.
12. Comarck LM, Cauldwell MD, Anson BJ. Brachial and antebrachial arterial patterns: A study of 750 extremities. *Surg Gynecol Obstet.* 1953;96:43–54.
13. Lengele B, Dhem A. Variations of the vasculonervous elements of the human axilla. *Arch Anat Histol Embryol.* 1989;72:57–67.

Author biography

Anjalee G Ovhal, Associate Professor  <https://orcid.org/0000-0002-9953-4760>

K Ravikumar, Assistant Professor

Devender Sachdev, Associate Professor

Cite this article: Ovhal AG, Ravikumar K, Sachdev D. A study of variations in branching pattern of axillary artery in cadavers. *Indian J Clin Anat Physiol* 2021;8(4):314-319.