

Content available at: <https://www.ipinnovative.com/open-access-journals>

Indian Journal of Clinical Anatomy and Physiology

Journal homepage: <https://www.ijcap.org/>

## Original Research Article

## Variations in the gluteal region and its clinical significance – A cadaveric study

Shalini Kumar<sup>1,\*</sup>, Priyanka Rana<sup>1</sup>, Shayama Kumari Razdan<sup>1</sup><sup>1</sup>Dept. of Anatomy, Hamdard Institute of Medical Sciences & Research, New Delhi, India

## ARTICLE INFO

## Article history:

Received 27-11-2020

Accepted 03-12-2020

Available online 11-01-2021

## Keywords:

Piriformis muscle

Inferior gluteal nerve

Common peroneal nerve

## ABSTRACT

**Introduction:** Anatomical structures involving muscles and nerves in the gluteal region are important as any variations of Sciatic nerve (SN) and its surrounding muscles like piriformis muscle (PM) can lead to entrapment or compression of this nerve causing sciatica and piriformis syndrome.

**Aim:** To find out variations in the gluteal region related to piriformis muscle and the nerves surrounding it.

**Materials and Methods:** The study was done on 20 embalmed cadavers (total 40 gluteal regions) during routine cadaveric dissection. The anatomical relations of the piriformis and surrounding nerves i.e. sciatic nerve, its divisions and gluteal nerves were studied.

**Results:** The dissection was done on 40 gluteal regions. In 36 gluteal regions (90%) the sciatic nerve emerged below the piriformis as a single trunk. While in 4 gluteal regions (10%) there was a higher division of sciatic nerve. In one cadaver we observed an accessory piriformis muscle just inferior to the main piriformis muscle. The sciatic nerve was also dividing higher up into common peroneal nerve and tibial nerve in the gluteal region. The common peroneal nerve (CPN) was observed emerging between the main and the accessory piriformis muscle. Along with it the inferior gluteal nerves were also seen traversing between the main and the accessory piriformis muscle.

**Conclusion:** Knowledge of anatomical variations in the gluteal region is important to explain the myalgia and neuropathies in this region. This knowledge is also important in performing hip surgeries and giving intramuscular injections in the gluteal region.

© This is an open access article distributed under the terms of the Creative Commons Attribution License (<https://creativecommons.org/licenses/by/4.0/>) which permits unrestricted use, distribution, and reproduction in any medium, provided the original author and source are credited.

## 1. Introduction

Sciatic nerve is formed by the anterior and posterior divisions of the lumbosacral plexus. It is derived from the spinal nerves L4-S3. In 85-90% individuals it divides into Tibial nerve (TN) and Common Peroneal nerve (CPN) at the apex of popliteal fossa.<sup>1</sup> It supplies the skin and the muscles of the back of the thigh, leg and the foot. Normally it enters the gluteal region from pelvis by coming out of greater sciatic foramen. It lies below the piriformis and then continues as a single trunk. Variations in the gluteal region involving the divisions of sciatic nerve and piriformis muscle may cause compression of sciatic nerve leading to sciatica and piriformis syndrome. These variations of

sciatic nerve in the lower limb in relation to piriformis have been classified by various authors.<sup>2-8</sup> This study was done to see any variations of sciatic nerve along with other nerves in this region and their relation to piriformis so that this knowledge can be applied while performing the hip surgeries. Moreover, the variations can be kept in mind while giving intramuscular injections in the gluteal region.

## 2. Materials and Methods

20 formalin fixed cadavers were used following routine cadaveric dissection on 40 gluteal regions. The study was carried out in the Department of Anatomy, HIMSR during the period of two years. Twelve cadavers were male and eight cadavers were female. All cadavers were further dissected to identify sciatic nerve and its division, gluteal

\* Corresponding author.

E-mail address: [drshalini94@gmail.com](mailto:drshalini94@gmail.com) (S. Kumar).

nerves and its relation to the piriformis muscle. The sciatic nerve division and its relation to piriformis muscle was identified in order to find out if the nerve was dividing below the piriformis, above the piriformis or passing through the piriformis muscle. All the variations of the nerves surrounding the piriformis were recorded.

### 3. Results

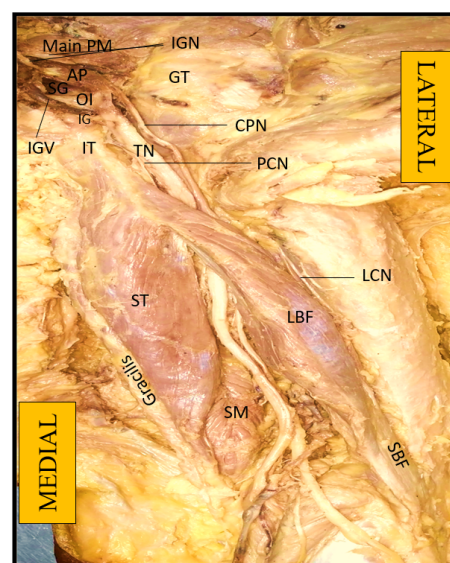
In 90% of the gluteal region studied i.e. 36 regions showed the normal course of the sciatic nerve passing below the piriformis as a single trunk with no variations seen in piriformis and the surrounding structures. In 4 gluteal regions (i.e.10%) the sciatic nerve was dividing higher up and passing below the piriformis. In one case i.e. right gluteal region of male cadaver we observed an accessory piriformis muscle present below the main piriformis muscle and appearing as a separate muscle as shown in Table 1. The sciatic nerve was also dividing into CPN and TN in the gluteal region. The CPN was observed passing between the main and accessory piriformis muscle. In addition, the inferior gluteal nerves were seen traversing between the main and accessory piriformis muscle. Moreover, the CPN and TN were not uniting at any point of their course and traversed as separate nerves. As shown in Figure 1.

## 4. Discussion

In 1937 Beaton & Anson gave a classification for variations of SN and PM in 120 specimens.<sup>9,12</sup> According to their classification 6 types of variations can be seen : Type 1 having undivided nerve below undivided muscle, Type 2 having divisions of nerve between and below undivided muscle, Type 3 where divisions are above and below the undivided muscle, Type 4 having undivided nerve between heads of piriformis, Type 5 where divisions are present between and above heads of piriformis and Type 6 having undivided nerve above undivided muscle.

Patel et al<sup>15</sup> studied on 86 lower extremities and found Type 1 variation in 91%. Pokorny et al.<sup>10</sup> found type 1 in 79% cadavers and Type 2, 3&4 in 14.3%, 4.4% and 2.2% respectively. Similarly Ugrenovic et al<sup>11</sup> found Type 1 variation in 96% cases and in 4% cases they found variable relationship between SN and piriformis muscle. They also found CPN perforating the piriformis muscle in 2.5% cases while Tibial nerve leaving the below the piriformis. Our study found that in 90% gluteal regions showed type 1 where sciatic nerve was passing as a single trunk below the piriformis. In 4 gluteal regions (10%) the sciatic nerve was dividing higher up and passing below the undivided piriformis which comes under type 2.

Many authors have reported the accessory head of piriformis along with main piriformis. Natsis et al<sup>14</sup> observed two heads of piriformis where CPN and TN passed below the double piriformis in 4% cases. Only in one limb



**Fig. 1:** Showing the Common peroneal nerve passing between the main and accessory piriformis muscle. The Tibial nerve is seen emerging below the Accessory piriformis muscle. The Inferior gluteal nerve is also seen emerging between the main piriformis and accessory piriformis muscle. PM- piriformis muscle, AP-Accessory piriformis muscle, CPN- Common Peroneal nerve, IGN- Inferior gluteal nerve, SG- Superior gemillus, IG – Inferior gemillus, OI- Obturator Internus, GT- Greater Trochanter, IT- Inferior Trochanter, QF- Quadratus Femoris, PCN- Posterior cutaneous nerve of thigh, ST- Semitendinosus, SM- Semimembranosus, LBF- Long head of biceps femoris, SBF- Small head of biceps femoris, IGV-inferior gluteal vein

they found that nerves were piercing through the piriformis and in another limb they were passing above it. Similarly Battaglia et al<sup>15</sup> found two bellies of piriformis and CPN was passing between them. The TN was passing below the inferior border of piriformis. Jacommo et al<sup>16</sup> found in one cadaver that SN was dividing high along with an accessory piriformis muscle. They also observed that SN was dividing under the piriformis and TN was passing between accessory piriformis and superior gemellus muscle. Kabkci et al<sup>17</sup> studied in 60 fetuses that In 98.3% cases the SN was exiting below the piriformis and in only 1.67% there was a high division of SN.

Lewis et al<sup>18</sup> studied 51 corpses and found that in 89% cases the SN was undivided and passing as a single trunk below piriformis. In 8.8% CPN was seen piercing the piriformis and in 2.9% cases the CPN was passing over the piriformis. In our study we found that in 2.5% cases the CPN was passing between the main and the accessory piriformis muscle. Our study is different from all these studies as we observed the inferior gluteal nerves along with CPN passing between the main and an accessory piriformis muscle.

Inferior gluteal nerve (IGN) arises from the sacral plexus (L5, S1 and S2 dorsal rami). The other nerves arising from the

**Table 1:**

Cadavers studied	No	Gluteal regions dissected	Normal course of sciatic nerve Dividing at popliteal fossa	Higher division dividing below piriformis
Male	15	30	12	2
Female	5	10	5	0

**Table 2:**

Name of authors	Type 1	Type 2	Type 3	Type 4	Type 5	Type 6
Beaton & Anson <sup>9</sup>	84.2%	11.7%	3.3%	0.8%	–	–
Pokorny et al <sup>10</sup>	79.1%	14.3%	4.4%	2.2%	–	–
Ugrenovic et al <sup>11</sup>	96%	2.5%	1.5%	–	–	–
Present study	90%	10%	–	–	–	–

sacral plexus are sciatic nerve, superior gluteal nerve, the pudendal nerve and the posterior femoral cutaneous nerve.<sup>1</sup> The Inferior gluteal nerve along with the sciatic nerve leaves the pelvis through the sciatic notch and both lie below the piriformis. Inferior gluteal nerve then supplies the gluteus maximus muscle.

Sforsini et al<sup>19</sup> observed IGN arising from posterior cutaneous nerve of thigh instead of having an independent origin. Nagarajan et al<sup>20</sup> found a communication between common peroneal and inferior gluteal nerve and that communicating nerve was found to lie in the substance of lower piriformis.

Jacomo et al<sup>16</sup> found common peroneal nerve passing between the piriformis and accessory piriformis muscle and then giving a branch i.e. inferior gluteal nerve.

S. L. Fahrioglu et al<sup>21</sup> found an accessory piriformis muscle and high division of sciatic nerve. They also observe that piriformis muscle was fused with the gluteus medius muscle. They found inferior gluteal nerve, common peroneal nerve and posterior cutaneous nerve of thigh located between main and accessory piriformis muscle.

The clinical symptoms due to IGN entrapment alone cannot be differentiated from those due to entrapment of sciatic nerve, piriformis syndrome, posterior cutaneous nerve entrapment, sacroiliac joint pathology etc. Most commonly piriformis abnormality leads to several concurrent entrapment since IGN, sciatic nerve and posterior cutaneous nerve of thigh travel together.

Many authors have done MRI studies for the variations of piriformis. Polesello et al<sup>22</sup> through an MRI study observed an accessory muscle belly of left piriformis and common peroneal nerve passed between its fibers and the standard piriformis muscle in one female patient of 45 year old. Varenika et al<sup>23</sup> by MRI study found normal sciatic nerve anatomy in 87% case and the other 13% showed one of the division of sciatic nerve passing through piriformis and the other passing below the piriformis.

Thus the anatomical variations seen in sciatic nerve and the piriformis muscle present in gluteal region is

an important cause of clinical syndrome called piriformis syndrome.<sup>14</sup> It is characterised by radiating pain in gluteal region and the lower limb.<sup>24</sup>

## 5. Conclusion

The anatomical knowledge of the variations present in gluteal region is of utmost importance for the surgeons who perform surgeries around the hip joint and gluteal region. This knowledge is also important to the clinicians while giving intramuscular injections in this region to prevent sciatic injury. Moreover also can help in managing patients of piriformis syndrome which can be due to compression of common peroneal nerve and gluteal nerve between the piriformis and accessory head of piriformis.

## 6. Source of Funding

None.

## 7. Conflict of Interest

The authors have no conflicts of interest.

## References

1. Standring S. Gray's anatomy: the anatomical basis of clinical practice. London: Churchill Livingstone; 2005.
2. Anbumani TL, Selvi AT, Ammal SA. Sciatic nerve and its variations: an anatomical study. *Int J Anat Res*. 2015;3(2):1121–7.
3. Mallikarjun A, Sangeetha V. Study on variant anatomy of sciatic nerve. *J Clin Diagn Res*. 2014;8(8):7–09.
4. Prakash KD, Amanrao BP, Karan K, Santosh S. Study of anatomical variations of the sciatic nerve and its importance to clinicians and anaesthetist. *Int J Curr Res*. 2014;6(7):7518–21.
5. Guvencer M, Iyem C, Akcyer P, Tetik S, Naderi S. Variation in the high division of the sciatic nerve and relationship between the sciatic nerve and the piriformis. *Turk Neurosurg*. 2009;19(2):139–44.
6. Shashtrakar R, Nakhate M, Sawant VG. Study of variation in the high division of sciatic nerve and its relationship with the Piriformis muscle. *Med Res Chron*. 2015;2(3):359–65.
7. Surke SB, Badaam AM. High division of sciatic nerve: A cadaveric study. *Int J Anat Radiol Surg*. 2016;5(4):18–20.
8. Rani P, Kalra S. A cadaveric study of normal and variant levels of division of sciatic nerve and coupled anomalies with clinical

- application in surgical interventions. *Int J Anat Res*. 2015;3(3):1230–6.
9. Beaton LE. The sciatic nerve and piriform muscle: Their Interrelation a possible cause of coccygodynia. *J Bone Joint Surgery Am*. 1938;20:686–88.
  10. Pokorný D, Jahoda D, Veigl D, Pinskerová V, Sosna A. Topographic variations of the relationship of the sciatic nerve and the piriformis muscle and its relevance to palsy after total hip arthroplasty. *Surg Radiol Anat*. 2006;28(1):88–91. doi:10.1007/s00276-005-0056-x.
  11. Ugrenović S, Jovanović I, Krstić V, Stojanović V, Vasović L, Antić S. The level of the sciatic nerve division and its relations to the piriform muscle. *Vojnosanit Pregl*. 2005;62(1):45–9.
  12. Beaton LE, Anson BJ. The relation of the sciatic nerve and of its subdivisions to the piriformis muscle. *The Anatomical Record*. 1937;70(1):1–5. doi:10.1002/ar.1090700102.
  13. Patel S, Shah M, Vora R, Zalawadia A, Rathod SP. A variation in the high division of the sciatic nerve and its relation with piriformis muscle. *Natl J Med Res*. 2011;1(2):27–30.
  14. Natsis K, Totlis T, Konstantinidis GA, Paraskevas G, Piagkou M, Koebeke J. Anatomical variations between the sciatic nerve and the piriformis muscle: a contribution to surgical anatomy in piriformis syndrome. *Surg Radiol Anat*. 2014;36(3):273–80. doi:10.1007/s00276-013-1180-7.
  15. Battaglia PJ, Scali F, Enix DE. Co-presentation of unilateral femoral and bilateral sciatic nerve variants in one cadaver: A case report with clinical implications. *Chiropr Man Ther*. 2012;20(1):34. doi:10.1186/2045-709x-20-34.
  16. Jacomo AL, Martinez CAR, Saleh SO, Andrade M, Akamatsu FE. Unusual Relationship between the Piriform Muscle and Sciatic, Inferior Gluteal and Posterior Femoral Cutaneous Nerves. *Int J Morphol*. 2014;32(2):432–4. doi:10.4067/s0717-95022014000200008.
  17. Kabakcı AA, Buyukmumcu M, Yılmaz MT, Cicekcibasi AE, Akin D. Anatomical structure and topographic anatomy of sciatic nerve in human fetuses. *J Anat Soc India*. 2016;65(1):S25–S32. doi:10.1016/j.jasi.2015.12.001.
  18. Lewis S, Jurak J, Lee C, Lewis R, Gest T. Anatomical variations of the sciatic nerve, in relation to the piriformis muscle. *Transl Res Anat*. 2016;5(1):15–9. doi:10.1016/j.tria.2016.11.001.
  19. Sforsini C, Wikinski JA. Anatomical review of the lumbosacral plexus and nerves of the lower extremity. *Tech Reg Anesth Pain Manag*. 2006;10(4):138–44. doi:10.1053/j.trap.2006.10.001.
  20. Nagarajan S, Veeramani R, Suma HY, Chand P. Common peroneal nerve entrapment with the communication between inferior gluteal nerve and common peroneal nerve. *J Exp Clin Anat*. 2016;15(1):56–9. doi:10.4103/1596-2393.190825.
  21. Fahrioglu SL, Koç T, Kurtoğlu Z, İlgi NS. Unusual accessory piriformis muscle: A case report. *J Anat Soc India*. 2017;66(2):S19–S21. doi:10.1016/j.jasi.2017.03.003.
  22. Polesello GC, Queiroz MC, Linhares JPT, Amaral DT, Ono NK. Anatomical variation of piriformis muscle as a cause of deep gluteal pain: diagnosis using MR neurography and treatment. *Rev Bras Ortop*. 2013;48(1):114–7. doi:10.1016/j.rboe.2012.09.001.
  23. Varenika V, Lutz AM, Beaulieu CF, Bucknor MD. Detection and prevalence of variant sciatic nerve anatomy in relation to the piriformis muscle on MRI. *Skelet Radiol*. 2017;46:751–7. doi:10.1007/s00256-017-2597-6.
  24. Santos CM, Pereira CU, Morais AA. Piriformis syndrome: a review of the literature. *J Bras Neurocirurg*. 2009;20(1):46–52.

### Author biography

**Shalini Kumar**, Associate Professor

**Priyanka Rana**, PG Student

**Shayama Kumari Razdan**, Professor

**Cite this article:** Kumar S, Rana P, Razdan SK. Variations in the gluteal region and its clinical significance – A cadaveric study. *Indian J Clin Anat Physiol* 2020;7(4):346–349.